D Y PATIL DENTAL SCHOOL

Dr. D Y Patil Knowledge City, Charholi Bk, Via Lohegaon, Pune 412105
Affiliated to Maharashtra University of Health Sciences, Nashik
Recognized by Dental Council of India



SELF STUDY REPORT (CYCLE 1) 2018-2023

CRITERIA: 2: Teaching-Learning and Evaluation

KEY INDICATOR: 2.3: Teaching-Learning Process

METRIC: 2.3.2: Institute facilitates the use of Clinical skills laboratory/ simulation- based learning

ADDITIONAL INFORMATION

INDEX

SR.NO.	DATA	PAGE NO.
1.	Details of Clinical Skills Laboratory/Simulation Based Learning	4-6
2.	Nemoceph software purchase invoice	7
3.	Nemoceph software training details	8-15
4.	Nemoceph software usage register	16-39

LINGARAJ SHIGLI ANAND

Digitally signed by LINGARAJ SHIGLI ANAND
Date: 2024.09.27 10:22:52 +05'30'

Clinical Skills Laboratory/Simulation Based Learning	
A. Basic Clinical Skills/ Simulation Training Models and Trainers for skills in relevant disciplines	1. Department of Oral and Maxillofacial Surgery - List of instruments - Models - Emergency drugs - Radiographs 2. Department of Oral Medicine and Radiology - List of models 3. Department of Oral Pathology - List of specimens/models in DADH 4. Department of Conservative Dentistry and Endodontics - List of models 5. Department of Prosthodontics and Crown and Bridge - List of models 6. Department of Periodontology - List of models 7. Department of Public Health Dentistry - List of posters, charts and models 8. Department of Orthodontics and Dentofacial Orthopaedics - Name of Appliance - Models
B. Advanced simulators for simulation based training	Nemoceph Software Training - For Students - For Staff
C. Structured programs for training and assessment of students in Clinical Skills Lab/ Simulation based learning	1. Department of General Microbiology - Topics for UG skills 2. Department of Pharmacology - Topics for UG skills 3. Department of Oral Pathology and Microbiology - Topics for UG skills 3rd BDS (2018-2023) 4. Department of Pedodontics and Preventive Dentistry - Topics covered in UG Preclinical lab skills - Topics covered in PG Preclinical lab skills - Details of training program conducted - Details of participants

	5. Department of Oral Medicine and Radiology - Details of training program conducted in UG skill lab 6. Department of General Pathology - Topics covered in UG skills 7. Department of Prosthodontics and Crown and Bridge - Details of Training program conducted in Dental Material Science (1st and 2nd BDS) - Details of Training program conducted in Pre-clinical Prosthodontics (1st and 2nd BDS) 8. Department of Dental Anatomy and Histology - Topics covered and participants in UG skill lab for 1st BDS (2018-2023) 9. Department of General Anatomy Histology - Topics covered in BDS 1st Year (2018-2023) 10. Department of Orthodontics and Dentofacial Orthopaedics - Topics covered in UG skill lab for 3rd BDS - Topics covered in UG skill lab in 4th BDS - Topics covered in UG skill lab for Interns - Topics covered in PG skill lab - Details of Training program and Details of participants - Topics covered in UG preclinical lab - Topics covered in PG preclinical lab - Details training programmes for the faculty in the use of clinical skill lab and simulation methods of teaching-learning with details of participants 11. Department of Oral and Maxillofacial Surgery - Topics covered in clinical postings for Interns - Topics covered in clinical postings for Final BDS

	- Topics covered in clinical postings for 3rd BDS - Details of training program conducted and details of participants 12. Department of Conservative Dentistry and Endodontics - Topics covered in UG skill lab for 1st, 2nd , 3rd , 4th BDS - Topics covered in PG skill lab - Details of training program conducted and details of participants - Topics covered in PG preclinical lab - Topics covered in UG preclinical lab - Details of training program for the faculty in the use of clinical skill lab and simulation methos of teaching-learning with details of participants 13. Department of Periodontology - Topics covered in UG skill lab for Interns - Details of training program conducted and details of participants in Clinical postings conducted for 3rd and 4th BDS 14. Department of Public Health Dentistry - Atraumatic Restorative Treatment, Pit and Fissure Sealant Application (3rd BDS,4th BDS, Interns)
D. Training program for the faculty in the use of clinical skill lab and simulation methods of teaching-learning	1. Department of Conservative Dentistry and Endodontics - EndoBuzz - CompoArt - Endo-kraft - Rubber dam isolation 2. Nemoceph Software Training

NEMOCEPH SOFTWARE PURCHASE INVOICE

BILL

GST : **09AGUPS1711N1ZO**

SANSIN 3D SYSTEMS K 64, Sector 11, NOIDA – 201 301 Uttar Pradesh (INDIA) +91.98110 50717 / 98999 10151	**D.Y. PATIL DENTAL SCHOOL** **Lohegaon, Pune** State Code : **27** GST :

Your Reference No & Date	*Our Bill Number*	*Date*
DYPDS/12/21-22 dated 24.02.2021	**12/21-22**	**Sept 03, 2021**

S.No.	*PARTICULARS*	*QTY*	*RATE (Rs.)*	*TOTAL (Rs.)*
1.	**NemoCeph 2D Orthodontic Cephalometric Software with virtual dongle version 10** ***One year guarantee and free technical support***	**01**	**1,69,492.00**	**1,69,492.00**
	CGST			
	SGST			
	IGST		**18%**	**30,508.00**
	TOTAL			**2,00,000.00**
	Rupees One Lakh Seventy Seven Thousand only			

Advance Received 50% : Rs. 1,00,000.00
Balance 50% : Rs. 1,00,000.00

Software installed on Sept 03, 2021
Checked and demonstrated to Dr Arun Mhaske



For Sansin 3D Systems

NEMOCEPH SOFTWARE TRAINING DETAILS

D Y PATIL GROUP

D Y PATIL DENTAL SCHOOL

Affiliated to the Maharashtra University of Health Sciences, Nashik
Recognized by Dental Council of India

NEMOCEPH SOFTWARE TRAINING	
Course Name – Nemoceph software.	Date:08/01/2021
Department: Orthodontics and Dentofacial orthopaedics	Resource: Anydesk Software
Participants : staff	

Content:

The course includes training and calibration of students to use Nemoceph software.

Skills acquired:

Digitally using software for tracing of lateral cephalogram.

List of beneficiaries:

Sr. no	Name of staff
1.	Dr. Sandeep Jethe
2.	Dr. Varsha Merani
3.	Dr. Shailesh Dongre
4.	Dr. Arun Mhaske
5.	Dr. Suyog Shendage.

HOD

Department of Orthodontics

PROFESSOR & HEAD
Dept. of Orthodontics
D Y Patil Dental School
D Y Patil Knowledge City
Charholi Bk, Via Lohegaon, Pune - 412105

Dean

Dr D Y Patil Knowledge City, Charholi Bk, Via Lohegaon, Pune 412 105
• Phone (020) 35037779 • E Mail : dean@dypds.com



D Y PATIL GROUP

D Y PATIL DENTAL SCHOOL

Affiliated to the Maharashtra University of Health Sciences, Nashik
Recognized by Dental Council of India

NEMOCEPH SOFTWARE TRAINING	
Course Name – Nemoceph software.	Date:01/08/2022
Department: Orthodontics and Dentofacial orthopaedics	Resource Person: Dr. Shirish Game
Participants : 5	

Content:

The course includes training and calibration of students to use Nemoceph software.

Skills acquired:

Digitally using software for tracing of lateral cephalogram.

HOD

Department of Orthodontics

PROFESSOR & HEAD
Dept. of Orthodontics
D Y Patil Dental School
D Y Patil Knowledge City
Charholi Bk. Via Lohegaon, Pune - 412105

Dean

Dr D Y Patil Knowledge City, Charholi Bk, Via Lohegaon, Pune 412 105
• Phone (020) 35037779 • E Mail : dean@dypds.com

D Y PATIL GROUP

D Y PATIL DENTAL SCHOOL

Affiliated to the Maharashtra University of Health Sciences, Nashik
Recognized by Dental Council of India

List of beneficiaries

Dr. Sunil Kalyankar

Dr. Akanksha Kedar

Dr. Ashwini Kamble

Dr. Krushnal Bopate

Dr. Snehal Mahatre

HOD

Department of Orthodontics

PROFESSOR & HEAD
Dept. of Orthodontics
D Y Patil Dental School
D Y Patil Knowledge City
Charoli (Bk), Via Lohegaon, Pune - 412105

Dean

D Y PATIL GROUP

D Y PATIL DENTAL SCHOOL

Affiliated to the Maharashtra University of Health Sciences, Nashik
Recognized by Dental Council of India

NEMOCEPH SOFTWARE TRAINING	
Course Name – Nemoceph software.	Date:29/11/2021
Department: Orthodontics and Dentofacial orthopaedics	Resource Person: Dr. Shirish Game
Participants : 2	

Content:

The course includes training and calibration of students to use Nemoceph software.

Skills acquired:

Digitally using software for tracing of lateral cephalogram.

HOD

Department of Orthodontics

PROFESSOR & HEAD
Dept. of Orthodontics
D Y Patil Dental School
D Y Patil Knowledge City
Pimpri (Bk), Via Lohegaon, Pune - 411018

Dean

D Y PATIL GROUP

D Y PATIL DENTAL SCHOOL

Affiliated to the Maharashtra University of Health Sciences, Nashik
Recognized by Dental Council of India

List of beneficiaries

Participants: Dr. Sanjeet Utekar

Dr. Mrunali Tone

HOD

Department of Orthodontics

PROFESSOR & HEAD
Dept. of Orthodontics
D Y Patil Dental School
D Y Patil Knowledge City
Charoli (Bk), Via Lohegaon. Pune - 412105

Dean





NEMOCEPH SOFTWARE USAGE REGISTER

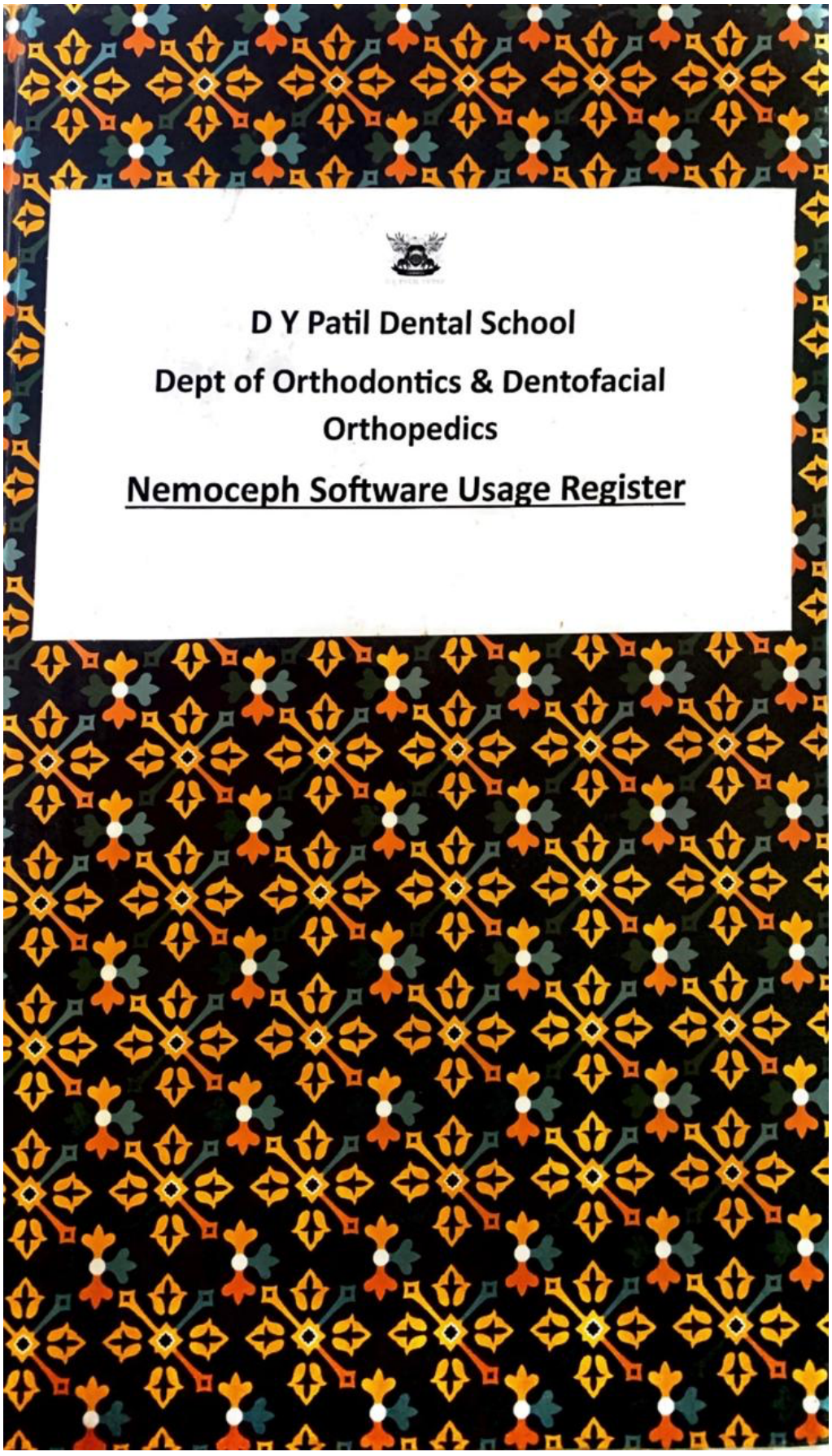

Dept. of Orthodontics And
Dentofacial Orthopedics.

Nemoceph Software Record.

Sept. 2021

Date.	Work done.	Doctors Name	Sign.
3/9/2021	Software installation done.		
8/9/2021.	Demostration of software use to staff.		
13/9/2021.	Tracing of Pt. Neha Patil	Dr. Shailesh.	
22/9/2021	Demonstration to final year student.	Dr. Arun	
25/9/2021	Demonstration to interns	Dr. Varsha.	
26/9/2021.	Demonstration to third year student.	Dr. Varsha.	
		Dr Sunil.	

PROFESSOR & HEAD
Dept. of Orthodontics
D Y Patil Dental College
D Y Patil Knowledge City
Varoli (Bk), Via Lohegaon, Pune - 411105

December - 2021

Date	work done	Doctor's Name	Sign
29/11/2021	Demonstration to post graduate students	Dr. Arun	[signature]
7/12/2021	tracing done for Pratik Ghule	Dr. Mrunali	[signature]
9/12/2021	tracing done for Jyoti sharma	Dr Sanjeet.	
10/12/2021	tracing done for Sneha Bade	Dr Shirish.	[signature]
13/12/2021	tracing done for Sana Shaikh	Dr. Sanjeet.	
15/12/2021	tracing done for Alka Jadhav	Dr. Mrunali	[signature]
17/12/2021	tracing done for Omkar Gard	Dr Shirish	[signature]
20/12/2021	tracing done for Sahil Joseph	Dr. Shirish	[signature]
21/12/2021	tracing done for Pragati more	Dr. Mrunali	[signature]
23/12/2021	tracing done for Hemant Telang	Dr. Sanjeet.	
	Demonstration to final year student	Dr. Shailesh	[signature]

PROFESSOR & HEAD
Dept. of Orthodontics
D Y Patil Dr. ... School
D Y Patil Knowledge City
...aroli (Bk), Via Lohegaon, Pune - 412105

January 2022.

Date	Work Done.	Doctors Name	Sign.
5/1/22	Demonstration to Interns.	Dr. Sujog	
7/1/22	Ceph tracing of patient. Khushbu	Dr. Mrunali	
13/1/22	Ceph tracing of Aditya	Dr. Varsha	

PROFESSOR & HEAD
Dept. of Orthodontics
D Y Patil Dental School
D Y Patil Knowledge City
Charoli (Bk), Via Lohegaon, Pune - 412105

February 2022

Date.	Work done.	Doctors Name	Sign
7/2/22	tracing done for yash sarde	Dr. Mrunali	
10/2/22	Tracing done for Komal Chandane	Dr. Shinth Caune	

PROFESSOR & HEAD
Dept. of Orthodontics
D Y Patil Dental School
D Y Patil Knowledge City
Charoli (Bk), Via Lohegaon, Pune - 412105

March 2022

Date	Work done	Doctor's Name	Sign.
3/3/22	tracing done par mahadevi sakhare	Dr Mrunali	Mrunali
10/3/22	Tracing done for Trupti Khandure	Dr. Rutuja	Rutuja

PROFESSOR & HEAD
Dept. of Orthodontics
D Y Patil Dental School
D Y Patil Knowledge City
Charoli (Bk), Via Lohegaon, Pune - 412105

April 2022

Date	Work done	Doctors Name	Sign
6/4/22	tracing done for Pratik baghele	Dr. Anuradha	
13/4/22	Tracing done for Aayushi Pagnis	Dr. Shirish Gaware	

PROFESSOR & HEAD
Dept. of Orthodontics
D Y Patil Dental School
D Y Patil Knowledge City
Kasarwadi (Bk), Via Lohegaon, Pune - 412105

May 2022

Date	Work done	Doctors Name	Sign
5/5/22	tracing done for Jayraj Likame	Dr. Mrunali	[illegible]
11/5/22	Tracing done for Ashwany Dasnoori	Dr. Shivesh Gupta	[illegible]

PROFESSOR & HEAD
Dept. of Orthodontics
D Y Patil Dental School
D Y Patil Knowledge City
Charoli (Bk), Via Lohegaon, P

June 2022

Date.	Work done.	Doctor.	Staff.
6/6/22	Tracing of Shruchi Lokhande	Dr. Shirish Game	
8/6/22	Tracing of Sairaj Raut	Dr. Mrunal Tare	
14/6/22	Tracing of Aditya Kambli	Dr. Sanjeet Otekar	

PROFESSOR & HEAD
Dept. of Prosthodontics
D Y Patil Dental School
D Y Patil Knowledge City
Charoli (Bk), Via Lohegaon, Pune - 412

July 2022

Date	Work done	Doctor	Staff Sign
4/7/22	Tracing of Pranav Kadam	Dr. Shirish Game	
12/7/22	Tracing of Aastha Tidekar	Dr: Mrunali Tone	
20/7/22	Tracing of Tanushree Manawore	Dr.. Sanjeet Utekar	

PROFESSOR & HEAD
Dept. of Orthodontics
D Y Patil Dental School
D Y Patil Knowledge City
Charoli (Bk), Via Lohegaon

August 2022

Date.	Work Done	Doctor.	Sign.
2/8/22	Tracing of Priti Bhandari	Dr. Shirish Game	
3/8/22	Tracing of Tripti Gavhane	Dr. Sanjeet Utekar	
3/8/22	Tracing of Omkar Kakade	Dr. Shirish Game	
8/8/22	Tracing of Swapnil Acharya	Dr. Neenali Tare	
11/8/22	Tracing of Anjali Badigar	Dr. Sanjeet Utekar	
	Tracing of Shravani Belitkar	Dr. Sunil Kalyankar	
17/8/22	Tracing of Sadri Jadhav	Dr. Sunil Kalyankar	

PROFESSOR & HEAD
Dept. of Orthodontics
D Y Patil Dental School
D Y Patil Knowledge City
Charholi (Bk), Via Lohegaon, Pune - 412105

Sept 2022

Date	Work done	Doctor	Sign
1/9/22	Tracing of Omkar Nawale	Dr. Sanjeet Utekar	Sanjeet
6/9/22	Priya Kadam Lateral Ceph tracing	Dr. Shirish Game	Shirish
8/9/22	Tracing of Harshita Jadhav	Dr. Mrunali Tare	Mrunali
12/9/22	Tracing of Rishav Arya	Dr. Sanjeet Utekar	Sanjeet
16/9/22	Tracing of Lavanya Polula	Dr. Sanjeet Utekar	Sanjeet
20/9/22	Tracing of Sadichha oral	Dr. Sunil kalyan	Sunil
23/9/22	Tracing of Sirat Kholkar	Dr. Sunil kalyan	Sunil

PROFESSOR & HEAD
Dept. of Orthodontics
D Y Patil Dental School
D Y Patil Knowledge City
Charholi (Bk), Via Lohegaon, Pune - 412105

Oct 2022

Date	Work done	Doctor	Sign
3/10/22	Tracing of Anjali Chadke	Dr. Sanjeet Utekar	Sanjeet
4/10/22	Tracing of Sapana Ranpise	Dr. Sanjeet Utekar	Sanjeet
7/10/22	Tracing of Shubhangi Jire	Dr. Shirish Game	
11/10/22	Tracing of chetan gaikwad	Dr. Mrunali Tare	
14/10/22	Tracing of Tejaswini kamble	Dr. Sunil kalyure	
15/10/22	Tracing of Rachana Nakade	Dr. Sunil kalyure	

PROFESSOR & HEAD
Dept. of Orthodontics
D Y Patil Dental School
D Y Patil Knowledge City
Charholi (Bk), Via Lohegaon, Pune - 412

Nov 2022

Date.	Work done.	Doctor.	Sign.
4/9/22	Tracing of Kesav Kamble	Dr. Sanjeet. Utekar	Sanjeet
9/9/22	Tracing of Shruti Jindal	Dr. Shirish Game	Shirish
10/9/22	Tracing of Shravani Shete	Dr. Mrunali Tare	Mrunali
15/9/22	Tracing of Atul Bhist	Dr. Sanjeet Utekar	Sanjeet
17/9/22	Tracing of Bhushan Malghan	Dr. Sunil Kalyan	Sunil

PROFESSOR & HEAD
Dept. of Orthodontics
D Y Patil Dental School
D Y Patil Knowledge City
Charoli (Bk), Via Lohegaon, Pune - 412105

Dec 2022

Date	Work done	Doctor	Sign
5/12/23	Tracing of Rohit Kolekar	Dr. Sanjeet Utekar	Sanjeet
8/12/23	Tracing of Shruti Nagdekar	Dr. Shirish Game	Shirish
10/12/23	Tracing of ashwini waghmare	Dr. Mrinali Tare	Mrinali
12/12/23	Tracing of Unnatti	Dr. Sanjeet Utekar	Sanjeet
15/12/23	Tracing of Rutika Tandale	Dr. Sunil Kalyankar	Sunil

PROFESSOR & HEAD
Dept. of Orthodontics
D Y Patil Dental School
D Y Patil Knowledge City
Charoli (Bk), Via Lohegaon, Pune - 412105

January 2023.

Date.	~~Doctor~~ Work done.	Doctor	Sign
3/1/23	Tracing of Janhavi Waghere	Dr. Shirish Game.	
6/1/23	Tracing of Prachi Lokhande	Dr. Sanjeet Utekar	
10/1/23	Tracing of Aayushi Singh	Dr. Shirish Game	
10/1/23	Tracing of ashwini umap	Dr. Neenali Tare	
12/1/23	Tracing of Mausha Kumar	Dr Sanjeet Utekar	
13/1/23	Tracing of Anshika Chaudhary	Dr. Sunil Kalyur	
16/1/23	Tracing of Payal Thalor	Dr. Neenali Tare	
18/1/23	Tracing of Payal giri	Dr. Sunil Kalyur	

PROFESSOR & HEAD
Dept. of Orthodontics
D Y Patil Dental School
D Y Patil Knowledge City
Charholi (Bk), Via Lohegaon, Pune - 412105

Feb 2023

Date	Work done	Doctor	Sign
2/2/23	Tracing of Kashvi Saxena	Dr. Sanjeet Utekar	[illegible]
7/2/23	Tracing of Shivanjali Jagade	Dr. Shirish Gama	[illegible]
7/2/23	Tracing of Ashlesha Jadhav	Dr. Mrunali Zane	[illegible]
9/2/23	Tracing of Kajal Goud	Dr. Sanjeet Utekar	[illegible]
13/2/23	Tracing of Mantasha Haque	Dr. Mrunali Zane	[illegible]
15/2/23	Tracing of Shailesh Shingade	Dr. Suni Kalyani	[illegible]

PROFESSOR & HEAD
Dept. of Orthodontics
D Y Patil Dental School
D Y Patil Knowledge City
Charoli (Bk), Via Lohegaon, Pune - 41210

March 23

Date	Work done.	Doctor.	Sign
2/3/23	Tracing of Sakshi Kharat	Dr. Shirish Game	Shirish
6/3/23	Tracing of Krisha Gujari	Dr. Sanjeet. Utekar	Sanjeet
8/3/23	Tracing of Shilpa Sawant	Dr. Shirish Game	Shirish
10/3/23	Tracing of Deepak Aiwale	Dr. Shirish Game	
10/3/23	Tracing of Zohira Shaikh	Dr Sanjeet Utekar	Sanjeet
14/3/23	Tracing of Karan Kakade	Dr Meenali Tare.	[illegible]
16/3/23	Tracing of Sanvesha Mudhakar	Dr. Sunil Kalyanwar	[illegible]

PROFESSOR & HEAD
Dept. of Orthodontics
D Y Patil Dental School
D Y Patil Knowledge City
Charoli (Bk), Via Lohegaon, Pune 412105

April 23

Date	Work done	Doctor	Sign
3/4/23	Lateral Ceph tracing of Tushara Pamidi	Dr. Shirish Game.	[signature]
6/4/23	Tracing of Shweta Salunke	Dr. Sanjeet Utekar	[signature]
10/4/23	Tracing of Trupti Khandane	Dr. Shirish Game	[signature]
10/4/23	Tracing of Rhishabh mallasamani	Dr. Mounali Tare	[signature]
13/4/23	Tracing of Sharvari Patil.	Dr. Sanjeet Utekar	[signature]

[signature]

PROFESSOR & HEAD
Dept. of Orthodontics
D Y Patil Dental School
D Y Patil Knowledge City
Ozarde (Bk), Via Lohegaon, Pune - 412105

May-23

Date	Work done.	Doctor.	Sign
3/5/23	Demonstration of to interns	Dr. Shailesh	
8/5/23	Lateral Ceph. tracing of Mansi Kapse	Dr. Shirish Gaine	
9/5/23	Tracing of Rehnuma Khan	Dr Sanjeet Uttam	
9/5/23	Lateral Ceph. tracing of Pankaj Agasti	Dr. Shirish Gaine	
11/5/23	Tracing of Tejaswini gaikwad	Dr. Anand Tone	

PROFESSOR & HEAD
Dept. of Orthodontics
D.Y.Patil Dental School
D Y Patil Knowledge City
Charoli (Bk), Via Lohegaon, Pune

June 23

Date	Work done	Doctor	Sign
2/6/23	Lateral Ceph. Tracing of Siddhi Thorane	Dr. Abhirish Game	
5/6/23	Tracing of Ruchika Gadve	Dr. Sanjeet Utekar	
5/6/23	Tracing of Gayatri Baviskar	Dr. Abhirish Game	
9/6/23	Tracing of Yusuf Tanwar	Dr Sanjeet Utekar	
12/6/23	Tracing of Isha bishnoi	Dr. Mrunali Tone	
13/6/23	Tracing of Sanvi Tagade	Dr Sanjeet.	
15/6/23	Tracing of Baljeet singh	Dr. Mrunali Tone	

PROFESSOR & HEAD
Dept. of Orthodontics
D Y Patil Dental School
D Y Patil Knowledge City
Charholi (Bk), Via Lohegaon, Pune-412105

July 23

Date	Work done.	Doctor.	Sign
5/7/23	Tracing of Radyesa chavan	Dr. Sanjeet Ukekar	Sanjeet
6/7/23	Tracing of Sayali Gholap	Dr. Shirish Gaur	Shirish
6/7/23	Tracing of Vardhan Sonsuna	Dr. Sanjeet Ukekar	Sanjeet
7/7/23	Tracing of Abhishek Dhir	Dr. Shirish Gaur	Shirish
10/7/23	Tracing of Akshara Dixit	Dr. Sanjeet Ukekar	Sanjeet
12/7/23	Tracing of Rohit meghavat	Dr. Neenali Tare	Neenali
14/7/23	Tracing of Sonal Lokhande	Dr. Neenali Tare	Neenali
15/7/23	Tracing of Shivani Pawar	Dr. Sanjeet Ukekar	Sanjeet
19/7/23	Tracing - Divij tyagi	Dr Aalankha	A
20/7/23	Tracing - Nivisha gain	Dr Aalankha	A

PROFESSOR & HEAD
Dept. of Orthodontics
D Y Patil Dental School
D Y Patil Knowledge City
Charholi (Bk), Via Lohegaon, Pune - 412105

Aug 23

Date	Work done	Doctor	Staff Sign.
2/8/23	Dakshi Patel lateral Ceph tracing done	Dr. Shirish Game	
7/8/23	Tracing of Vedika Pathare	Dr Sanjeet Utekar	Sanjeet
7/8/23	Tracing of payal kiste	Dr Munalitone	
9/8/23	Tracing of Monika Gilhe	Dr. Sanjeet.	Sanjeet
10/8/23	Tracing - Onkar gadge	Dr Balanlaha	
14/8/23	Tracing Kshitija Gaikwad	Dr Balanlaha	
17/8/23	Tracing Swati Sonawane	Dr Balanlaha	

PROFESSOR & HEAD
Dept. of Orthodontics
D Y Patil Dental School
D Y Patil Knowledge City
Charoli (Bk), Via Lohegaon, Pune- 412105

Record Book Details

Department Of Conservative Dentistry

Record Book

D Y PATIL GROUP

D Y PATIL DENTAL SCHOOL

Dr. D. Y. Patil Knowledge City, Charholi (BK), Via - Lohegaon, Pune - 412 105

THIRD AND FOURTH YEAR B.D.S

DEPARTMENT OF CONSERVATIVE DENTISTRY, ENDODONTICS & ESTHETIC DENTISTRY

CLINICAL RECORD BOOK

NAME: Sakshi . S. Ambatkar.

ROLL NO: 01 BATCH: A

YEAR: 2022 - 2023

MUHS Seat No:

External Examiner's signature: 1.8.23

Internal Examiner's signature:

D Y PATIL GROUP

D Y PATIL DENTAL SCHOOL

Dr. D. Y. Patil Knowledge City, Charholi (BK), Via - Lohegaon, Pune - 412 105

DEPARTMENT OF CONSERVATIVE DENTISTRY, ENDODONTICS AND ESTHETIC DENTISTRY

CLINICAL RECORD BOOK

CERTIFICATE

This is certify that Mr./Ms. Sakshi. S. Ambatkar .

Examination No. _____ *has successfully completed all the exercises in Pre-Clinical Conservative Dentistry And Endodontics as per the Maharashtra University of Health Sciences requirements for third and fourth year B.D.S course*

INCHARGE
Department of Conservative Dentistry
Endodontics and Esthetic Dentistry

DATE: _____

PROFESSOR & HEAD
Dept. of Conservative Dentistry
& Endodontics
D Y Patil Dental School
Dr. D. Y. Patil Knowledge City
Charholi (BK), Lohegaon, Pune-412105.

PROFESSOR & H.O.D.
Department of Conservative Dentistry
Endodontics and Esthetic Dentistry

DATE: 23/03/23

INSTRUCTIONS

1. Discipline and punctuality is expected throughout the clinical postings.
2. Each student should wear a clean white apron. Shirt sleeves should be folded properly above the elbow.
3. Long hair should be tied at the back and the head cap should be worn.
4. Long nails, nail polish and mehendi are strictly prohibited.
5. Use of facemask, protective eyewear and head cap is mandatory.
6. Remove all jewellery including wristwatches and rings before wearing gloves.
7. Each student must possess two sets of instruments during their practical posting and examinations. Lending or borrowing of instruments will never be allowed.
8. Each student should possess adequate knowledge about instruments and all equipments and working of the dental chair before handling them. No procedure should be carried out without taking permission and guidance from the staff.
9. Report any damage/breakage of equipment immediately to the concerned staff member.
10. Maintain cleanliness during work and avoid wastage of dental materials. Remember that each patient deserves skillfully performed procedures.
11. Fundamentals of operative dentistry must be well understood and reviewed periodically by the student.
12. Conservation of tooth structure, clean-cut tooth preparation, isolation of operating field, proper pulp protection and good aesthetics are important aspects of clinical procedures carried out in the department.
13. Students should bring their record book on each day of their posting and record book should be regularly updated and duly signed by the instructor.
14. Approval of each procedure performed by the student from the instructor and immediate entry in the record book is imperative.
15. Marks will be credited for this record book at the University Examination.

RULES TO BE FOLLOWED IN THE CLINICS

1. Disinfect your working area by using spray-wipe-spray technique.
2. Pleasantly greet the patient in the reception area by name and request that he or she follows you to the treatment area.
3. After the patient is seated in the chair, bring the chair into position, drape the patient, turn on the operating light.
4. Scrub your hands with soap and thoroughly wash them, dry them and put on the gloves. Discard the gloves after single use. Replace torn or damaged gloves immediately.
5. Clinical examination of every patient is mandatory. Record your findings in the patient's record paper and also in your journal. Get it approved by your instructor.
6. Clearly communicate to the patient about his/her dental diagnosis and the procedure(s) required. Explain the treatment plan to the patient; take an informed consent before commencement of the operative procedure.
7. Get each and every step of the operative procedure approved by your instructor.
8. After the completion of operative procedure, give proper post operative instructions and schedule the next appointment for him/her.
9. Check the patient's face for smudges or debris, gently remove them with moist cotton / tissue
10. Bring the chair to the (rest) position before asking the patient to leave the chair.
11. Used instruments should be cleaned and rinsed in tap water before placing them in the ultrasonic cleaner.
12. Students are expected to dry the instruments retrieved from ultrasonic cleaner, neatly pack them in their sterilization pouches These pouches should be handed over to the staff nurse for sterilization.

LIST OF INSTRUMENTS

Diagnostic Instruments: (2 sets each)

1) Mouth mirror with handle
2) Straight probe
3) Williams graduated probe
4) Double ended explorer
5) Tweezer

Instruments for tooth preparation:

A) Hand Instruments: (2 sets each)

1) Single ended straight enamel chisel (2mm)
2) Double ended unibevelled enamel Hatchet (2mm)
3) Double ended Gingival Marginal Trimmer 77/78 and 79/80
4) Double ended spoon excavator -Small & Medium size

B) Rotary Instruments:

Sr. No.	Instruments	
1.	Contra - angled handpiece for Micromotor (Slow speed)	
2.	Contra - angled handpiece for Airotor (High speed)	
3.	Diamond points - (FG & Latch type) (2 sets each)	Size -10/12 Shape - Round, Straight, Inverted Cone, Tapered Fissure (short and long), Pear shaped.
4.	Carbide burs (latch type)	Round (Small and Medium size) ;

Plastic Filling Instruments: (2 sets each)

1) Cement Spatula - Short & stiff blade
   - Long & flexible blade
2) Agate Spatula.
3) Cement Carrier - Double ended instrument with one end rounded
4) Double ended round Amalgam Condenser (small)
5) Double ended parallelogram Amalgam Condenser 155/153
6) Amalgam Carrier No. 5
7) Double ended ball Burnisher
8) Amalgam carvers
   - Wards
   - Frahms
   - Hollenbeck
9) Composite filling instruments (plastic)

Finishing and Polishing instruments:

1) Hand
   1. Finishing Strips - Fine, Medium and Coarse.
2) Rotary
   1. Finishing burs or points for silver Amalgam restoration (round and flame shape).
   2. Polishing brush and rubber cup.
   3. Composite finishing and polishing kit.
   4. Impregnated finishing disks - Assorted.

SUPPLEMENTRY INSTRUMENTS

1. Stainless steel tray with lid - 8" 3"
2. Enamel tray - 18" 18"
3. Mackintosh sheet - 18" 18"
4. Rubber bowl - Small and Large
5. Plaster spatula - Straight
6. Plaster knife
7. Wax spatula & knife
8. Glass slab - Thick
9. Chip syringe with bulb
10. Dappen dish - 2 Different Colours
11. Cotton Holder - Stainless steel
12. Waste receiver - Stainless steel
13. Matrix band retainer - Ivory No.1, Ivory No.8
14. Matrix bands - Ivory No.1 (Assorted Pk.)
(Premolar and Molar bands 0.038mm & 0.05mm)
Ivory No.8 (Assorted Pk.)
(Premolar and Molar bands 0.038mm & 0.05mm)
15. Celluloid/Mylar strips.
16. Wooden wedges - Assorted sizes
(Blades to shape the wedges)
17. Mortar & pestle - Ground glass
18. Curved stainless steel surgical scissors. - Small
19. 0.5 mm pencil marker
20. Ruler (6")
21. Hand gloves size. – As per individual size.
22. Face mask

CLASS I TOOTH PREPARATIONS

Sr. No.	Case No.	Name of Patient	Gender	Age
1		Shweta Jadhav	Female	18yrs
2		Gyanlata Pandey.	Female	30yrs
3		Kavita Chavan	Female	42yrs

DENTAL AMALGAM RESTORATIONS

Date	Tooth No.	Tooth Preparation		Pulp Protection/ Base and Matricing		Restoration		Total (30)
		Marks (15)	Sign	Marks (5)	Sign	Marks (10)	Sign	
03/02/22	36							
29/09/22	36	14/20		5/10		14/20		
01/10/22	46	15/20		7/10		15/20		

CLASS II TOOTH PREPARATIONS

Sr. No.	Case No.	Name of Patient	Gender	Age
1		Ranchan Arora	Female	24 yrs.
2		Rewita Chavan	Female	42 yrs.
3		Ankush Waghade	Male	36 yrs.
4		Mohammad Shaikh.	Male.	22 yrs.
5		Sameer Mahbdi.	Male	

DENTAL AMALGAM RESTORATIONS

Date	Tooth No.	Tooth Preparation		Pulp Protection/ Base and Matricing		Restoration		Total (30)
		Marks (15)	Sign	Marks (5)	Sign	Marks (10)	Sign	
24/09/22	24		B²		B²		B²	
03/10/22	47	15/20	4/10/22	8/20	4/10/22	14/20	4/10/22	
17/02/23	16			-	-			
22/02/23	46		22/2/23		22/2/23		22/2/23	
23/02/23	25	14/20	24/2/23	5/10	24/2/23	14/20	24/2/23	

CASE RECORDS

Diagnosis & Treatment planning in Conservative Dentistry

Name of the patient: Rajkumar Gautam

Age: 31 yrs

Address: Pune

Tel. No. 7841949832

Occupation: Service.

Registration No. 4223

Date: 23/09/22.

Gender: Male.

Emergency Contact: 9841949832

DENTAL RECORD

Chief Complaint: Patient complains of pain after food lodgement in upper right Back region of Jaw since 2-3 months.

History of present illness: Patient was apparently asymptomatic 3 months back until he experienced pain after food lodgement in maxillary left posterior region of Jaw. Pain is sharp, shooting & localized in nature. It is lingering & lasting for about 5 to 10minutes pain aggravates on pressure on mastication & relieves on its own. Patient has no history of nocturnal pain, swelling & pus discharge.

Past Dental Experience:

Tooth coloured Restoration $\frac{\bar{C}}{6|}$ (4 yrs Ago)

Subjective symptoms:

Tooth / Region

Pain:	Present ✓		Absent
Location:	Localized ✓	Diffused	Referred
Duration:	Seconds	Minutes ✓	Hours
Quality:	Sharp ✓	Dull	Throbbing
Onset:	Stimulated ✓	Spontaneous	
Increased by:	Cold	Heat	Pressure ✓
	Postural Change	Sweet	Sour
Relieved by:	Cold	Heat	Medication ✓

Medical History:

A) Record of any present illness: NO Relevant History

i) Cardiac disease

- Anginal / Coronary
- Pacemaker
- Congenital heart disease
- Rheumatic fever

ii) Abnormal bleeding

- Blood dyscrasias

iii) High blood pressure

iv) Anemia

v) Diabetes

vi) Hepatitis

vii) AIDS / HIV

viii) Asthma

ix) Tuberculosis

x) Arthritis

xi) Sinus trouble

xii) Epilepsy

xiii) Stroke

xiv) Psychiatric treatment

xv) Cancer treatment / Radiation therapy

B) Any medicines or drugs taken in the past or current medication → 1) Amoxicillin 2) Aceclofenac 3) Pantoprazole.

C) Allergy to any drug/drugs – NRH

D) Any prosthesis inserted into the body NRH

E) Any Surgery in the past with or without blood transfusion NRH.

F) For Women Pregnancy Y/N

Nursing Y/N

G) Any other relevant findings NRH

EXAMINATION

A) General Examination:

Built
Stature
Gait
Posture

} No Abnormality Detected.

B) Extraoral Examination:

- Symmetry Grossly Bilaterally symmetrical
- Swelling: Hard Soft Diffused Localized
  Dimension and extent
- TM Joint No clicking sound, No deviation
- Lymph nodes Not palpable, Non tender
- Sinus/Fistula Absent

C) Intraoral examination

i) Soft tissue examination: No Abnormality Detected.

Tongue Mucosa Palate Floor of mouth Gingiva

ii) Swelling: Present Absent ✓

iii) Sinus tract opening: Absent

iv) Oral hygiene: Good Fair ✓ Poor

v) Occlusion: Harmonious ✓ Non-harmonious

vi) Current status of dentition

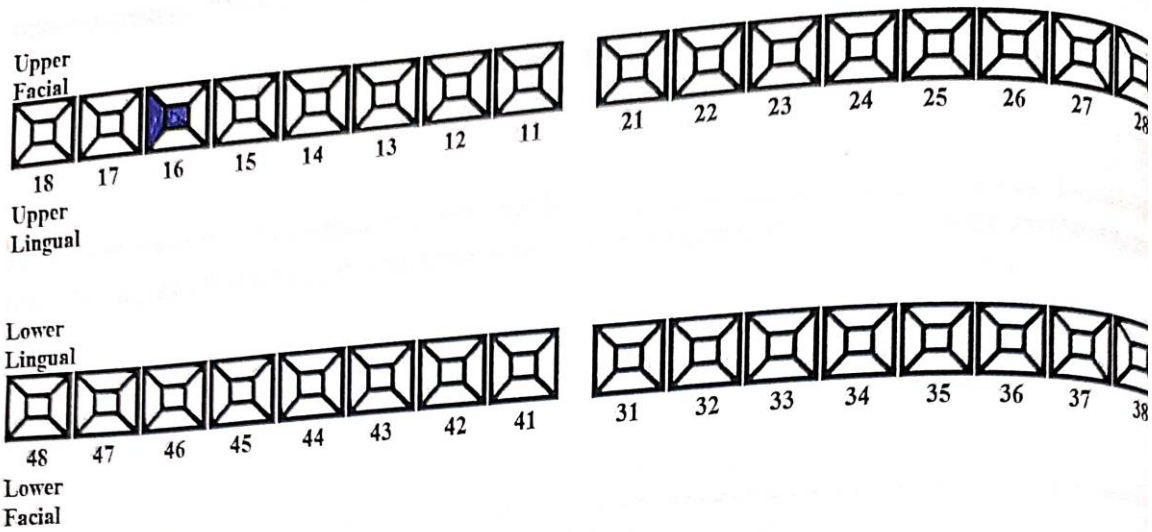

Notation:

Caries -		R.C. treated –	R.C.
Restoration present -		Attrition -	
Secondary caries -		Abrasion / Erosion –	
Tooth missing -	A	Crown present –	C
Discoloration -		Vertical fracture –	#
Tooth fracture -	F		

Distoocclusal caries $\bar{c}$ 6/
pit & fissure caries $\bar{c}$ /7
occlusal caries $\bar{c}$ /4
Occlusal fault $\bar{c}$ /6

(14)

CLINICAL EXAMINATION OF AMALGAM RESTORATIONS:

- Amalgam blues
- Proximal overhangs
- Marginal ditching
- Voids
- Fracture lines
- Improper anatomic contours
- Marginal ridge incompatibility
- Improper proximal contacts
- Recurrent caries
- Improper occlusal contacts

} No Relevant Finding.

CLINICAL EXAMINATION OF CAST RESTORATIONS NRF

⇨ Defective, Proximal overhang, Improper contours, Fractured tooth/Restoration, Secondary caries.

CLINICAL EXAMINATION OF TOOTH COLORED RESTORATION.

1) Improper contour
2) Proximal contact
3) Overhanging proximal margin
4) Recurrent caries
5) Marginal staining.
6) Fracture

} NRF

EXAMINATION OF NON-CARIOUS LESIONS

ATTRITION

ABRASION

EROSION

ABFRACTION

} No Relevant Finding

EXAMINATION OF AREA OF CHIEF COMPLAINT:

a. Tenderness on palpation Positive

b. Pain on percussion Positive

c. Mobility Absent

d. Furcation involvement Absent

e. Pulp vitality tests

Thermal test: Heat Cold ✓

i. No response
ii. Moderate transient response
iii. Painful response which subsides quickly after removal of stimulus
iv. Painful response that lingers after removal of stimulus

f. Electric pulp test

	Control tooth	Test tooth
	Response at number	Response at number

Caries Diagnosis:

1. Clinical Examination for caries:
   a) Visual changes - Surface Texture - soft consistency
   - Colour Blackish discolouration
2. Tactile sensation
3. Radiographs Radiolucency involving enamel, dentin & approaching pulp. ROPA-61
4. Transillumination.

Categorization of Adults According to Caries Risk indicators:

Caries Risk Category

Low: - No carious lesions in last 3 years.

Adequately restored surfaces

Good oral hygiene

Regular dental Visits

Fluoride dentifrice use

Medium: -

Presence of two of the following indicators:

Current orthodontic treatment or removable appliance or several exposed root surface or poor oral hygiene or frequent fermentable carbohydrate intake or inadequate exposure to topical Fluoride.

High:- Presence of one of the following indicators:

Any carious lesion in previous 2 years or inadequate salivary flow or initial enamel interproximal radiolucencies or presence of >2 of the risk indicators shown in the medium risk category.

Provisional Diagnosis:

Chronic Irreversible Pulpitis c 6/

→ a) Region - maxillary right post. Region
b) Teeth completely seen - 765/ Teeth partially seen are 14. Most pathologic tooth is 16.
Crown - Diffused radiolucency involving enamel, dentin reaching pulp.
2 intact Roots with patent Root canal
PDL space is widen with discontinuous lamina dura. No Periapical Radiolucency seen. Intact interdental crest seen.

Investigations and interpretations :

i) Radiographs: Intraoral periapical ✓

Bitewing

O.P.G.

Any other

ii) Blood tests:

iii) Any other:

Final Diagnosis:

Pulpal — Reversible / Irreversible ✓

Periapical Pathology:

1) Acute apical periodontitis
2) Chronic apical periodontitis
3) Periapical granuloma
4) Periapical cyst
5) Acute dentoalveolar abscess

Radiographically - loss of lamina dura & widening of PDL space.

Prognosis: fair.

Treatment Plan:

i) Urgent phase

Access opening c 6/

ii) Control phase

oral prophylaxis.

iii) Re-evaluation phase

iv) Definitive phase

1) cleaning & shaping c 6/

2) obturation c 6/

3) post Endodontic Treatment c 6/

4) Prosthesis c 6/

v) Maintenance phase

Recall after 6-8 months.

Signature of instructor :- **Date:-**

Dental Anatomy

Record Book

D Y PATIL DENTAL SCHOOL

Department of Oral Pathology and Microbiology

This is to certify that **Intern** Roll No ..22.. named ~~Mr/Mrs~~ Gatkal Deepti

has satisfactorily completed the work of this department as per the DCI guidelines.

I herby give him/her the certification of internship completion from this department

Date: 30/09/2019

Signature

Head of the Department

Department of Oral Pathology and Microbiology

D.Y. Patil Dental School Department of Oral Pathology PUNE

Department of Oral Pathology and Microbiology

GROUND SECTIONS

Sr. No	Date	Nature of the specimen	Findings	Staff Signature
1.	19/9/2019	T.S of Bone	Haversian canal	
2.	21/9/2019	Ground section of tooth	Enamel spindle	
3.	23/9/2019	Ground section of tooth	Inter-globular dentin	
4.	23/9/2019	Ground section of tooth	Sharpey's fibers	
5.	24/9/2019	Ground section of tooth	Sclerotic dentin	
6.	24/9/2019	Ground section of tooth	Dead tract	
7.	24/9/2019	Ground section of tooth	Neonatal line	
8.	26/9/2019	Ground section of tooth	Incremental lines	
9.	28/9/2019	T.S of tooth	Dentinal tubules	
10.	28/9/2019	Ground section of tooth	Dentino-enamel junction	

Signature

Head of the Department

Department of Oral Pathology and Microbiology

D.Y. Patil Dental School * Department of Oral Pathology * PUNE

Department Of Orthodontics And Dento- Facial Orthopaedics

Record Book

D Y PATIL GROUP

D Y PATIL DENTAL SCHOOL

Dr. D. Y. Patil Knowledge City, Charholi (BK), Via - Lohegaon, Pune - 412 105

JOURNAL OF ORTHODONTICS & DENTOFACIAL ORTHOPEDICS

NAME: Mrunali Gopal Bari.

ROLL NO: 04. **BATCH:** Summer (A)

YEAR: 2022-23

MUHS Seat No: 49551

D Y PATIL GROUP

D Y PATIL DENTAL SCHOOL

Dr. D. Y. Patil Knowledge City, Charholi (BK), Via - Lohegaon, Pune - 412 105

JOURNAL OF ORTHODONTICS & DENTOFACIAL ORTHOPEDICS

CERTIFICATE

Mr./Ms. Mrunali Gopal Bari.

Roll No. 04 *has Attended and Completed all*

The Practicals Recorded in this Journal.

Date: 24/07/23

Signature of The Staff In-charge

Signature of The Head of Dept.

PROFESSOR & HEAD
Dept. of Orthodontics
D Y Patil Dental School
D Y Patil Knowledge City
Charholi (Bk), Via Lohegaon, Pune - 412105

Signature of External Examiner

INDEX

ROLL NO :- 04

CLINICAL & PRACTICALS IN ORTHODONTICS

SR NO	DATE	PRE CLINICAL WORKS DONE	GRADE	SIGN
		Basic wire bending exercise gauge		
		a. Straightening of wires		
	16/02/21	19 gauge	A A	
	17/11/21	21 gauge	A A	
1	15/12/21	b. Bending of a equilateral triangle	B+	
	16/12/21	c. Bending of rectangle	B++	
	15/12/21	d. Bending of square	B+	
	17/12/21	e. Bending of circle		
	07/04/22 16/11/22	f. Bending of a U. V. A	A	B+
		Construction of Clasps		
		a. ¾ clasp (C-clasp)		
	16/11/22	Maxillary arch	A A	
	17/11/22	Mandibular arch	B	
		b. Full clasp (Jackson's Clasp)		
2	17/11/22	Maxillary arch	A A	
	19/11/22	Mandibular arch	B A	
		c. Adam's Clasp		
		Maxillary arch		
		Mandibular arch	A A	
		Construction of Springs		
3	21/11/22	a. Finger Spring	A A	
	23/11/22	b. Double Cantilever Spring (Z-spring)	B A SHORT A A LONG	
		Construction of Canine retractors		
		a. U - Loop Canine retractor		
4		Maxillary arch	A A	
		Mandibular arch	A B	
		b. Helical Canine retractor		

INDEX

ROLL NO :- _____

CLINICAL & PRACTICALS IN ORTHODONTICS

SR NO	DATE	PRE CLINICAL WORKS DONE	GRADE	SIGN
		Maxillary arch	A B	
		Mandibular arch	A A	
		b. Buccal (self-supported) canine retractor	A B	
		d. Palatal canine retractor	A A	
5		**Labial Bow** Short Grade Long Sign	Long Grade	Sign
	06/04/23	Maxillary arch B+	A	
		Mandibular arch A B	A	
6		**Making upper Alginate impression**	B+	
7		**Making lower Alginate impression**	B+	
8		**Study model preparation**		
9		**Model Analysis**		
		a. Pont's analysis		
		b. Ashley Howe's analysis		
		c. Carey's analysis		
		d. Bolton's analysis		
		e. Moyer's Mixed Dentition Analysis		
10		**Case History**	A	
11		**Case discussion**	B	
		Cephalometric Tracings		
		a. Down's Analysis	A	
		b. Steiner's Analysis		
		c. Tweed's Analysis		
13		**Coffin spring on upper arch Gauge 1 mm**		
14		**Appliance construction in Acrylic**		
		a. Upper Hawley's Appliance		
		b. Lower Hawley's Appliance		
		c. Upper Habit breaking Appliance		

Introduction

The ideal property required for tooth movement is the production of line, optimal continious force. Hence the most important requirement of an orthodontics were relate to mechanics of tooth movement.

For the given appliance, the design to be succesfull, the mechanical properties of wire which will be considered are.

Mobility
Ductility
Malleability
Stiffness
strength
Corrosion resistance
Ability to be welded & soldered.
Biocompatible.

- Classification of orthodontic wire.

1. Noble metal
2. Stainless steel wire
3. Titanium alloys
4. Non-metal alloys.

1] Noble Metal.

- Example : Silver, Platinum, Gold
- These wires are very expensive though they are quite elastic.

Disadvantage : I. Expensive.
II. They have large cross section for adequate thickness

2. Stainless steel wire.
- They have all the required ideal properties.
- Most commonly used wires.
- However in comparison to NiTi, they are less elastic.
- The most commonly used Stainless steel wire is 18 : 8 alloy (18% chromium, 8 % Nickel)
- A typical orthodontic appliance is made in 18 : 8 wire.
- A composition of wire is 1] 18 % chromium - for corrosion resistance 2] 8 % Nickel - make it austentic at room temperature.
- 74 % Iron & 40.50 % Carbon, the iron & carbon from the structured composition which imparts strength to steel.
- Increase in carbon content would increase hardness but makes structures more brittle.

3. Titanium Alloys.
- These are highly elastic wires.
- They are used in appliances for treatment purposes.
- Examples : NiTi and Tm A.
TmA is not solderable nor weldable

4. Non - Metal Alloys.
- Wire has aesthetic appearance. Stable in oral environment. eg. optiflex wire.



Exercise 01.

Aim : To straighten a 6 inches piece of 19 gauge HRSS (Hand round stainless steel) wire in all planes.

The Tests for straightend wire are

- It should roll freely on glass slab.
- There should be no gap between the wire and glass slab.





Exercise 02.

- Aim :

To straighten a 6 inches piece of 21 gauge HRSS (Hand round Stainless steel) wire in all planes.

- The tests for straightened wire are.

i. It should roll freely on glass slab.

ii. There should be no gap between the wire & the glass slab.



Exercise 03.

Aim : To prepare an equilateral triangle of each side 5 cm of 19 gauge HRSS wire.

Procedure :

I. An equilateral triangle of sides 2 inches each is prepared using a 19 gauge HRSS wire.
II. Firstly 7 inches wire is straightened.
III. From one end of this wire mark 1 inch length with glass marking pencil.
IV. This will be the first point of the first bend to form an equilateral triangle.
V. An 90° bend is given using rectangular beak at the piece.
VI. Then the piece is held a little away from the formed angle more acute.
VII. This is repeated till the angle becomes 60°. Check the parts for equality at the plane of the triangle.
VIII. Mark the point at 2 inches length & repeat same.
IX. Keep in mind the plane of all sides of the triangle till the end meets the starting end.
X. Check the formed triangle for sides angles & planes on the graph paper with a triangle of 2 inches length drawn on it & check the plane on glass slab.

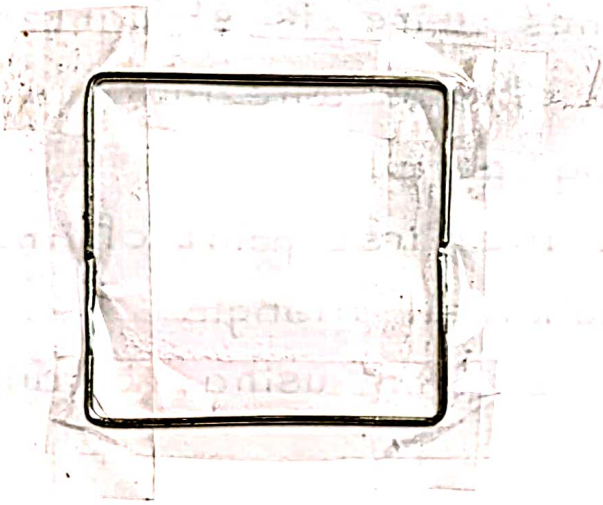

Exercise 04.

Aim : To prepare a square of each side 4 cm using a 19 gauge HRSS wire.

Procedure :

- The square is made using a 19 gauge HRSS wire.
- A wire of 16 cm length is straightened.
- 4 cm is marked from one end of wire with a glass marking pencil.
- At the point, the wire is bent to form square.
- A 90° bend is given using the rectangular end of the plier.
- The two parts of wire are checked for plane.
- Next measurements are marked & procedure is repeated. till a square is formed keeping in mind that the plane of all 4 sides of square till the end meets.
- The excess is cut.
- The dimensions are checked with a graph paper.



Exercise 05.

Aim : To prepare a Rectangle of sides 5 x 3 cm by using a 19 gauge HRSS wire.

Procedure :

- The rectangle of sides 5 x 3 cm is prepared by using 19 gauge HRSS wire.
- Firstly 2.5 cm wire is marked & bent in 90° angle.
- Then mark 3 cm & the procedure is repeated i.e bending in 90°.
- Now mark 5 cm and bend. After each bend check for the plane on glass slab.
- Now bend on 3 cm marking.
- Lastly 2.5 cm should be marked and bent till it meet another end.
- Cut excess of wire.
- Check the dimensions on rectangle drawn on graph paper.



Exercise 06.

Aim : To prepare a circle with diameter 5 cm from 19 gauge wire HRSS wire.

Procedure :

- The circle is made using 19 gauge wire
- 6-7 inches wire piece is taken and wire is curved using pulp of finger.
- Step by step. the free end is curved by a piler.
- An accurate diameter of circle is obtained
- Care is taken during formation of circle that there are no sharp bends or kinks.
- The circle is completed by approaching the two ends with each other.
- The dimensions are checked on graph paper as well as its adaptation on glass slab.







Exercise 07.

Aim : To prepare an U series, V series and a UV series from a 19 gauge wire

Procedure :

- Prepare a UV series of U of height 1 cm and V of height 1 cm leaving a gap between each V and each U of 1 cm.
- Take a 19 gauge wire of 9 inches & make it straight.
- Now mark at 1cm & give a bend at 90° Now at approx 0.7 mm start giving a slight bend using plier till the height of U reached 1 cm.
- Now again repeat this procedure to make 5 'U' with 1 cm gap in between each 'U'
- For V series, mark at 1 cm. and give a bend and V should be of 1 cm height, so give bend accordingly.
- In this way 5 V's are prepared with 1 cm gap in between each V.
- check the plane on glass slab.
- For UV series make U & V alternately and check the plane on glass slab.

Circumferential Clasp.

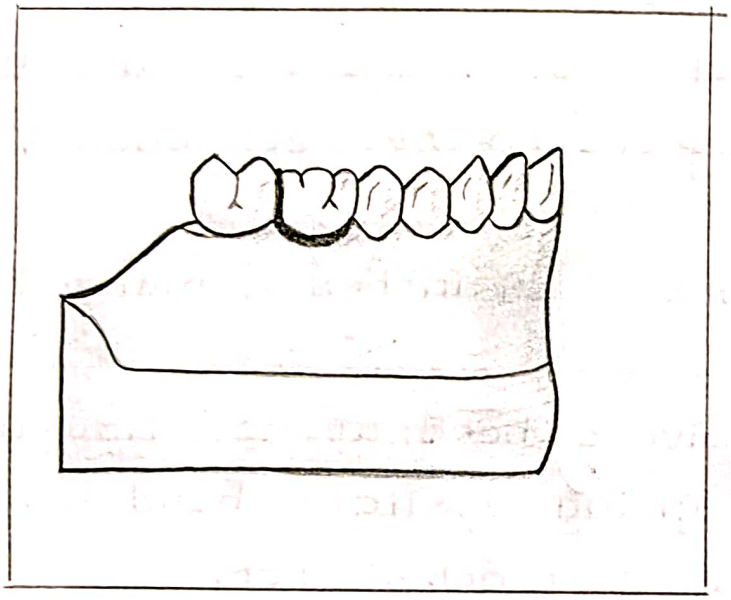

Exercise 08.

- Aim : To prepare a 'C' clasp from 19 gauge wire.
- Defination. : A 'C' clasp is a passive removable appliance which is used to provide retention to the appliance also called as circumferential clasp or a 3/4 th clasp.
- Requirement : It should be rigid.

II. It should give or have excellant retention without causing retention. irritation to gingival tissue.

III. It should not undergo distortion during mastication & insertion on removal of appliance.

IV. It should be easy to fabricate & should be replaceable.

- Procedure :

I. A 19 gauge wire bent following a cervical line / countour of tooth using universal plier.

II. The wire should be adapted into the distal embrassure of area & it should go untill it reaches the supplied aspect of contact point between two teeth.

The first occlusal point between two teeth.

The first occlusal pt 'C' clasp should follow the occlusal part of interdental anatomy which in case of molars is in U shape.

V. This bend is given to adapt wire occlusally.

There should be a gap of 0.5 - 0.7 mm between Tag arm & cast.

Jackson's Clasp

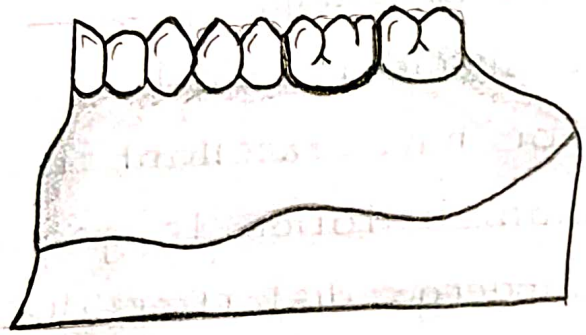

Exercise 09.

- Aim : To prepare a 'U' clasp from 19 gauge wire.
- Defination : This clasp engages the buccocervical undercut and also the mesial as well as distal proximal undercuts. It is called Jackson's clasp or 'U' clasp or full clasp.
- Requirement : I. It should be rigid.
  II. It should give excellent retention. without any irritation to gingival tissue.
  III. It should not undergo distortion during mastication & insertion on removal of appliance.
  IV. It should be easy to fabricate and be replacable.
- procedure :

1. A 19 gauge wire is adapted along bucco-lingual margin & both proximal undercuts then carried over occlusal embrassure to entire retentive arm on both sides of Molar.
2. M bend is given to adapt wire occlusally.
3. There should be a gap of 0.5 - 0.7 mm between the arm to cast. Bend it into loop, Just in turn 90° angle.

Adam's Clasp



a. Buccal view

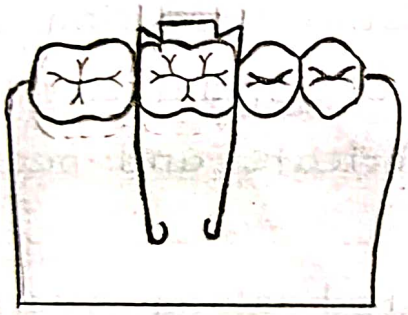

b. occlusal view

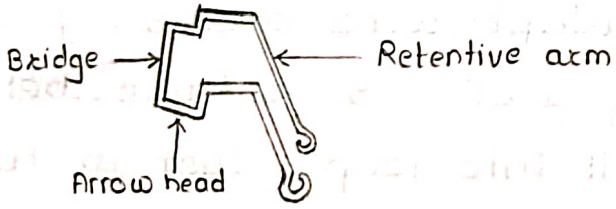

Exercise 10.

- Aim : To prepare an 'Adam's clasp'
- It was first given by Dr. C.P. Adam It is also called as universal clasp. Liverpool clasp or Modified arrow head clasp.
- Procedure :

A 22 gauge wire is used to construct an Adam's clasp.

First measure 2/3 rd of Mesiodistal dimensions of teeth or buccal S/F and then their corresponding points are marked on the wire.

Bends are given on the point keeping the angle approx 60°

In this way bridge of clasp is prepared.

Arrowheads are prepared by giving outward & downward bent at this point. The million dollar bent at this point It is given by holding plier at one half of the arrowhead The two arrowheads should be mesiobuccal & distobuccal line angle.

The prepared arms of the arrowheads are then adjusted to coincide with them.

They are adapted interproximally by giving interproximal bend. Tag arms are made as in C-clasp.

Orthodontic Appliances.

These are divices used to apply force on a tooth/ group of teeth in predetermined direction to move a tooth to the desired direction.

- Classification.

They are divided into 3 groups.

Group A - 1. Mechanical 2. Functional.

Group B - 1. Active 2. Passive.

Group C - 1. Fixed 2. Removable.

A] 1. Mechanical Appliances :

These appliances evert direct pressure on teeth.

2. Functional Appliance. :

These appliances which evert, makes use of various functional forces to bring about tooth movement. Jaw position in desired position.

B] 1. Active Appliances :

These exert active force on teeth to bring about movements.

2. Passive Appliances :

These do not exert any force on tooth.

C] 1. Fixed Appliances.

These are fixed into the teeth/tooth for duration of an active treatment till the teeth are moved.

2. Removable Appliances.

These can be removed by the patient at will.

- Components of Removable Appliances.

I. Base Plate.

made by acrylic & serves following functions.

i. Holds the other components (Active & Passive).

ii. Helps in anchorage.

iii. In selected cases it is thickened & serves as a little platform or inclined plane.

II. Active Component

Used to bring about actual tooth movement.

III. Passive Component.

They are used for retaining the appliances in oral cavity. They are passive & do not exert any pressure on tooth.

Finger Spring

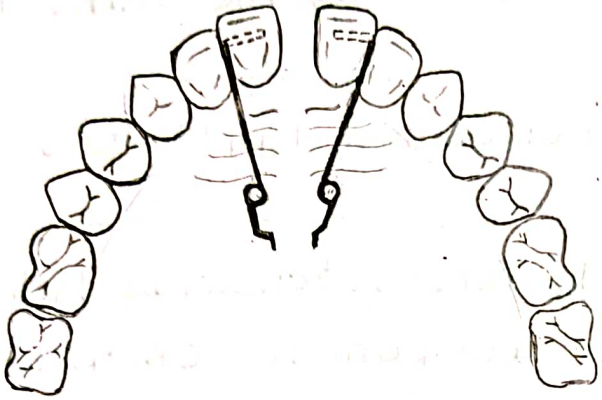

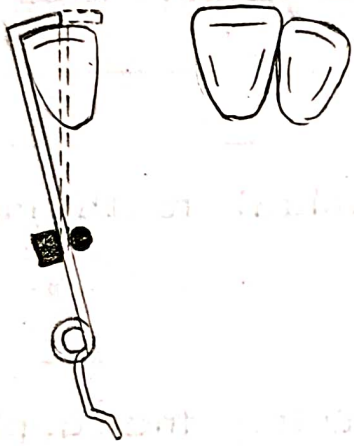

Activation of Finger Spring



Construction of Springs.

1. Finger Spring.

- Aim : To prepare finger spring or palatally approaching Canine retractor.
- Fabrication : 4 inches 23 gauge wire is first straightened. At the end the wire is bend on itself so as to make the end blunt. This will prevent injury to gingival tissue. This end of wire is then adapted interproximally the coil is prepared on the wire with the following criteria.

a] It should project helix & internal diameter should be four times diameter of wire.

b] The active arm coil should be parallel to occlusal plane.

c] The coil should be on opposite side of tooth movement.

d] It should have 1/4 th turn.

- Indication :

This canine retractor is used on Anterior as well as Posterior teeth to either mesialize or distalize tooth.

- Advantages :

I. It is located on parallel side, therefore more esthetic
II. It can be used for both Anterior or posterior teeth.
III. This retractor can either mesialize or distalize tooth.

- Disadvantages.

I. They are normally effective over short distance. as located on palatal side.

II. They tend to interfere with tongue movement.

III. Thus the palatal spring should be boxed & hence it is time consuming.

- Placement of Coil.

It should be situated midway between initial & final position. It should be 6-8 mm away from cervical margin.

After fabrication of coil, A downward vertical bend is given to all to make the coil parallel to occlusal plane.

Double Cantilivet Spring

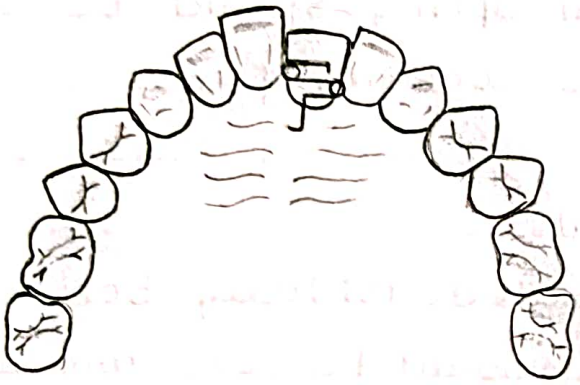

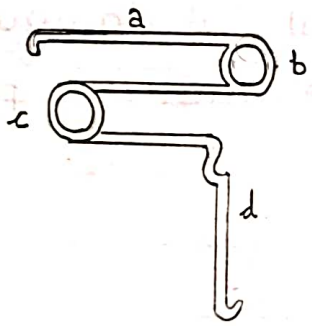

Spring design in double cantilever spring

a : active arm emerges from tissue side.

b : First coil.

c : Second coil.

d : Retentive arm & tag.

Double Contiliver Spring (Z-Spring).

- Aim : To construct Z spring from 23 gauge wire or 0.6 mm HRSS wire.

- Fabrication.

1. Firstly a 4 inches piece of 23 gauge wire is straightened.
2. The end of wire is then bent on itself to make the wire blunt. (bent on crushed loop). The mesiodistal width of the concerned tooth is measured & then transferred on the wire.
3. At that point the first coil is made, Internal diameter should be 4 times the diameter of wire. An active arm should be above the coil. The second coil is then prepared as that mesiodistal width of tooth. All the specifications of previous coil should be maintained

- On the distal arm of second coil. 90° downward vertical bend is given to ensure that plane of spring is maintained parallel to occlusal plane.
- The spring should be adapted to height of cingulum of the tooth.
- The tag arms are fabricated to complete wire bending.
- Boxing is supposed to be done on modelling wax. The purpose of box is to protect spring.

- Indications.

I. To bring labial movement of one or more teeth. correction on mirror rotation.

II. Correction of Anterior cross-bite. (by labial movement of concerned tooth).

- Disadvantages.

I. Palatal spring is time consuming.

II. As it is fabricated in 23 gauge wire, chances of distortion is very high.

U loop Canine Retractor

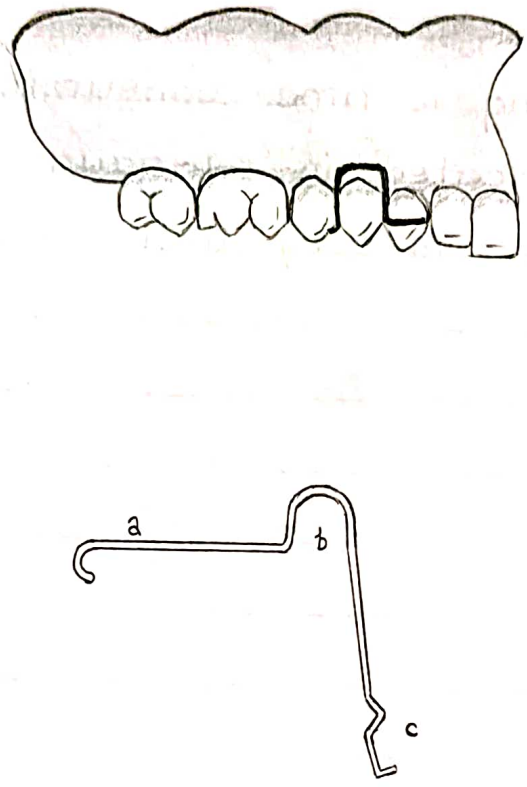

a. Active arm

b. U loop

c. Retentive tag.

Construction of Canine Retractor.

- U loop canine retractor.
- Aim : To construct a U loop canine retractor.
- Procedure :

i. It is made of 0.6 mm or 0.7 mm wire.

ii. It consist of U loop, an active arm & a retentive arm that is distal

iii. The base of U loop should be 2-3 mm below the cervical margin.

iv. The mesial arm of U loop is bent at right angles & adapted around the canine below the mesial contact point.

v. Mechanically it is best effective & is used when minimal retraction of 1-2 mm is required.

vi. It is activated by closing the loops by 1-2 mm or the cutting the free end of the active arm by 2 mm & readapting it.

- Advantages :

I. They are easy to fabricate.

II. They have less bulk.

Helical Canine Retractor

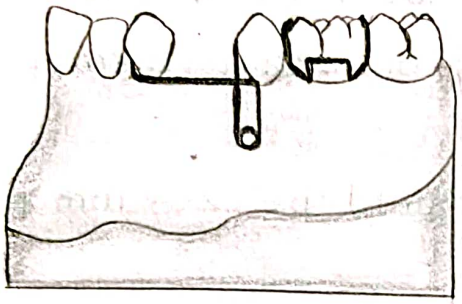

Lateral view.

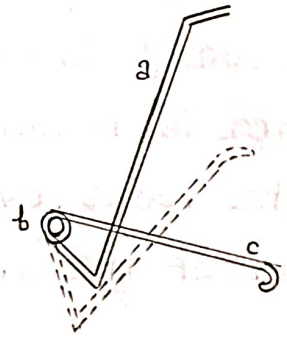

a : Active arm

b : Helix.

c : Retentive arm.

Helical Canine Retractor.

- Aim : Prepare a canine retractor - Helical type.

- Procedure :

- It is fabricated from 23 gauge HRSS wire.
- 4 inch piece of wire is first taken & a coil is then placed with round beak of plier in such a way that there is no gap between the coil.
- Active arm should be adapted over buccal surface of canine.
- A coil should be placed 3-4 mm below the cervical margin of 2nd premolar.
- Tag arm is placed between first & second premolar. Then the active arm is bent at right angles to mesial cervical 1/3 rd of second premolar.
The arm should be parallel to occlusal surface.
The tag arm is bent & adapted on active arm.

- Indications.

The helical type of canine retractor is best suited for retracton of canine in 1st premolar extraction cases. When canine are also well aligned in the dental arch.

- Advantages :

i. Due to presence of coil, it permits gentle forces. Hence requires gentle less activation.

ii. It has wide range of action.

iii. Tag arm is mesial to 2nd premolar, which prevents loss of anchorage.

- Disadvantages

i. It is made up of thinner gauge wire & is likely to distort.

ii. It is difficult to construct.

- Activation.

It is activated by opening the coil by cutting free end of active arm & readapting it.

Box Type Canine Retractor.

- Aim. : To prepare box type canine retractor with 22 gauge wire.

Canine retractor is an active component of removable appliance.

- Classification of canine retractor.

1. Depending upon Position.
   a. Buccal - bucally placed.
   b. Palatal - palatally placed.

2. Based on presence of helix or loop.
   a. Canine retractor with helix.
   b. Canine retractor with loop.

3. Based on mode of action.
   a. Push type.
   b. Pull type.

- Box type : It is buccally placed pull type, without coil type of canine retractor which is made from 22 gauge or 0.7 mm wire HRSS wire.

- Procedure :
- A 4 inch piece of wire is straightened.
- A loop is prepared & adapted to buccal surface & 2nd Premolar

- The loop should extend 2-3 mm below cervical margin (0.5 mm away from gingival seat).
- Both the arms of 'U' shaped box should be parallel to each other.
- A right angled bend is given at junction of cervical and mesial 1/3 rd of 2nd premolar.
- The horizontal arm contacts with canine in cervical 1/3rd region. to minimize tipping.
- The distal arm of 'U' shape is adapted interproximal between 1st & 2nd premolar.
- The loop should extend 2-3 mm below cervical margin. (0.5 mm away from gingival seat).
- Both the arms of 'U' shaped should be Parallel & in between 1st & 2nd Premolar.
- The horizontal arm adapts along mesial surface of canine so as to help retraction.

- Advantages.

i. easy to construct.
ii. No special plier required.
iii. Require less time for fabrication.

- Disadvantage.

since tag arm is distal to premolar there is greater chance of anchorage loss. since this is shorter & has to adjust more frequently.

- Uses :

Retraction of canine to short distal distance when canine is well defined in the arch.



Self Supported Canine Retractor

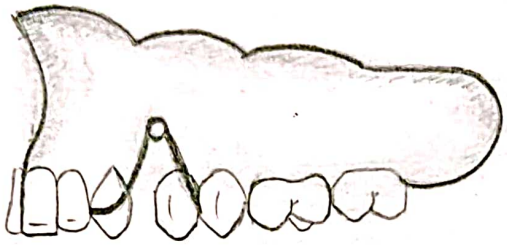

Buccal / Self Supported / Hockey Stick type Canine Retractor.

- Aim : To prepare Buccal / Self Supported / Hockey Stick type Canine retractor.
- It is a buccally placed, Pull type Canine retractor.
- It is made of 22 gauge wire.

- Procedure :
- The diameter of coil is about 4 times the diameter of wire.
- The active arm of retractors is always above the coil.
- The coil is placed away from the buccal surface so it lies half the distance between cervical corner of tooth & deep in vestibule.
- Active arm is hooted around cervical margin of canine.
- Distal arm is given bend & is adapted interproximally to palatal surface in manner similar to arm / tag.

- Indications.

i. To retract labially placed canine.

ii. They bring about distal & palatal movement of canine.

- Advantages.

Due to pressure coil, the length of wire is decreased. Hence increases elasticity and reduces

stiffness . The tag arm is mesial to 2nd premolar. Hence anchorage loss is controlled.

- Disadvantage.

i. The coil may be uncomfortable to patient.

ii. If coil is too high enough , in this case active arm may become short may have limited range of adjustment.

iii. Self correcting canine retractors are stiff. & should be adjusted by only small amount. (0.75 - 1 mm per month).

Palatal Canine Retractor

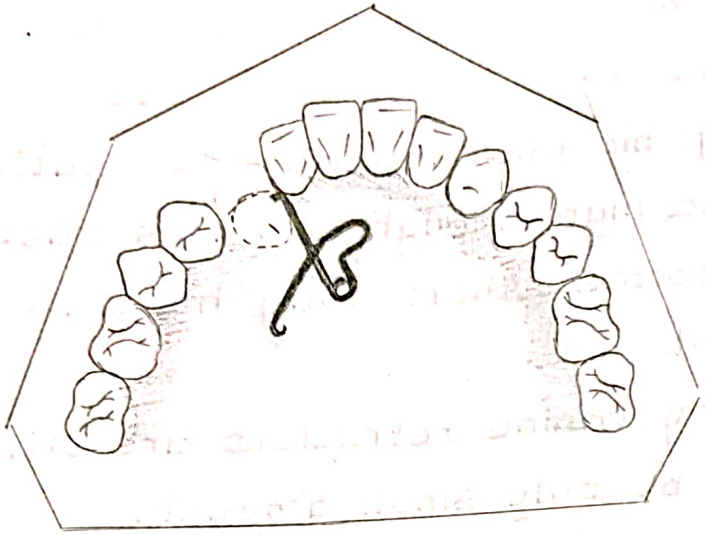

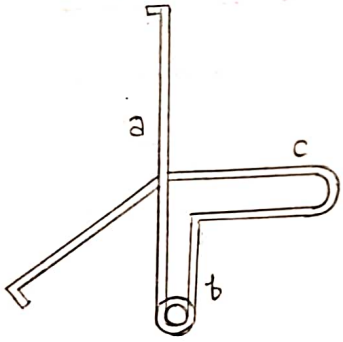

a Distal arm

b. Helix

c. Mesial arm.

Palatal Canine Retractor.

- It is made up of 0.6 mm stainless steel wire.
- It consist of a coil of 3 mm diameter, an active arm and a grade arm.
- The active arm is placed along the long axis of tooth i.e the canine.
- It is activated by opening the helix 2 mm at a time.

- Indications

1. In retraction of canine that are palatally placed.

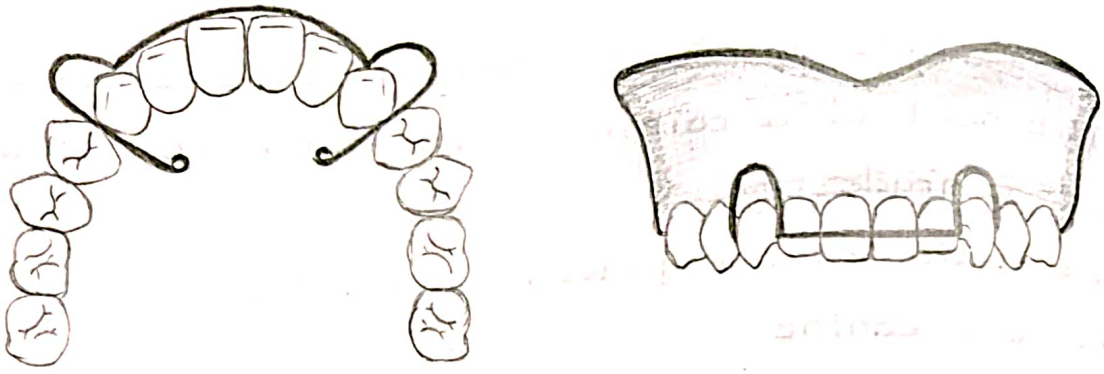

Short Labial Bow

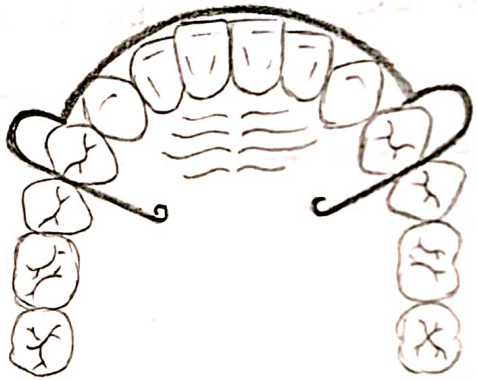

Long Labial Bow

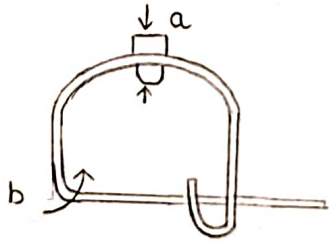

Adjustment of reverse loop labial bow

Labial Bow.

- Aim : To make a labial bow from 21 gauge wire on a ideal cast.
- The labial bow is an evenly curved & symmetrical arch. which contracts labial surface of teeth.
- Each labial bow carrier has usually two symmetrical U loops for activation & adjustment of bow.

- Classification of labial bow.

I. Regular labial bow is from canine to canine.
II. Short labial bow is from lateral incisor to contralateral lateral incisor.
III. Long labial bow is from 1st Premolar to contra. 1st premolar. OR second premolar to 2nd premolar.

- It is usually made of 21 gauge wire. Horizontal arm of bow is adapted to labial surface of incisor at function of incisal & middle 3rd in case of regular labial bow. The 90° bend is given at junction of mesial 1/3 rd & incisal 1/3 rd of canine.
- The U loop is then completed in such a way that distal arm of loop lies in embrassure between canine & 1st premolar.
- Both arms of U loop should be parallel to each other. Lower portion of U should extend 2-3 mm below cervical margin of tooth.

- Uses :

I. To exert retractive pressure on anterior teeth.
II. To limit the labial movement of incisor.
III. To carry the auxillary
IV. To bring about mild rotation & contraction. along with the help of Z spring.
V. Retention.

- Disadvantages :

1. Controll of individual tooth movement is deficient.

- Activation & Adjustment of labial bow.

This is done by compressing 'U' loops at the ends & trimming of acrylic on palatal aspect of each component.

- Modification.

I. Robert Retractor.
II. Split labial Bow.
III. Fitted labial Bow.
IV. High labial Bow. apron spring.
V. Labial Bow with reverse loop.

Robert's Retractor

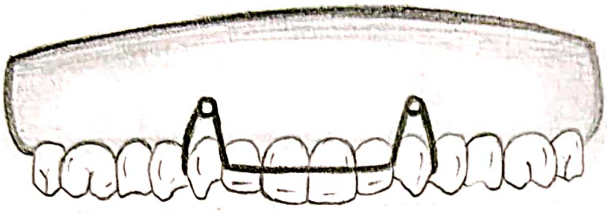

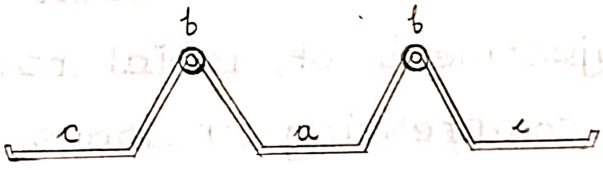

a : Horizontal arm

b : Helix

c : Retentive arm

1. Robert's Appliance.

- Indications :

1. It is used when teeth are rarely proclined & they dont have good underlying support esp. in adults.

- In this way it is achieved by decreasing the diameter of wire and un-increasing the effective length.
- We use 23 gauge wire.
- Instead of 'U' loop are prepared, Use 23 gauge on the other end of each loop then extended. and enters the sleeves of rubber to bring these sleeves. then prevents distortion of rubber.

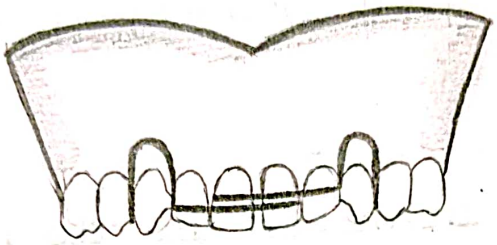

Split Labial Bow
for Retraction

2. Split Labial Bow

- Indication :

1. Assymetrical retraction is possible by activating on 'V' loop more than the other.

eg. i. Cases of unilateral cleft lip or palate.

ii. Modified form of split in anterior labial bow can be used for closure of midline diastema.

The labial bow has split in anterior region resulting into seperation of buccal arms having a 'V' each segment acts as a continious spring.

- Disadvantages.

Because of thinner gauge of wire it is more likely to distort.

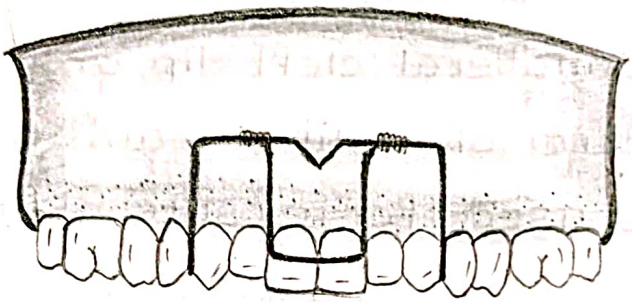

High labial bow with apron spring

3. High Labial Bow with / without Flapper Springs
It has 2 parts.

① Strand / Seat ford which is prepared by 1 mm HRSS wire.

② Active component in happer spring on approns which is prepared from 0.4 - 0.5 mm wire.

- The approns spring can be designed for restoration of the one ore more teeth.
- This is given in cases of excessive proclination. as conventional labial bow is not used because of its tendency to slip cervically.
- Very commonly light focus are generated in labial bow
- It is commonly used in adults with poor bone support.

- Disadvantages.

I. Difficult to fabricate.

II. Risk of soft tissue damage.

4. Fitted labial Bow.

- This is normally a retentive labial bow.
- It is fabricated using 21 gauge HRSS wire.
- The wire is fabricated and adapted to confine labial bow to labial surface of each other and 'U' loop is usually small.

- Indications.

Fitted distal labial bow have position and they are preffered in rotation being corrected inactive treatment.

Mill's Labial Bow

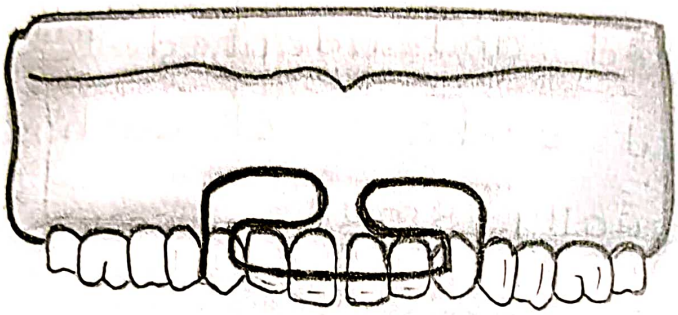

Mill's Labial Bow

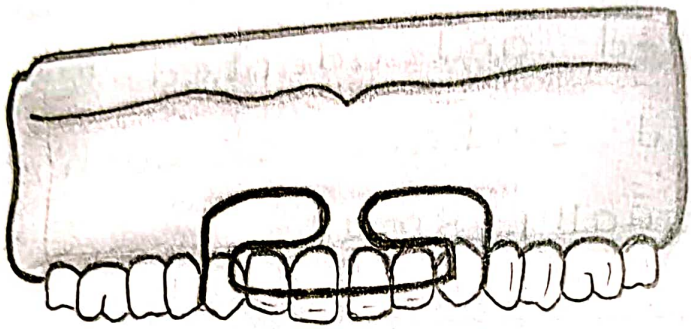

5. Mill's Labial Bow.

- This made from 0.5 - 0.6 mm HRSS wire.
- This type of labial bow is required on single tooth or on group of teeth.

eg. When one or more teeth in an arch are more proclined to each other.

The labial bow has extensive looping wire so as to increase length Flexibility range of action.

- Disadvantage.
- Difficulty in fabrication.
- Poor patient acceptance.
- Complex design.

Reverse labial Bow

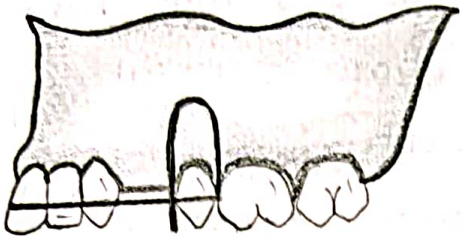



Reverse labial bow is activated by opening the loop This results in lowering of bow more incisally

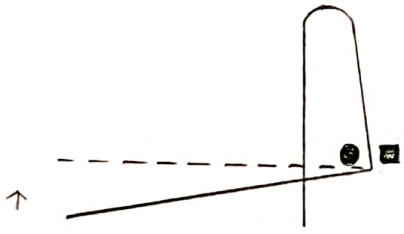

Compensatory bend made to maintain proper level of bow

6. Reverse Labial Bow

- In this type, tag arm is attatched to mesial to canine i.e mesial to U-loop. This 13 to 23 labial bow.
- The distally placed U loop to canine free end of U loop is adapted occlusally between the lateral incisor & central incisor.
- As the large span of wire is incorporated, the flexibility is increased.

7. Labial Bow Soldered to Adams Clasp.

This is used when retention palate is to be given in patient with 1st or 2nd premolar extraction

8. Elastics used as labial Bow.

- Instead of an orthodontic wire an elastic can be used for retraction of an anterior teeth.
- labial bow with hooks on either side is fabricated with hooks going distally towards canine.
- The elastic structures between hooks should be on labial surface of incisors, the patient can change elastic regularly.
- The no. of patients visits to orthodontist are reduced because of that.

- Disadvantage.

1. One has to rely on patient to change elastics where patient co-operation is important.
2. The elastic can slip gingivally & can cause gingival trauma.

Coffin Spring

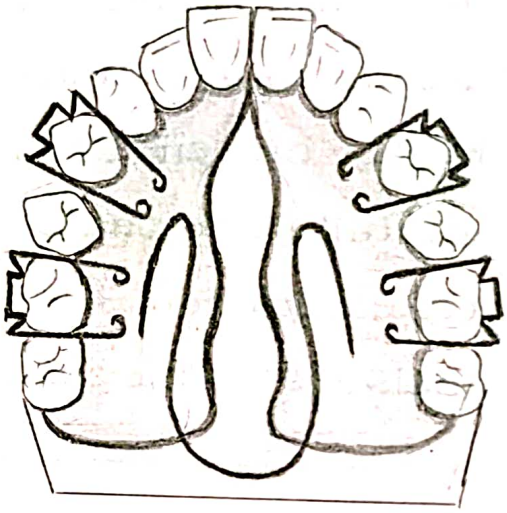

Fabrication of Coffin Spring.

- Waller H coffin introduced this spring in 1881, for lateral expansion of arch.
- A heavy 19 gauge wire is used.

- Indications.

When a different degree of expansion is used or required at anterior & posterior segment of arch, coffin spring is a better option.

- There are 2 types of coffin spring.
  1. Pear Shaped.
  11. Diamond shaped.

- Construction.
- This extends from mesial surface of 1st Premolar to distal surface of 1st molar.
- A big & smooth loop is formed onto wire center for fabrication of pear shaped coffin spring.
- In case of diamond shaped, bends are given on wire in such a way that Anterior, posterior diameter is 2/3 rd, 1/3 rd.
- The spring is kept at uniform distance of 1 mm from palatal form & controlled.

- Advantages :

1. Simple to construct.
11. Less bulky

iii. more economical.

- different degree of expansion is possible in anterior & posterior segment.
- The modified form of coffin spring is used on mayofunctional appliances.
eg. Bayonates Palate, Free activation.

- Disadvantages
- No pressure controll for expansion as activation is arbitrary.
- Force decay is used rapid & frequent adjustments are required.
- It may enterfere with tonight tongue movement & speech.

- Activation.
For anterior arch expansion, It is activated, posteriorly at the base of pear shaped / diamond shape in midline for posterior arch expansion. with plier. The optimal activation should be 4 mm.

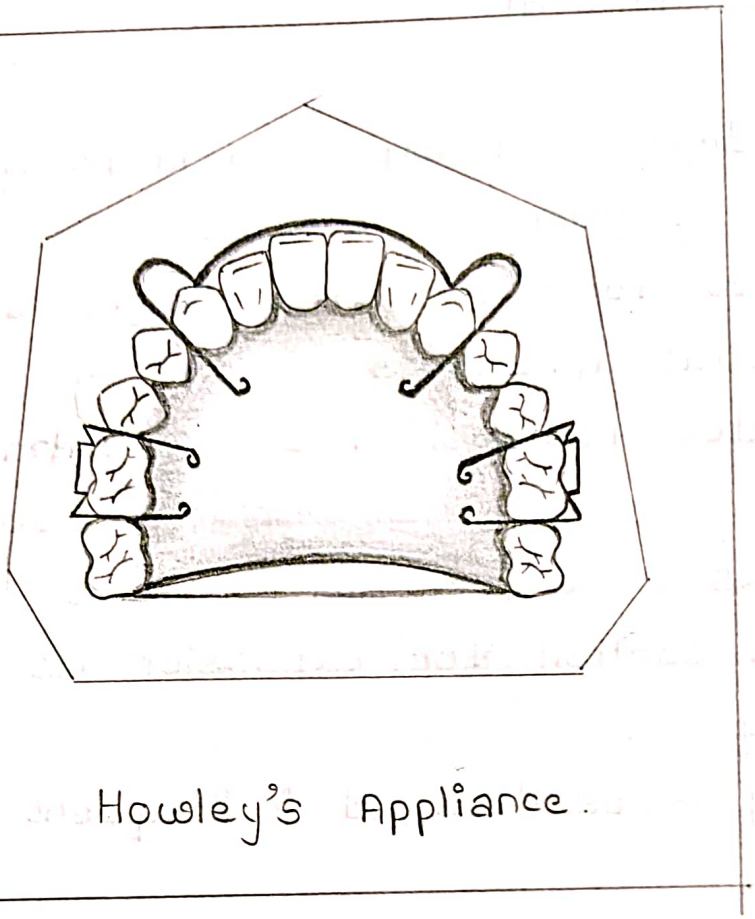

Howley's Appliance.

Hawley's Appliance.

- It was designed in 1920 by charles Hawley
- It is more frequently used retainer.

- The classical Hawley's appliance consists of clasp on molar & short labial bow extending from canine to canine having adjustment hoops.
- This simple design can be modified in several ways to exit suit specific requirements.
- This labial bow can be made to extend from one first premolar to opposite first premolar. This design helps in closing spaces distal to canine.
- Anterior modification is to solder the bow to the bridge of Adam's clasp. This design avoids the risk of space opening between canine & premolar due to cross over wire.
- Fitted labial bow can also be used to offer excellent retention.
- Anterior kite planes can be incorporated to correct deep bite cases.

- Advantage.

I. Ease of fabrication.
II. Simple design.
III. Minimal patient discomfort due to reduced bulk.
IV. So, acceptable to most patients.

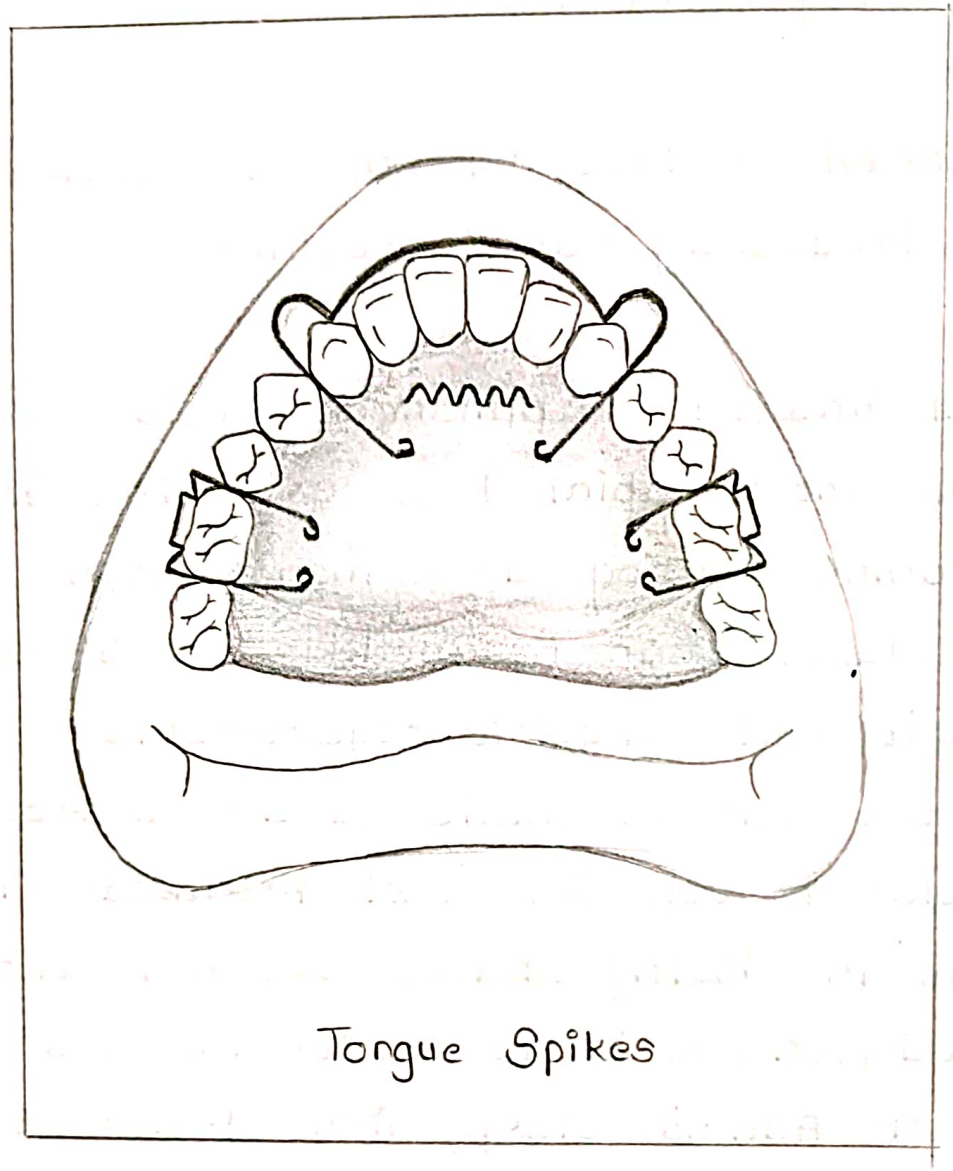

Tongue Spikes

Fabrication of Tongue Spikes.

- Aim : To construct Tongue spikes with 32 gauge HRSS wire.

- Appliances : Fabricated to correct the habit of thumb sucking. However appliance with tongue spikes should not be given to children below 5 years of age.

- Construction :

I. A piece of wire is 1st straightened at a distance (1 & ½ inches) end of wire.

II. First spike is normally maintained at about 2 mm more than cervico - occlusal height of central cervical incisor of patients model.

III. The height of spike may be between 10-12 mm on standard cast and 4 spikes are prepared.

IV. The location of spike should be line joining canine & 1st premolar on both sides.

V. The first spike should be computed by giving a sharp downward bend

VI. The distance between two arms of spikes should be 1mm & the distance between 2 adjacent spikes are 2 mm.

VII. The base of spikes should be at the same level so that they remain were in acrylic

- Advantages
- They are easy to fabricate.
- They are very effective in correcting tongue thursting habit.

- Disadvantage.
- Being a part of removable appliance.
- Patient co-operation is essential for success
- It may not be effective in correcting tongue thursting due to macroglossia.
- It will also not correct complex tongue thrusting with skeletal open bite unless skeletal problem is corrected.

- Mode of Action.

It serves as a constant reminding to patient & also act as mechanical barrier to prevent tongue thursting.



Model Analysis - 1

- Case No. : Jyoti Pawar.
- Analysis of Model Seperately.

I. Individual Tooth Analysis.

10	11	6	7	8	7.8	9	9	7	8	7	6	11	10
7	6	5	4	3	2	1	1	2	3	4	5	6	7
7	6	5	4	3	2	1	1	2	3	4	5	6	7
10	11.5	6	7	7	6.5	6	6	6.5	7	7	6.5	12	11

II. Analysis of whole arch.

Particulars	Maxillary	Mandibular
Total Tooth material (1M to 1M)	96.8 mm	89 mm
Sum of Incisors	32.8 mm	25 mm
Arch Symmetry	Symmetrical	Symmetrical
Arch Shape	U Shape	V
Mid line	Accurate	Accurate
Curve of spee	–	2 mm
Palatal depth	19 mm	–
Crowding	–	–
Spacing.		7 mm

Analysis of models in occlusion.

Model Particulars	Right	Left
Angle's Molar Relation	Class I	Class I
Canine Relation	Class I	Class II
Incisor Relation	Class I	Class I
Proclination	(5-2) = 3	(4-2) = 2
Overjet	5	4
overbite	2	2
Midline	accurate	accurate
Crossbite	–	–

Diagnosis

Angle's Class I Malocclusion with proclined upper & lower incisors and spacing in both arches.

III. Indices.

A. Pont's Index.

Arch width in premolar region. = $\frac{32 \times 100}{80}$ = 40

Arch width in molar region. = $\frac{32 \times 100}{64}$ = 50

Region	Actual	Calculated	Difference
Premolar	38	40	2
Molar	49	50	1

. Inference : As measured value is less than calculated expansion is needed.

B. Ashley Howe's Index.

PMBAW % Formula : $\frac{42}{96} \times 100 = 43.75$

Inference : Borderline Case.

b. PMBAW < PMD.

43.75 < 45 Expansion Not Possible.

2. For Mandibular Arch.

A. Nance & Carey's Index.

Linear Dimension	Brass wire	Calculated	Difference.
66.5		65	1.5

Inference : Non - Extraction case.

3. Inter Arch Analysis : Boltons

Anterior Ratio = $\frac{\text{Man 6T}}{\text{Max 6T}} \times 100 = \frac{39 \times 100}{48.5} = 80.41$

Overa Anterior ratio $\geq$ 77.2

$\therefore$ Corrected Anterior ratio = $\frac{77.2 \times 48.5}{100} = 37.44.$

Overall ratio = $\frac{\text{Man 12T}}{\text{Max 12T}} \times 100 = \frac{91.3 \times 96}{100} = 92.7$

Overall ratio > 91.3

$\therefore$ Corrected Overall ratio = $\frac{91.3 \times 96}{100} = 89.64$

Inference

Overall Mandibular excess = 89 - 87.64 = 1.64.

Anterior Mandibular excess = 39 - 37.44 = 1.56

- Analysis of Space.

Maxillary Arch.

- Space Required.

Sr. No	Condition to Correct	Amount (mm)
1	Proclination = 3 x 2	6
2.	Crowding	-
3	Anterior Rotation	-
4.	Impacted	6
5	other.	-
	Total	12

- Space Available.

Sr. No	Particulars	Amount (mm)
1	Existing interdental Space	3+1+2+2 = 7
2	Expansion	
3	correction of retroclined teeth.	
4	Extraction	9
5	Distalization	
6.	extraction of supernumerary teeth	
7.	Interproximal stripping.	
	Total	16
	16 - 12 = 4 Available	

b. Mandibular Arch.

- Space Required.

Sr.No	Condition to Correct	Amount.
1	Proclination	2
2	Crowding	–
3	Impacted	–
4	Curve of spee	2
5	other	–
	Total	4

- Space Available

Sr.No	Particulars	Amount.
1	Existing interdental space	6
2	correction of Retroclined teeth	
3	extraction	
4	Distalization	
5	extraction of supernumerary	
6	other / IPR.	
7	Total	6
8	6 – 4 = 2 mm · Available.	

Treatment Plan.

1. Pre-orthodontic phase.
   - Scaling & polishing
   - Fillings

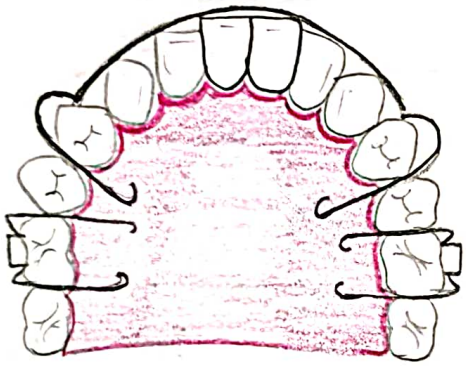

Labial bow

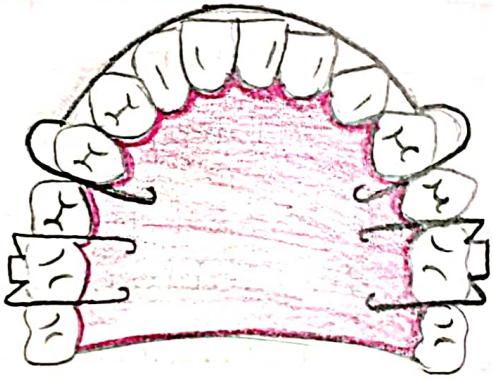

Hawley's appliance

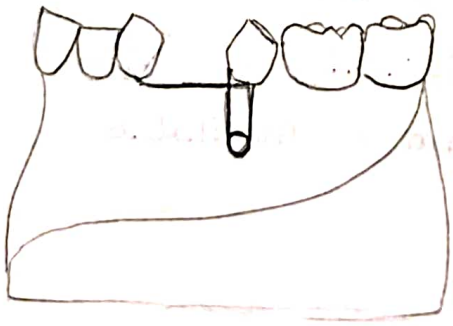

Helical canine Retractor

2. Orthodontic Phase

Phase		Appliance
I	Expansion / IPR	Jack screw Quad Helix.
II	Levelling & Alignment	Labial bow Adam's 'Z' Spring.
III	Canine retraction	Helical canine retractor.
IV	Incisior retraction	Labial bow Adams clasp.
V	Finishing & Detailing	Labial bow Adam's clasp.

3. Post orthodontic phase
   - Scaling & polishing.
   - Desensitizing toothpaste
   - Oral hygiene instruction.
   - Follow ups.

4. Retention appliance
   Hawley's Appliance.

Model Analysis - 2.

- Case No.
- Analysis of models seperately.

1] Individual Tooth Analysis.

10	10	7	7	8	8	10	10	8	8	7	7	10	10
7	6	5	4	3	2	1	1	2	3	4	5	6	7
7	6	5	4	3	2	1	1	2	3	4	5	6	7
10	10	7	7	7	7	6	6	7	7	7	8	10	10

2] Analysis of whole arch.

Particulars	Maxillary.	Mandibular
Total Tooth material	100	89
Sum of incisors	36	26
Arch Symmetry	Symmetrical	⊤⊢
Arch Shape	U	U
Midline	accurate	⊤⊢
curve of spee	–	3mm
palatal depth.	24 mm	–
crowding	5 mm	3 mm
spacing	–	–

- Analysis of models in occlusion.

Particulars	Maxillary	Mandibular
Angle's molar Relation	class I	class II
Canine Relation	class I	cross bite
Incisor Relation	class II	class II
Proclination	Max = 3	Mand = 0
Overjet	2	2
overbite	2	3
Midline	accurate	⊣⊢
Cross bite	–	–

- Diagnosis :

Angle's class I malocclusion on right & class II on left side, crowding in both arches & proclination in maxillary arch.

3. Indices.

- For Maxillary Arch.

A] Pont's Index.

1. Arch width in Premolar (4/4) = $\frac{36 \times 100}{80}$ = 45
2. Arch width in molar (6/6) = $\frac{36 \times 100}{64}$ = 56

Region	Actual	Calculated	difference
Premolar	34	45	11
Molar	46	56	10

Expansion is Needed.

b. Ashley Howe's Index.

PMBAW % Formula = $\frac{41}{90} \times 100 = 45.5$

Inference = Non-extraction case.

PMBAW (41) > PMD (40) = Expansion is possible.

- for mandibular Arch.

A] Nance & Carey's Index.

LD.	calculated	difference
69	66	3

Inference : Non extraction.

B. Bolton's Analysis.

Anterior ratio = $\frac{\text{Man 6T} \times 100}{\text{Max 6T}} = \frac{40 \times 100}{52} = 76.9$

A.R < 77.2

∴ Corrected A.R = $\frac{77.2 \times 52}{100} = 35.51$

Overall ratio = $\frac{89 \times 100}{100} = 89$.

∴ O.R < 91.3

∴ Corrected O.R = $\frac{91.3 \times 100}{100} = 91.3$

- Inference

Overall Maxi excess = 0

Overall Anterior maxi excess = 7.75

• Analysis of Space.

A. Maxillary Arch.

No.	condition to correct	Amount.
1	Proclination	2
2	Crowding	5
	Total	7

B. ii) Space Available. = 0 mm.

Space Required = 0-7 = 7 mm.

B. Mandibular Arch.

• Space required.

Sr.No.	Condition to correct	Amount.
1	Crowding	3
2	curve of Spee	3
		6

• Space Available

No.	Particulars	Amount.
1.	other.	0

Space Required = 6-0 = 6 mm.

• Treatment Plan.

1] Pha - Orthodontic Phase

- Scaling polishing
- Fillings.

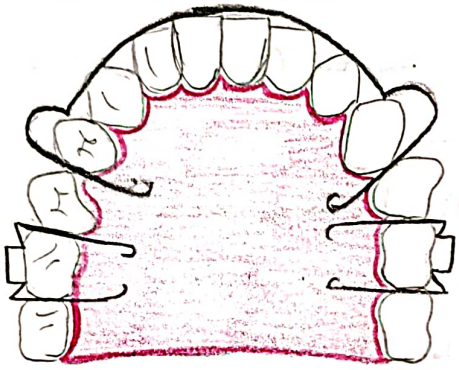

labial bow

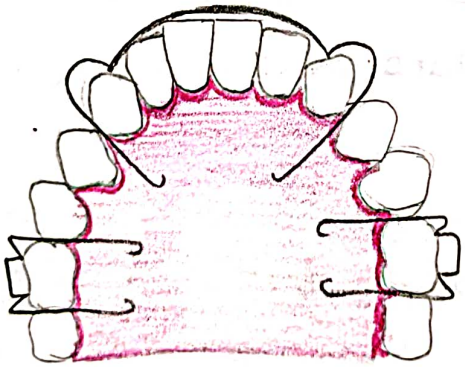

Hawley's appliance

2. Orthodontic phase.

phase		Appliance
I	IPR	
II	Leveling & Alignment	Labial bow
III	Finishing & Detailing	Labial bow

3. Post Orthodontic phase
   - Scaling polishing
   - Desensitizing toothpaste
   - Oral hygiene instruction
   - Follow up.



Model Analysis · 3

- Case No.
-
- Individual Tooth Analysis.

11	10	7	7	8	7	9	8	7	8	7	7	10	10
7	6	5	4	3	2	1	1	2	3	4	5	6	7
7	6	5	4	3	2	1	1	2	3	4	5	6	7
11	11	7	7	6	6	6	6	6	7	8	7	11	11

- Analysis of whole arch.

Particulars	Maxillary	Mandibular
Total tooth material	96	87
Sum of incisors	32	29
Arch Symmetry	Symmetrical	⊣⊢
Arch Shape	U shape	V shape
midline	Accurate	⊣⊢
curve of spee	—	2 mm
palatal depth	21 mm	—
Crowding	—	
Spacing.	—	

Analysis of model in occlusion.

Particular	Right	Left.
Angles molar relation	class II	class II.
Canine relation	I	I
Incisor relation	III	III
Proclination	0	0
Overjet	2	2
overbite	openbite	openbite.
midline	accurate	⊤
crossbite	present	Absent.

- Diagnosis

Angle's class II malocclusion with crossbite on right side & open bite in anterior region.

C. Indices.

For maxillary arch.

a. Pont's index.

Arch width in premolar region = $\frac{32 \times 100}{80}$ = 40

Arch width in molar region = $\frac{32 \times 100}{64}$ = 50

Region	Actual	Calculated	difference
Premolar	39	40	1
Molar	46	50	4

Inference : Expansion is needed.

b. Ashley Howe's Index.

$\frac{43}{96} \times 100 = 44.79$

Inference - a. Non extraction case.

PMBAW (43) > PMD (41) - expansion possible.

- For Mandibular Arch.

a. Nance & Carey's index.

LD.	calculated	Difference
66	70	4.

Inference : 2nd premolar (5/5) extraction.

3. Bolton's Analysis.

Anterior Ratio = $\frac{37}{47} \times 100 = 78.7$

AR > 77.2

∴ Corrected = $\frac{77.2 \times 47}{100} = 36.28.$

Overall Ratio = $\frac{87}{96} \times 100 = 90.6$

O.R < 91.3

∴ corrected = $\frac{90.6 \times 87}{100} = 78.8$

Inference : overall Max excess = 87-78.8 = 8

anterior Mand excess = 0.7.

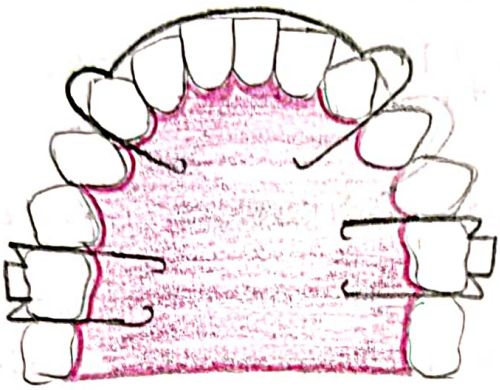

Labial Bow

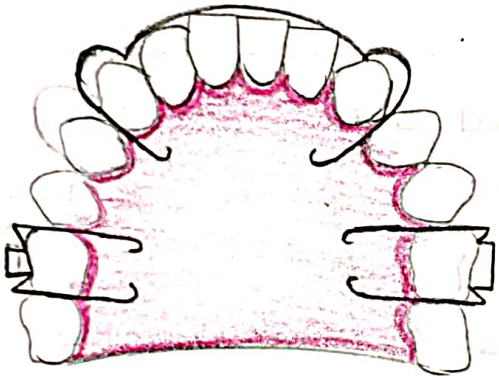

Hawley's Appliance

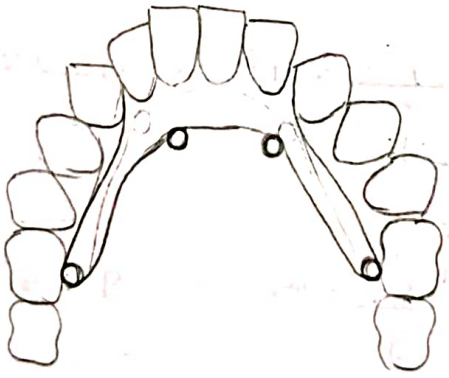

Quad helix

- Analysis of Space

a. Maxillary arch.

- Space required. = 0.
- Space available = 0.

b. Mandibular arch.

- Space required. = 2.
- Space available = 0. = IPR.

- Treatment plan.

1. Pre-orthodontic phase. - Scaling & Polishing
   Filling.
2. Orthodontic Phase

Phase I =	expansion / IPR	Quad helix.
Phase II -	leveling & alignment	Labial bow
		Z-Spring.
phase V =	Finishing & detailing	labial bow.

3. Post orthodontic phase.
   - Scaling & polishing
   - Desensitizing toothpaste
   - oral hygiene instruction
   - Follow up.

Model Analysis - 4.

Model No.

- Individual Tooth Analysis.

11	10	7	8	8	8	10	10	8	8	8	7	10	11
7	6	5	4	3	2	1	1	2	3	4	5	6	7
7	6	5	4	3	2	1	1	2	3	4	5	6	7
12	13	8	8	7	6	6	6	6	7	8	8	13	12

- Analysis of Whole arch.

Particulars	Maxillary	Mandibular
Total tooth material	102	96
Sum of incisors	36	24
Arch Symmetry	Symmetrical	⊤
Arch Shape	U	V
Midline	accurate	⊤
Curve of Spee	—	1 mm
Palatal depth	26 mm	—
Crowding	—	2 mm
Spacing.	5 mm	—

- Analysis of Model in occlusion.

Particulars	Right	Left.
Angle's Molar relation	Class I	class I
canine relation	I	I
Incisor relation	I	I
proclination	(4-2) = 2	(3-2) = 1
overjet	4	3
overbite	4	4
midline	accurate	—
crossbite.	—	—

- Diagnosis.

Angle's class I malocclusion with proclined upper incisors & crowding in mandibular arch and spacing in maxillary arch.

C. Indices.

- Maxillary arch.

a Pont's index.

Arch width in premolar = $\frac{36 \times 100}{80}$ = 45

Arch width in molar = $\frac{36 \times 100}{64}$ = 40.6

Region	Actual	Calculated	difference
Premolar	47	45	
Molar	51	40.6	

- Inference.

Expansion Not needed

b. Ashley Howe's index.

PMBAW % = $\frac{45}{102} \times 100 = 44.1$

inference = Non extraction case.

- for Mandibular arch.

a. Nance & carey's

LD.	calculated	difference.
70	75	5

Inference = 2nd premolar extraction.

8. Bolton's Analysis.

Anterior ratio = $\frac{88}{52} \times 100 = 73.07$.

Since A.R < 77.2.

Corrected AR = $\frac{52 \times 73.07}{100} = 40.14$.

Overall ratio = $\frac{96}{102} \times 100 = 94.11$

Since O.R > 91.3.

Corrected OR = $\frac{102 \times 91.3}{100} = 93.12$.

Inference

1. Overall mand excess = 1 mm.

Anterior max excess = 3 mm.

. Analysis of Space.

a. Maxillary Arch.

Space Required.

No.	Condition to correct	Amount.
1.	Proclination (4-2) x 2	4.
2.	Anterior rotation	3
	Total	7

Space Available.

No.	Particulars	Amount.
1.	Interdental Space	5
	Total	5.
∴	IPR	2 mm.

Space required.

No.	Condition to correct	Amount.
1.	Proclination	1
2	crowding	2
3	curve of spee	2
	Total	5

Space Available. = 0 mm.

∴ IPR = 5 mm

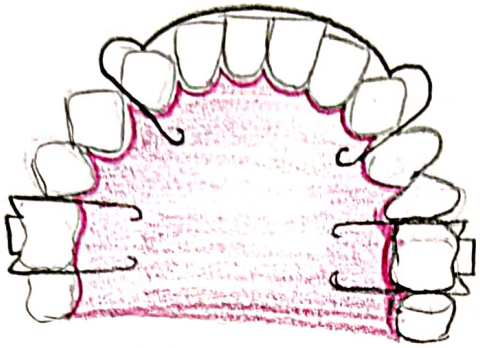

Labial bow

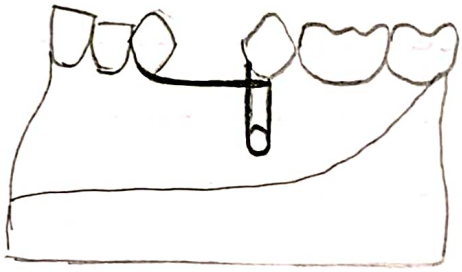

Helical canine Retractor

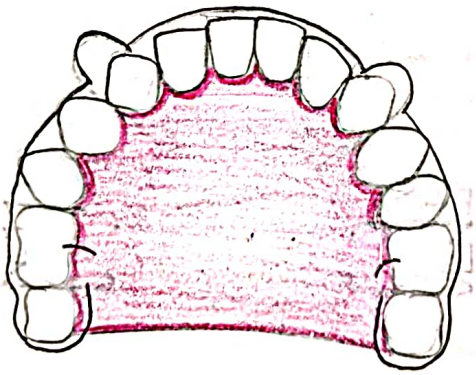

Begg's wrap around retainer

Treatment Plan.

1. Pre-Orthodontic phase.
   - Scaling & polishing
   - Filling.

2. Orthodontic phase.

Phase I - IPR.

Phase II - Leveling & Alignment — labial bow.

III - Canine Retraction — Helical canine retractor.

IV. - Incisor Retraction — labial bow

V. - Finishing & detailing — labial bow.

3. Post orthodontic phase.
   - Scaling & Polishing
   - desensitizing toothpaste.
   - oral hygiene instruction.
   - Follow up.

4. Retention Appliance.
   Begg's Wrap around retainer.



Model Analysis - 5

Case No :

1. Individual Tooth Analysis.

10	10	6	7	9	7	9	9	7		7	7	10	10
7	6	5	4	3	2	1	1	2	3	4	5	6	7
7	6	5	4	3	2	1	1	2	3	4	5	6	7
10	11	7	7	8	6	6	6	6	8	7	7	11	10

2. Analysis of whole arch.

Particulars	Maxillary	Mandibular
Total tooth material.	88	90
Sum of incisors	32	24
Arch of symmetry	Symmetrical	—
Arch of shape	U shape	V
mid line	Inaccurate	accurate
curve of spee	—	4 mm
Palatal depth	20 mm	—

- Analysis of models in occlusion.

Particulars	Right	left.
Angle's molar relation	class II div II	class II div II.
Canine relation	class II	-
Incisor relation	class II	class II.
Proclination	—	—
overjet	0	0
overbite	12	12
midline	inaccurate	-
Cross bite	—	—

• Indices.

a. Pont's index.

Arch width in premolar $\frac{32 \times 100}{80} = 40$

Arch width in molar. $\frac{32 \times 100}{64} = 50$

Region	Actual	Calculated	difference.
Premolar	34	40	6
Molar	49	50	1

Inference : Since actual value is less than calculated expansion is needed.

b. Ashley Howe's Index.

PMBAW % = $\frac{44}{88} \times 100 = 50$.

Inference. - Non-extraction case.

b. PMBAW (50) > PMD (40) = expansion possible.

2. For mandibular

a). Nance & Carey's index.

LD.	Calculated	difference
68	78	10

Inference = 1st molar (4/4) extraction.

8. Bolton's Analysis.

Anterior Ratio = $\frac{40}{41} \times 100 = 97.56$

A.R > 77.2.

Corrected A.R = $\frac{97.2 \times 41}{100} = 31.65$.

Overall Ratio = $\frac{90}{88} \times 100 = 102.27$.

O.R > 91.3.

Corrected O.R = $\frac{88 \times 91.3}{100} = 80.34$.

Inference.

1. Overall mandi excess = 90 - 80.34 = 9.6.
2. Anterior mandi excess = 40 - 31.65 = 8.4.

- Analysis of Space.
- Space Req.

No.	Condition to Correct	Amount.
1	Crowding	1
2	Impacted	9
	Total	10

- Space Available

No	Particular	Amount.
1	Interdental Space	2
2	Correction of retroclined Teeth	6 mm
	Total	8

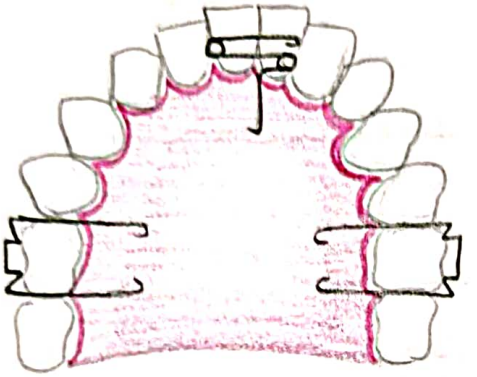

Z spring

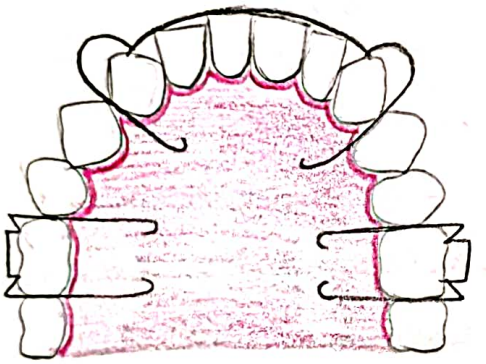

Labial bow

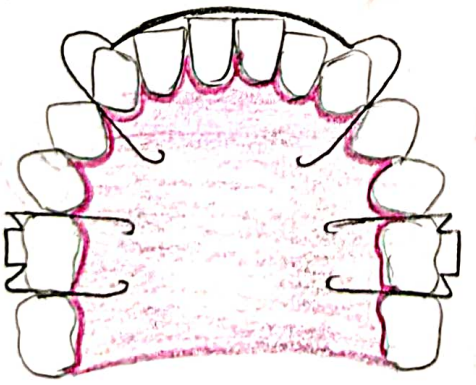

Hawley's appliance

IPR = 2 mm.

b. Mandibular Arch.

Space Required.

No.	Condition to Correct	Amount.
1	Crowding	3
2.	curve of spee	2
	Total	5

Space Available.

No	Particular	Amount.
1.	other	0.

∴ IPR. = 5 mm.

• Treatment Plan.

1. Pre-Orthodontic phase.
   - Scaling & polishing
   - Filling
   - extraction.

2 Orthodontic phase

Phase I - Expansion / IPR

phase II - Leveling & alignment — Z Spring.

phase M - Finishing & detailing. — Labial bow

3 Post Orthodontic phase
   - Scaling & polishing
   - Desensitizing toothpaste

- oral hygiene instruction.
- Follow up.



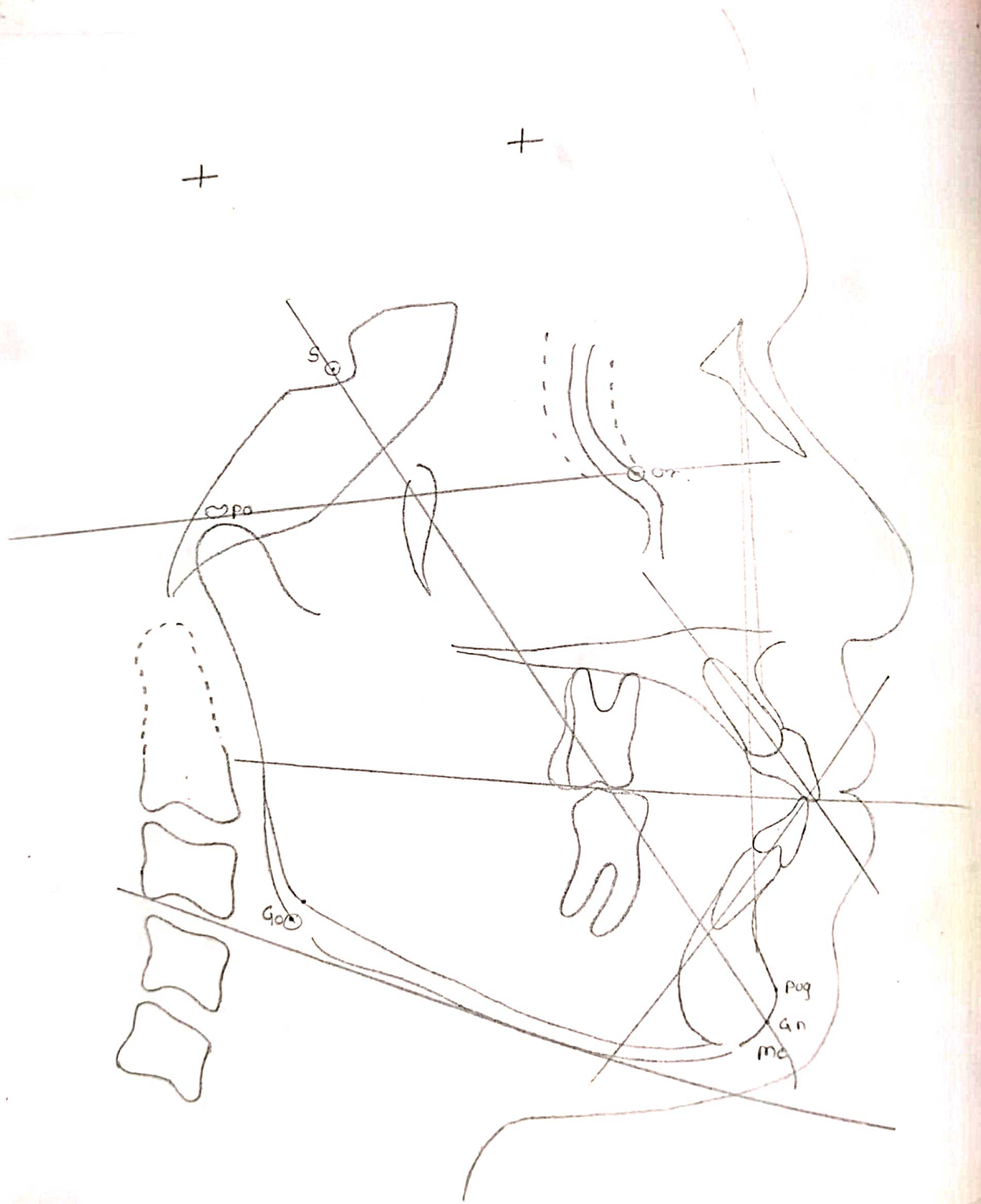
S
Or
Po
Go
Pog
Gn
Me

Cephalometric Tracing.
No. 01

- Patient Name : Tushar Salve

- Down's Analysis.

A] Skeletal.

Variable	Mean Value	Acquired value	Interpretation.
Facial Angle	87.8 (82-95)	90°	Average value
Angle of convexity	0 (8.5-10°)	0°	Average
A-B plane Angle	-4.6 (-9 - 0)	4°	Angles Class III Malocclusion.
Mandibular Plane Angle	21.9 (17-28)	17°	Average Value.
Y axis.	59.4 (53-66)	60°	Average Value.

B] Dental.

Variable	Mean Value	Acquired Value	Interpretation.
Cant of occlusal Plane.	9.3 (1.5-14°)	10°	Average
Lower incisor to occlusal plane	14.5° (3.5-20°)	37°	Lower incisor proclination
Lower incisor to mandibular plane	14° (-8.7 to 7°)	60°	Lower incisor Proclination
Interincisal angle	130-150°	102°	Class II div I malocclusion
Upper incisor to A-pog	2.7 mm (-1 to 5 mm)	7mm	proclined Upper incisor.

1.2



2. Steiner's Analysis

	Variable	Mean	Acquired.	Interpretation.
A.	Skeletal.			
1.	SNA angle	82	88	Prognathic Maxilla class II malocclusion
2.	SNB angle	80	89	Prognathic mandible class III malocclusion.
3.	ANB angle	2°	3°	class II
4.	occlusal plane angle	14.5	7°	Horizontal growth pattern.
5.	Mandibular plane angle	82	15°	Horizontal growth pattern.
B.	Dental.			
1.	Upper incisor-NA	4 mm	5 mm	Proclined upper incisor
2	Upper incisor-NA	22°	32°	Angles class II div I malocclusion
3.	lower incisor-NB	25°	51°	Proclined lower incisor.
4.	lower incisor-NB (At Linear).			
5	Interincisal angle	131°	102°	class II div I malocclusion.

1-3

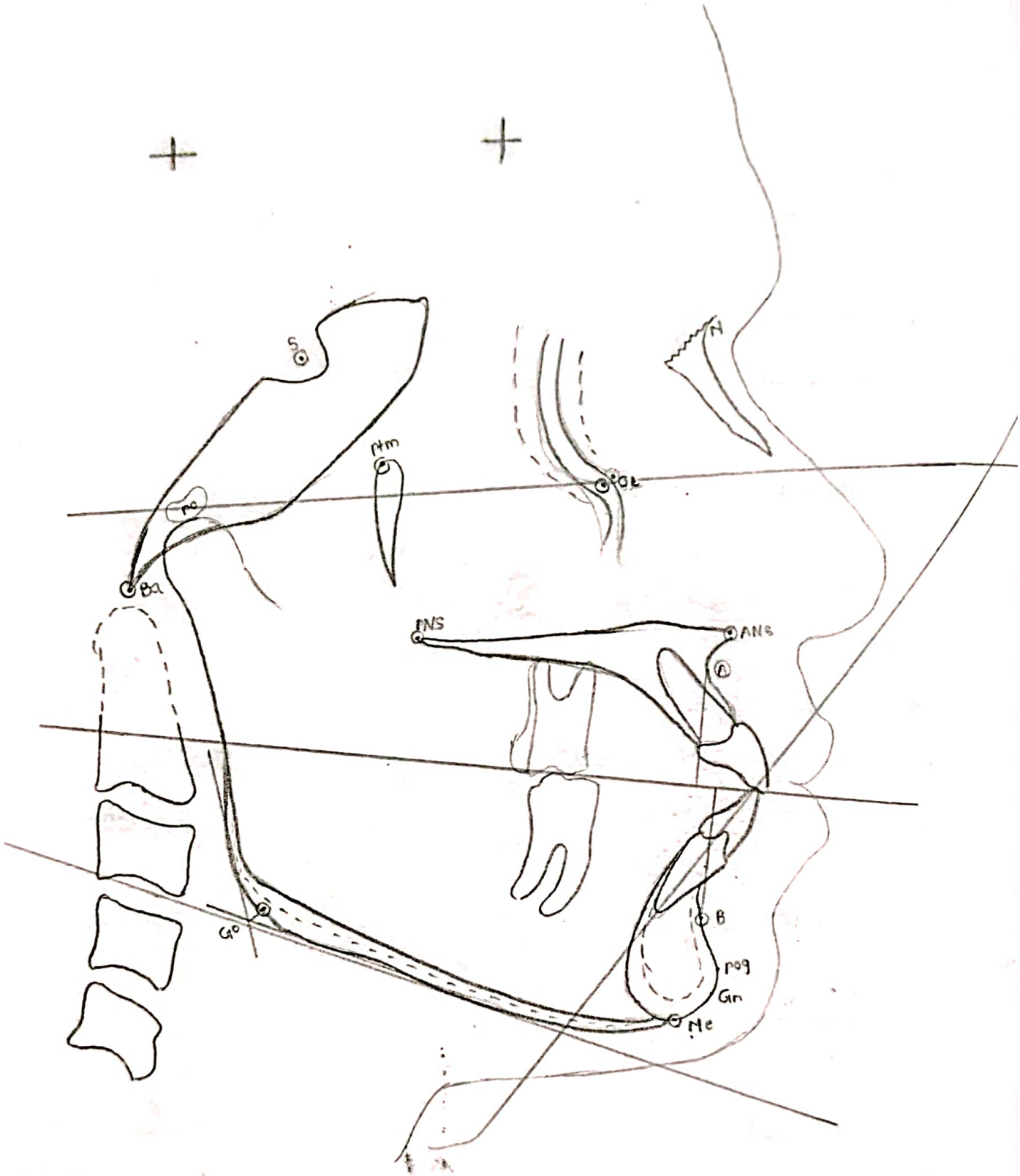

3. Tweeds Analysis

Variable	Mean Value	Acquired Value	Interpretation
Frankfort Mandibular plane angle (FMPA)	25	21	Horizontal Vertical growth pattern.
IMPA	90°	109°	Proclined incisor.
FMIA	65°	50°	Retrognathic mandible.

- Inference.

  Class II Malocclusion.



2.1

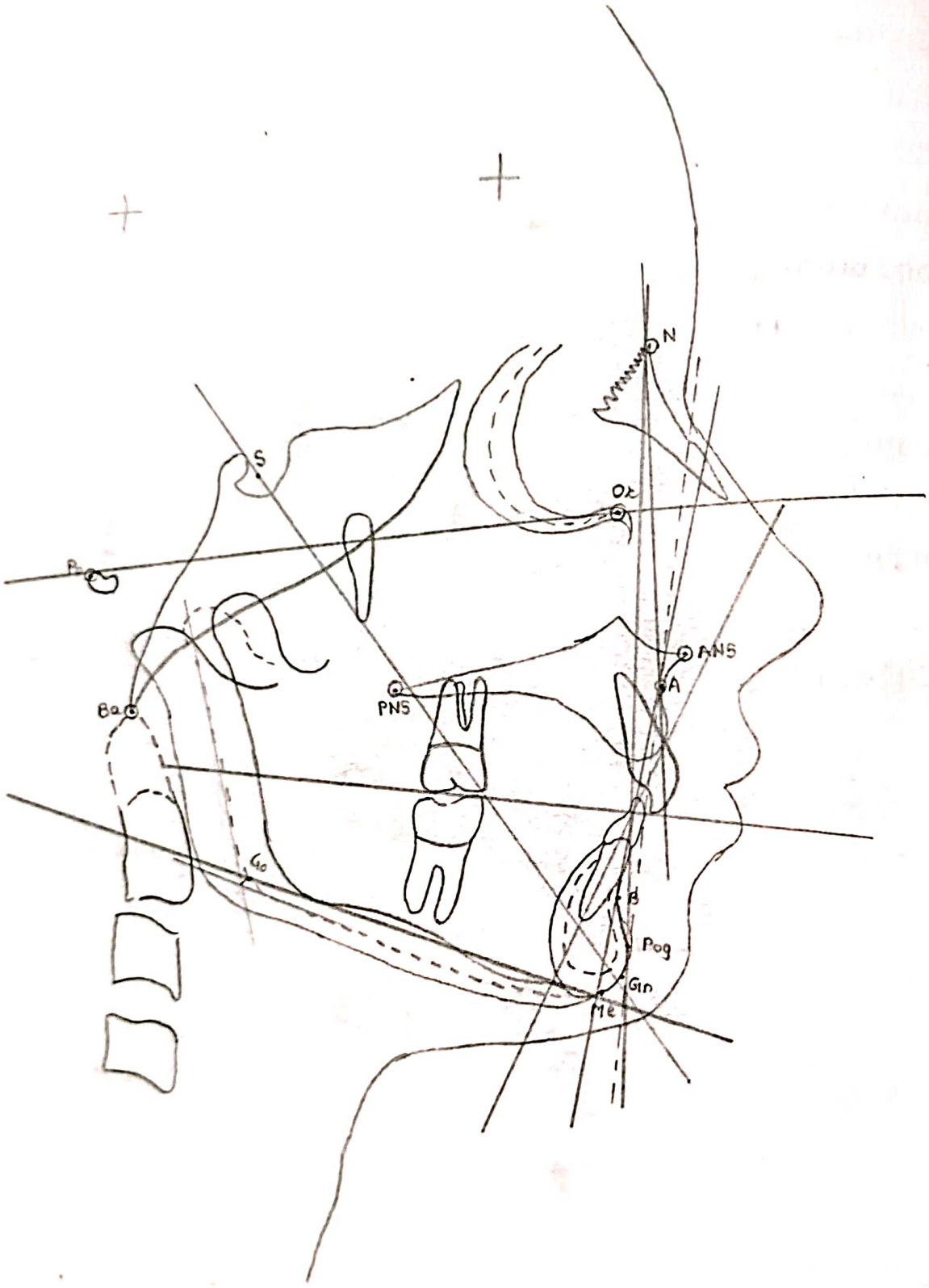

2.1

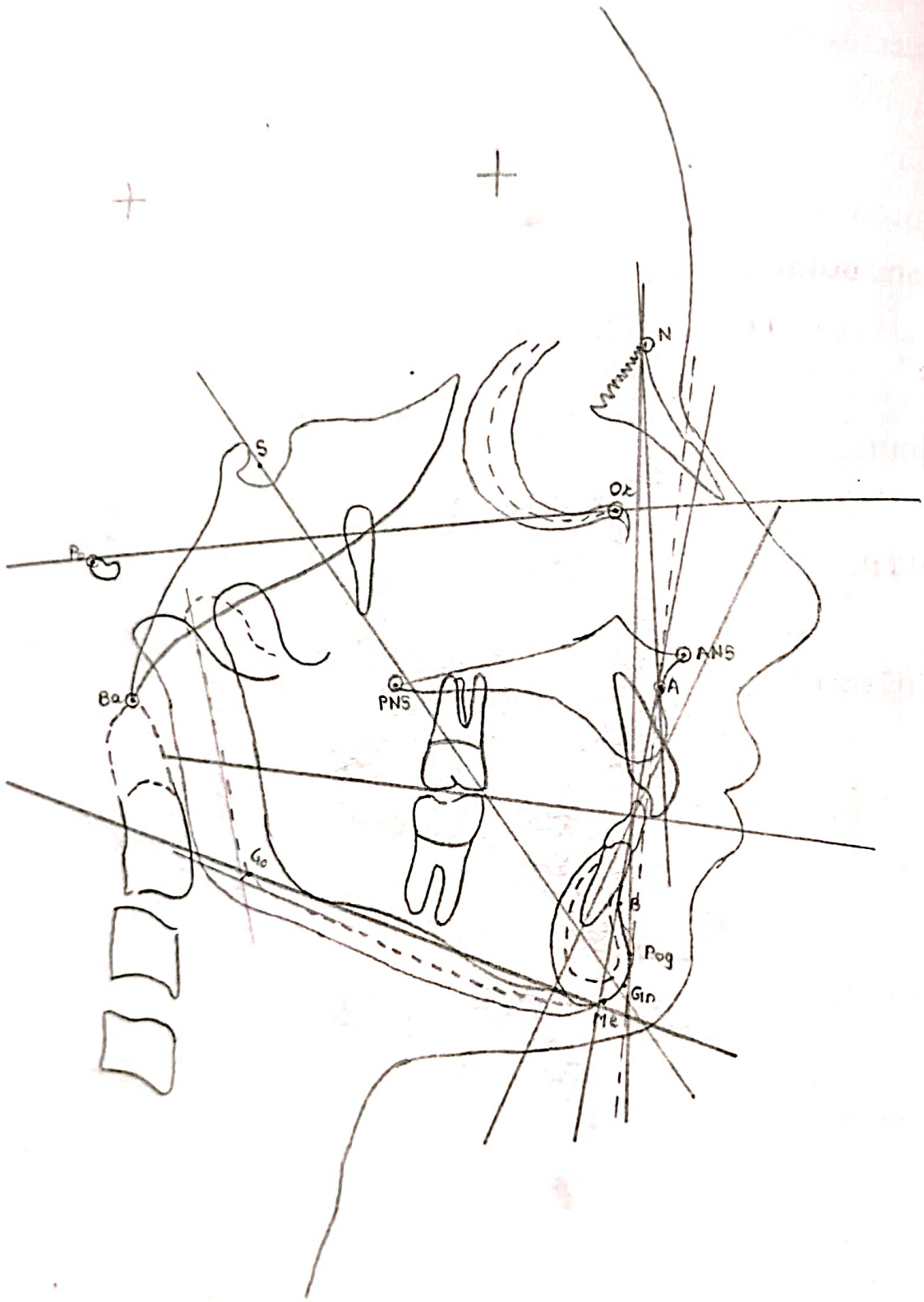

Cephalometric Tracing.
No. 02.

Patient Name - Nitya Tharat

1. Down's Analysis.

variable	Mean Value	Articulated Value	Interpretation.
A] Skeletal.			
1. Facial Angle	87.8	86°	Average Prognathic Maxilla
2. Angle of convexity	6°	10°	Convex profile
3. AB plane angle	-4.6°	-6°	Class II pattern.
4. Mandibular plane angle	21.9°	23°	Average.
5. Y axis	59.4°	58°	Average.
B] Dental.			
1. Cant of occlusal plane	9.3°	11°	Average.
2. Interincisal angle	135.4°	141°	class II div 2
3. Incisor-occlusal plane angle	14.5°	17°	Average.
4. Incisor-Mandibular plane angle	1.4°	5°	incisor tipped forward.
5. U1 to A pog linear	2.7 mm	2 mm	Average.

2·2

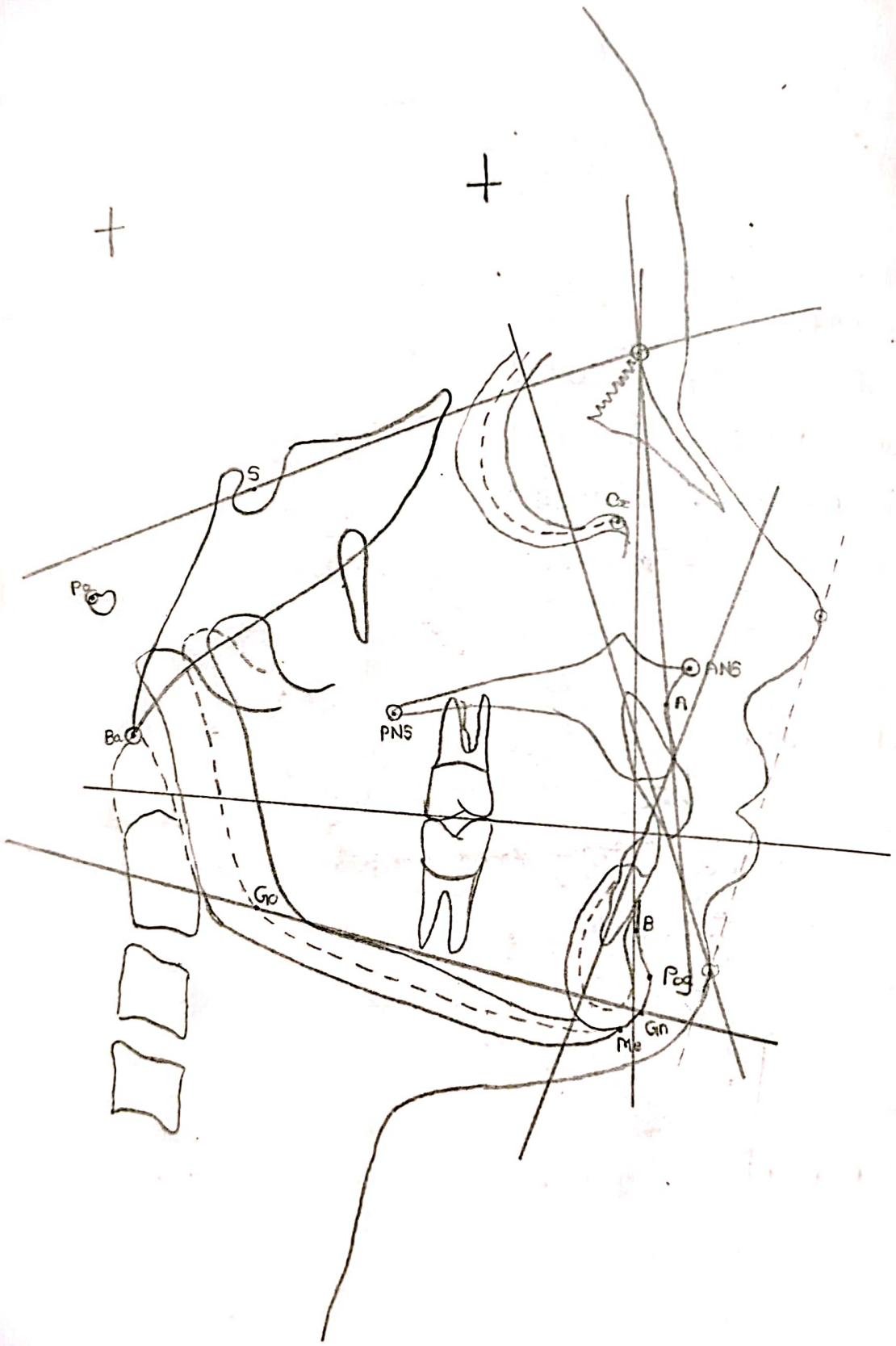

2] Steiner's Analysis.

variable	Mean Value	Articulated Value	Interpretation.
A] Skeletal.			
SNA	82	79°	Prognathic maxilla. Class III tend.
SNB	80	74°	Class II
SND	76	74	Average.
ANB	2°	5°	Class II.
Occlusal plane angle	14.5°	22°	Vertical growth pattern
Mandibular plane angle	32°	23$°	Horizontal growth pattern.
B] Dental			
Ui to NA mm	4 mm	0	Retroclined incisor
Ui to NA angle	22°	12°	Class II div II
Li to NB mm	4 mm	2 mm	Retroclined incisor
Li to NB angle	25°	21°	Class II div II
Li to Ui angle	131°	141°	Retroclination.
Occlusal to SN angle	14°	22°	Class II div II.

2.3

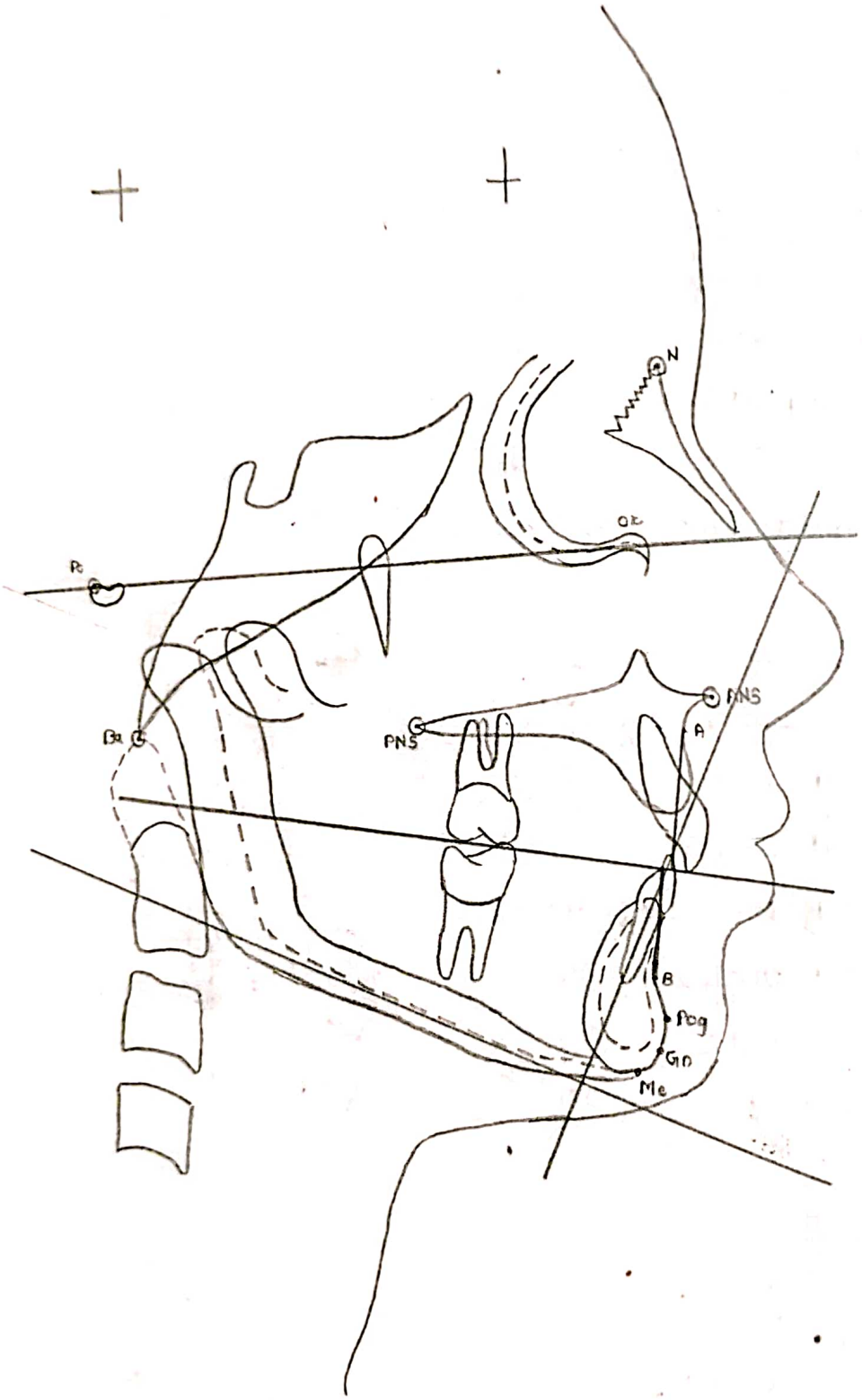

3] Tweed's Analysis.

Variable	Mean Value	Articulated Value	Interpretation
FMPA	25°	24	Horizontal growth.
FMIA	65°	62	Retrognathic mandible
IMPA	90°	94	Retrognathic mandible

4] Witt's Appraisal.

Bo - Ao	±1mm	+1mm.

Inference = Class II div II malocclusion.



3.1

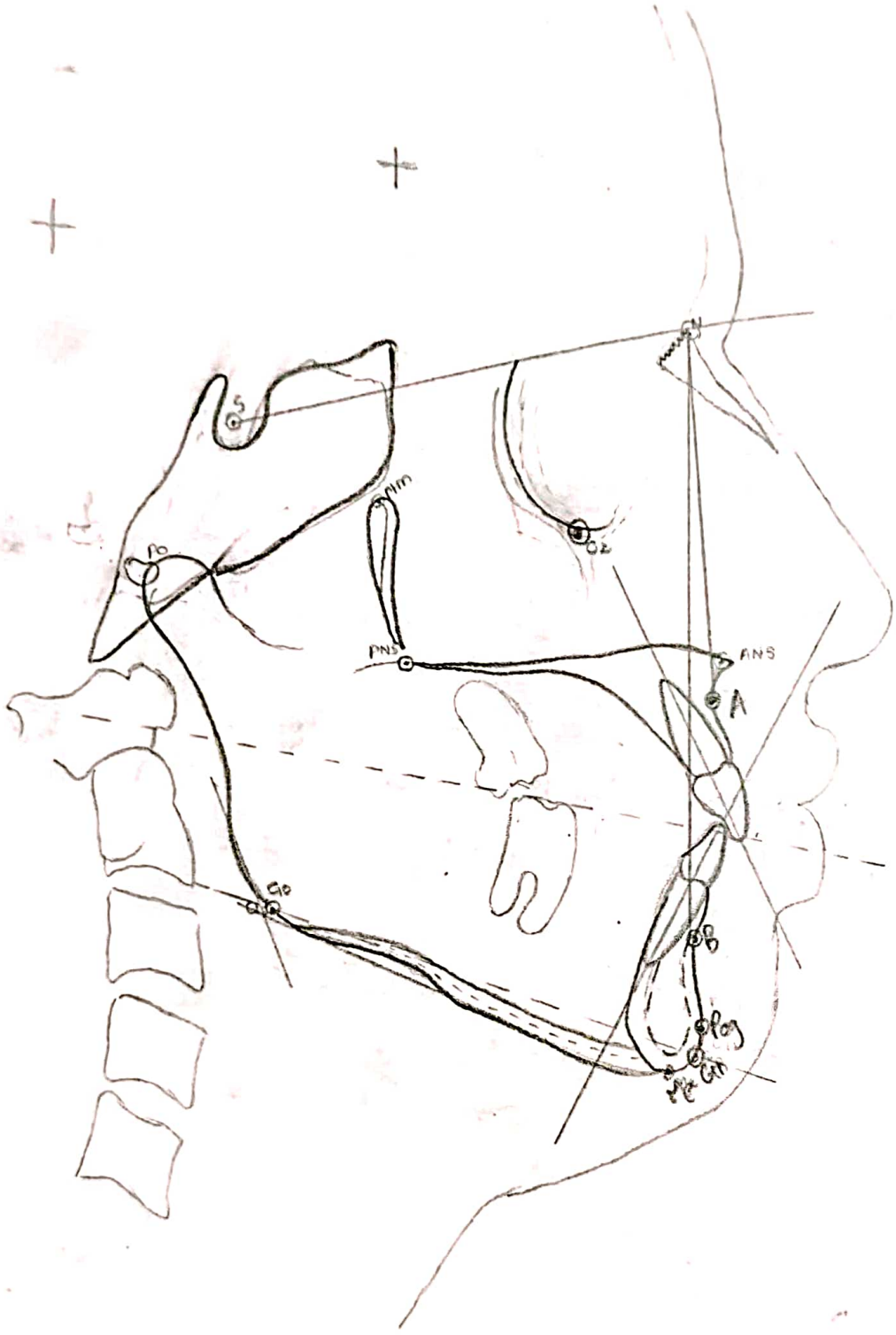

Cephalometric Tracing
NO : 03

Patient Name :

1] Down's Analysis.

Variable	Mean Value	Articulated Value	Interpretation
1. Skeletal			
1. Facial angle	87.8°	92°	class III malocclusion
2. Angle of convexity	0	4°	convex profile.
3. A-B plane angle.	−4.6°	2°	Average
4. Mandibular plane angle.	21.9	20°	Average
5. Yaxis	59.4	59°	Average
2. Dental.			
1. Cant of occlusal plane	9.3°	7°	Average.
2. lower incisor to occlusal plane.	14.5°	99°	Forward inclination of incisors.
3. lower incisor to mandibular plane.	14°	107°	Average.
4. Interincisal angle	130-150°	103°	class I bimax class II div I
5 Upper incisor to A-pog.	2.7 mm	9 mm	Average.

3.2

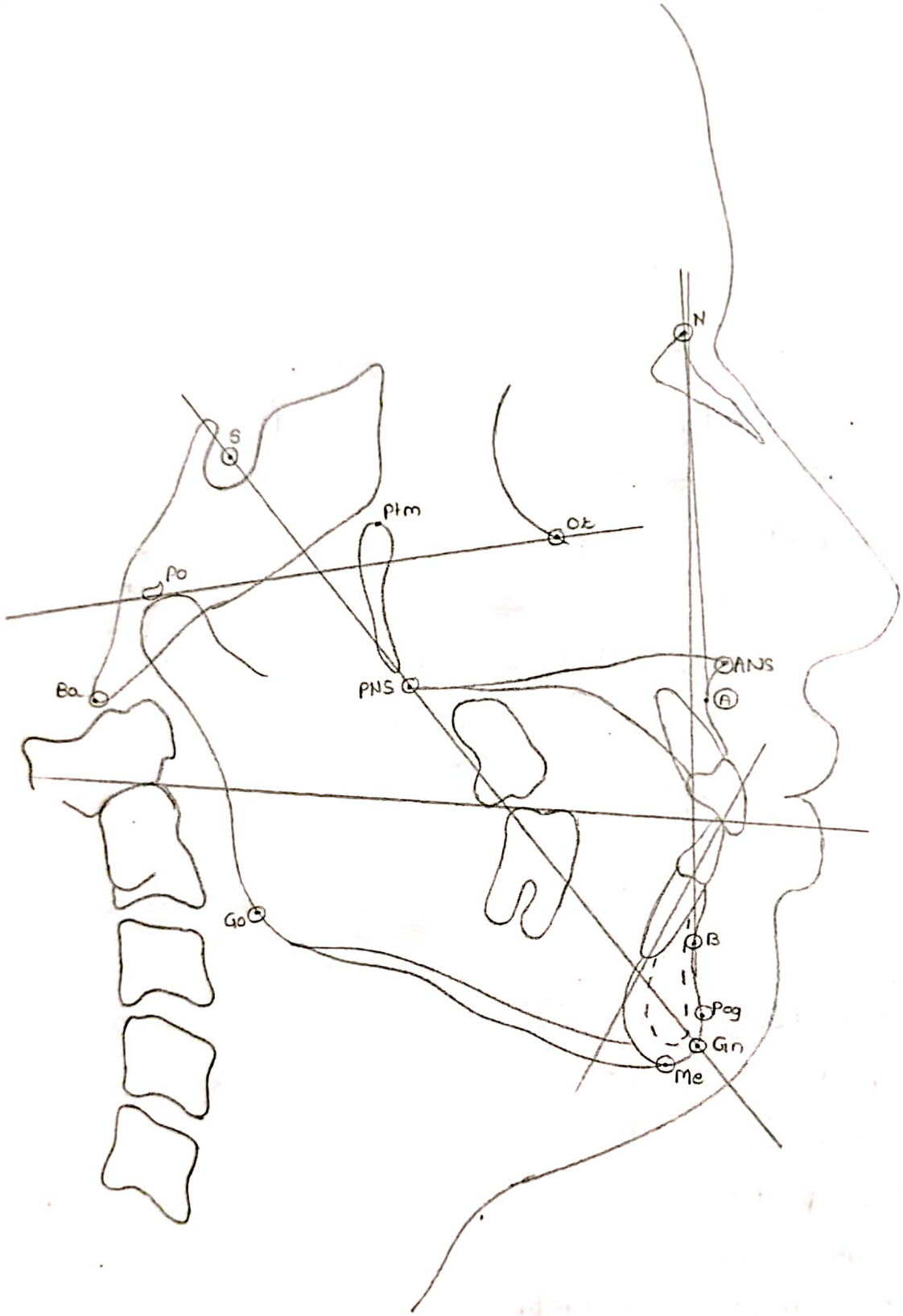

2] Steiner's Analysis.

Variable	Mean Value	Articulated Value	Interpretation.
A] Skeletal.			
SNA	79	80°	prognathic maxilla class II.
SNB	80	88°	Prognathic mandible. class III.
ANB	2 ± 2	2°	Average.
occlusal plane angle	1		
Mandibular plane angle	14	12°	Horizontal growth pattern.
	32	22°	Horizontal growth pattern.
B] Dental.			
Upper incisor to NA.	22	37°	Proclined upper incisor. class II div I
Upper incisor to NA linear	4	8 mm	labially displaced incisors
lower incisor to NB	25	38°	Class II div I.
lower incisor to NB	4	9 mm	labially displaced incisr
Interincisal angle	130	110°	proclined upper & lower teeth.
Angles class II		div I	malocclusion.

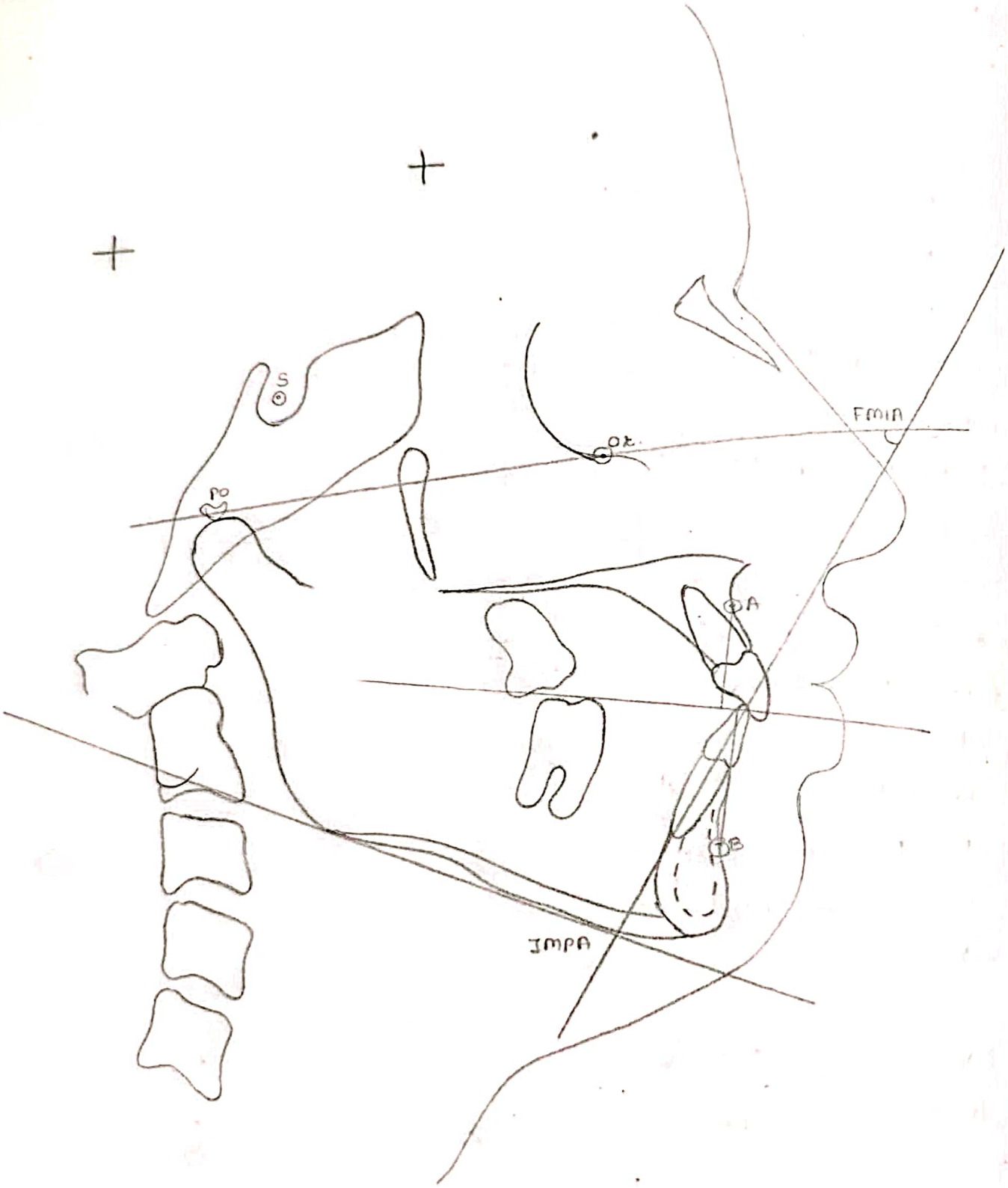
S
Or.
FMIA
Po
A
B
IMPA

Tweed's Analysis.

Variable.	Mean	Articulated	
FMIA	65 3°		
IMPA	90°	53°	Horizontal growth.
FMPA	25°	106°	Retrognathic Mandible
		21°	Retrognathic mandible.

Witt's Appraisal.

AO - BO = +2 mm

Angle's class II malocclusion.

PROFESSOR & HEAD
Dept. of Orthodontics
D Y Patil Dental School
D Y Patil Knowledge City
Charoli (Bk), Via Lohegaon, Pune - 412105

Department Of Prosthodontics And Crown & Bridge

Record Book

D Y PATIL GROUP

D Y PATIL DENTAL SCHOOL

Dr. D. Y. Patil Knowledge City, Charholi (BK) Via- Lohegaon, Pune- 412105

DEPARTMENT OF PROSTHODONTICS

CROWN AND BRIDGE & IMPLANTOLOGY

CERTIFICATE

THIS IS TO CERTIFY THAT :

MS/~~MR~~ ....MUNIFA.....NAZ.....

Roll No. ..52..... (III B.D.S.) Year 20..21.. to 20..22..

Roll No. ...47..... (IV B.D.S.) Year 20..22..to 20..23..

HAS COMPLETED SATISFACTORILY

THE CLINICAL B.D.S. PRACTICAL PROGRAM IN PROSTHODONTICS

AS PRESCRIBED BY THE MAHARASHTRA UNIVERSITY OF HEALTH SCIENCES

13.05.23

(INSTRUCTOR IN-CHARGE, III B.D.S.) **(HEAD OF DEPARTMENT)**

13/5/23 13/05/2023

(INSTRUCTOR IN-CHARGE, IV B.D.S.) **(HEAD OF DEPARTMENT)**

Head of Department of Prosthodontics
DY PATIL DENTAL SCHOOL
DY Patil Knowledge City, Charholi
Lohegaon,Pune - 412105

Date .....

UNIVERSITY ROLL NO.
49598



D Y PATIL GROUP

D Y PATIL DENTAL SCHOOL

Dr. D. Y. Patil Knowledge City, Charholi (BK) Via- Lohegaon, Pune- 412 105

DEPARTMENT OF PROSTHODONTICS

CROWN AND BRIDGE & IMPLANTOLOGY

26/07/2023

INTERNAL EXAMINER

26/7/23

EXTERNAL EXAMINER

UNIVERSITY ROLL NO.
49598

INTERNAL EXAMINER

EXTERNAL EXAMINER

UNIVERSITY ROLL NO.

INTERNAL EXAMINER

EXTERNAL EXAMINER

UNIVERSITY ROLL NO.

OPD No.
Date

Department of Prosthodontics
DY Patil Dental School, Lohegaon
Pune

Case Record
Complete Denture Therapy

I. Name of the Student : Munifa Naz

Roll No. : 8 47.

Patient Data

Name : Gorakhnath Rai

Age : 79

Sex : Male

Address : Chese Park, Pune.

Phone No : 9552355779

Occupation : Retired (Defence)

II. Chief Complaint Patient wants to get missing teeth replaced.

III. Systemic Status NRH

Medications if any

IV. Personal History NRH.

Diet : Mixed diet.

Habits: None.

VI. Mental Attitude (House Classification) Philosophical

VII. Extra Oral Examination

i. Facial form

Outline for : Square/Tapering/Sq.tapering/Ovoid

Profile : Straight/Convex/Concave

ii. Lips(Static Position)

a) Length : Short/Medium/ Long

b) Thickness: Normal

c) Support : Adequately supported / Unsupported

d) Mobility : Normal / Reduced mobility/Paralysis

e) Commissure: Present

iii. Temporomandibular joint

a) Tenderness : NAD

b) Mouth opening : NAD

c) Deviation NAD

d) Clicking/Crepitus : NAD

B. Clinical Step and Laboratory Procedures , Materials, and Techniques used:

No.	Step	Date	Material	Sign	Grade.
1.	Primary Impression : Maxillary Mandibulor	1/11/22	Impression Compound Muccocompressive technique.	Dr. Paulami	A A
2.	Primary cast perparation	2/11/22	Dental Plaster Double Pour technique.	Dr. Jitendra	A A
3.	Custom tray fabrication	3/11/22	Cold cure resin - Dough method	Dr. Ashish	A
4.	Final Impression: Maxillary Mandibulor	5/11/22	Border moulding - green stick. Final imp - ZnOE Paste.	Dr. Paulami	A
5.	Master Cast	5/11/22	Dental Stone.	Dr. Paulami	A
6.	perparation of Wax occiusal rims	6/11/22	Modelling Wax.	Dr. Paulami	A
7.	Jaw relation record	9/11/22	Orientation & Vertical	Dr. Jitendra	A
8.	Transfer of sealed Jaw relation record to the articulator	9/11/22	Mean value articulator, Dental Plaster.	Dr. Jitendra	A A
9.	Selecation of teeth				
10.	Teeth arrangement	10/11/22	maxillary & Mandibular.	Dr. Paulami	A

11.	Try-in and Verification of jaw relation record	12/11/22.	Teeth arrangement	Dr. Paulami	A
12.	Perparation of mould, wax elimination, processing	14/11/22	Flasking, Dewaxing, Packing, Curing.	Dr. Paulami	A
13.	trimming, regovery of the denture, finishing and polishing	16/11/22	Sand paper, finishing, Polishing, Pumice stone, Buffing.	Dr. Paulami	A
14.	Denture insertion	18/11/22.	Denture Delivery.	Dr. Paulami	A+
15.	Recall checkup				

Accomplishment : Satisfactory / Unsatisfactory

Patient's Signature :

Staff Incharge Signature : 07/07/23

HOD Signature

D Y PATIL GROUP

D Y PATIL DENTAL SCHOOL

Dr. D. Y. Patil Knowledge City, Charholi (BK) Via- Lohegaon, Pune- 412105

FIRST AND SECOND YEAR B.D.S

DENTAL MATERIAL SCIENCE

RECORD BOOK

CERTIFICATE

Mr. /Ms. : SHRAVANI DNYANESHWAR PHALKE

Roll No. 65 *has Attended and Completed all*

the Practicals Recorded in this Journal.

Date : _____

18/10/23 20/10/23

Signature of The Staff In-charge

DEPARTMENT OF PROSTHODONTICS : DMS

Signature of The Head of Dept.

8/1/24

Signature of The External Examiner

D Y PATIL GROUP

D Y PATIL DENTAL SCHOOL

Dr. D. Y. Patil Knowledge City, Charholi (BK) Via- Lohegaon, Pune- 412105

FIRST AND SECOND YEAR B.D.S

DENTAL MATERIAL SCIENCE

RECORD BOOK

8/1/24

INTERNAL EXAMINER

8/1/24

EXTERNAL EXAMINER

UNIVERSITY ROLL NO.
37091

INTERNAL EXAMINER

EXTERNAL EXAMINER

UNIVERSITY ROLL NO.
37091

WORK DONE

Sr.No.	Manipulation	Remarks	Signature
1)	Manipulation of Type II Gypsum product (dental plaster) - initial setting time - 4 min Total setting time - 14 min 9 sec		
2)	Manipulation of type III gypsum product (dental stone) Initial setting time - 12 min 17 sec Final setting time - 20 min 19 sec		
3	Manipulation of impression compound to make a trauma impression		
4	Manipulation of type II gypsum product using Nail Initial setting time - 1 min Final setting time - 7 min 20 sec		
5	Manipulating Type I Gypsum product using Nail as reminder. Initial time Setting 14 min Final setting time : 31 min 17 s		
6	manipulation of type III gypsum product using Nail Initial setting time - 4 min 6 s Final setting time - 8 min 57 s		
7)	Manipulation of 306 impression paste Initial setting time - 3 min 2 s Final setting time - 9 min 35 s		

D Y PATIL GROUP

D Y PATIL DENTAL SCHOOL

Dr. D. Y. Patil Knowledge City, Charholi (BK) Via- Lohegaon, Pune- 412105

PRE-CLINICAL PROSTHODNTICS

CERTIFICATE

THIS IS TO CERTIFY THAT :

MS/MR ..SMITA DIGAMBER SURYAWANSHI.....

Roll No. ..... (I B.D.S.) Year 20..... to 20.....

Roll No. ..... (II B.D.S.) Year 20.22. to 20.23..

HAS COMPLETED SATISFACTORILY

COMPLETED THE EXERCISE IN **PRE-CLINICAL PROSTHODONTICS** PROGRAM IN B.D.S. COURSE

AS PRESCRIBED BY THE MAHARASHTRA UNIVERSITY OF HEALTH SCIENCES

16/10/23

(INSTRUCTOR IN-CHARGE, I B.D.S.)

18/10/23

(INSTRUCTOR IN-CHARGE, II B.D.S.)

PRE-CLINICAL PROSTHODONTICS

Head of Department of Prosthodontics
DY PATIL DENTAL SCHOOL
DY Patil Knowledge City, Charholi
Lohegaon, Pune-412105

(HEAD OF DEPARTMENT)

Date ...19/10/2023.....

QUESTIONS :-

1. What is the type of articulator you are using ?

→ Non-arcon, Non-adjustable, mean value articulator (permits horizontal & vertical motion).

2. What points do you check prior to mouting to wax occlusal rims on the articulator ?

1) check position of vertical incisal pin, it should be at centre of incisal table.
2) The upper end of vertical pin should flush with upper axis of articulator.
3) Horizontal incisal pin should be in its position marking midline marked on occlusal rims.
4) Rims occlusal plane considered as midline of an articulator.

3. Is this articulator you are using a arcon or non-arcon type of articulator ?

→ Non-arcon type of articulator in which condylar elements are located on upper member and condylar guidance on lower member of articulator.

Date	Nature of Work Done	Sign of Instructor
27/3/22	Transfer of maxillary and mandibular jaw relation to articulator.	

QUESTIONS :-

1. **Why should you soak the articulator with mounted casts in cold water prior to the arrangement of teeth?**

→ To avoid the spillage of wax.

2. **What is the position of the maxillary 1st molar?**

→ The position of maxillary 1st molar in intraorally is average 0.3mm above parotid gland.
→ mesiobuccal cusp of 1st molar sets in central fossa of mandibular 1st molar.

3. **What is Pound's triangle?**

→ It is triangle formed by lines joining the apex of canine & the retromolar pad.

4. **What is vertical overlap?**

→ Vertical overlap between upper & lower incisors is overbite
Average (2mm) :

5. **What is horizontal overlap?**

Date	Nature of Work Done	Sign of Instructor
13/4/23	Complete teeth arrangement of	
	max. & mand. set (1) (max &	
	mand. [Anterior & posterior teeth].	

31/07/23

Department Of Pedodontics and Preventive Dentistry

Record Book

Record Book Details

Internship

Record Book Details

Internship

Department of Public Health Dentsitry

D Y PATIL DENTAL SCHOOL

Department of Public Health Dentistry

This is to certify that Intern named Mr/Ms Ajmera krishna. ,

Roll No 1 has satisfactorily completed the work of this department as per the DCI guidelines.

I hereby give him/her the certification of internship completion from this department.

Date: 19/12/22

PROFESSOR & HEAD
Dept. of Public Health Dentistry
D Y Patil Dental School
D Y Patil Knowledge City
Charoli (Bk), Via Lohegaon, Pune - 412105

Head of the Department

Department of Public Health Dentistry

ASSIGNED CLINICAL EXERCISES AND OUTREACH PROGRAM DURING INTERNSHIP

1. Organizing Dental Camp	5
2. Participation in Dental Camp	10
3. Satellite Center Charholi PHC	5
4. Rajiv Gandhi Hospital Posting	5
5. Comphrensive Dental Care in Integrated Clinic	10

OUTREACH ACTIVITIES

No of camps organised:

Sr No	Date	Venue
1.	19/11/22.	Sant Tukaram Maharaj Mandir.
2.	23/11/22.	Trinity Sheal Dighi.
3.	24/11/22.	Smart kids primary school.
4.	25/11/22	Akanksha Academy Lohegaon.
5.		
6.		
7.		
8.		
9.		
10.		

No of Camps Attended:

Sr No	Date	Venue
1.	19/11/22.	Sant Tukaram Maharaj Mandir.
2.	23/11/22.	Trinity Sheal Dighi.
3.	24/11/22.	Smart kids primary school.
4.	25/11/22.	Akansha Academy Lohegaon.
5.	30/11/22.	Santulan Bhavan Kharadi.
6.	1/12/22	Fun & fun Preschool.
7.	3/12/22.	SS English Medium School.
8.		
9.		
10.		
11.		
12.		
13.		
14.		
15.		

Comphrensive Dental Care in Integrated Clinic

Sl No	Date	OPD No	Name of Patient	Treatment	Sign
1.	3/01/22	80192	Manisha Sonawane	Scaling	
2.	3/01/22	80193	Bapurao Harinwale	Scaling	
3.	5/01/22	80194	Monika Devkar	Extraction	
4.	5/01/22	80195	Adarsh Devkar	Extraction	
5.	5/01/22	80196	Janhavi kholam	Scaling	
6.	10/01/22	80197	Sushmakholam	Extraction	
7.	10/01/22	80198	Prakash Palkar	Oral prophylaxis	
8.	10/01/22	80263	Rutuja Pol	Scaling	
9.	10/01/22	80264	Nitin Jangale	Extraction	
10.	11/01/22	80265	Reshma Ingale	Scaling	
11.	11/01/22	80266	Ashis Dhiwar	Oral prophylaxis	
12.	11/01/22	80267	Sujit kalokhi	Extraction	
13.	13/01/22	80268	Jyoti Varma	Toothbrush demo	
14.	13/01/22	80269	Dinesh Sonar	Scaling	
15.	14/01/22	80270	Nikhil Gomase	Scaling	

D Y PATIL DENTAL SCHOOL

Department of Public Health Dentistry

This is to certify that Intern named Mr/Ms Ajrekar Iftisam.,

Roll No 2 has satisfactorily completed the work of this department as per the DCI guidelines.

I hereby give him/her the certification of internship completion from this department.

Date: 19/12/22

PROFESSOR & HEAD
Dept. of Public Health Dentistry
D Y Patil Dental School
D Y Patil Knowledge City
Charoli (Bk), Via Lohegaon, Pune - 412105

Head of the Department

Department of Public Health Dentistry

ASSIGNED CLINICAL EXERCISES AND OUTREACH PROGRAM DURING INTERNSHIP

1.	Organizing Dental Camp	5
2.	Participation in Dental Camp	10
3.	Satellite Center Charholi PHC	5
4.	Rajiv Gandhi Hospital Posting	5
5.	Comphrensive Dental Care in Integrated Clinic	10

OUTREACH ACTIVITIES

No of camps organised:

Sr No	Date	Venue
1.	25/11/22.	Akansha Academy Lohegaon.
2.	30/11/22	Santulan Bhavan Khandi
3.	1/12/22.	Fun & fun Preschool.
4.		
5.		
6.		
7.		
8.		
9.		
10.		

No of Camps Attended:

Sr No	Date	Venue
1.	19/11/22.	Sant Tukaram Maharaj Mandir.
2.	23/11/22.	Trinity school Dighi.
3.	24/11/22.	Smart kids Primary School.
4.	25/11/22.	Akansha Academy Lohegaon.
5.	30/11/22.	Santulan Bhavan Khandi.
6.	5/12/22.	Eyes school.
7.	6/12/22.	PHC Wagholi.
8.	9/12/22.	Trinity School Dighi.
9.		
10.		
11.		
12.		
13.		
14.		
15.		

Satellite Centre Postings

PHC Charholi

Sr No	Date	Signature
1.	2/10/22	
2.	7/10/22	
3.	11/10/22	
4.	16/10/22	
5.	19/10/22	
6.	26/10/22	
7.	1/11/22	
8.	5/11/22	

Late Shri Rajeev Gandhi Hospital, Yerwada

Sr No	Date	Signature
1.	7/11/22.	
2.	12/11/22.	
3.	16/11/22	
4.	21/11/22	
5.	27/11/22	
6.	2/12/22	
7.	5/12/22	
8.	7/12/22	
9.	11/12/22.	

Comphrensive Dental Care in Integrated Clinic

Sl No	Date	OPD No	Name of Patient	Treatment	Sign
1.	11/11/22	80335	Pankaj Kanlar	Scaling	
2.	11/11/22	80336	Malika Detroja	Extraction	
3.	11/11/22	80337	Pradeep Rave	Scaling	
4.	11/11/22	80338	Prachi Sharma	Oral prophylaxis	
5.	11/11/22	80339	Vasant Borat	scaling	
6.	11/11/22	80340	Alakanshi Mehta	Extraction	
7.	11/11/22	80341	Ashish Goswami	Scaling	
8.	12/11/22	80414	Pankaj Kadam	scaling	
9.	12/11/22	80415	Sanita Deter	Extraction	
10.	12/11/22	80416	Sohan Gaikwad	Scaling	
11.					
12.					
13.					
14.					
15.					

D Y PATIL DENTAL SCHOOL

Department of Public Health Dentistry

This is to certify that Intern named Mr/Ms Agarkar Mrutyuja Vinod,

Roll No 1 has satisfactorily completed the work of this department as per the DCI guidelines.

I hereby give him/her the certification of internship completion from this department.

Date: 09/10/23

PROFESSOR & HEAD
Dept. of Public Health Dentistry
D Y Patil Dental School
D Y Patil Knowledge City
Charoli (Bk), Via Lohegaon, Pune - 412105

Head of the Department

Department of Public Health Dentistry

ASSIGNED CLINICAL EXERCISES AND OUTREACH PROGRAM DURING INTERNSHIP

1. Organizing Dental Camp	5
2. Participation in Dental Camp	10
3. Satellite Center Charholi PHC	5
4. Rajiv Gandhi Hospital Posting	5
5. Comphrensive Dental Care in Integrated Clinic	10

OUTREACH ACTIVITIES

No of camps organised:

Sr No	Date	Venue
1.	28/7/23	Ikids Paradise Preschool
2.	17/8/23	Time kids Dhanori
3.	5/9/23	Shining Star School.
4.		
5.		
6.		
7.		
8.		
9.		
10.		

No of Camps Attended:

Sr No	Date	Venue
1.	28/7/23	Ikids Paradise Preschool
2.	3/8/23	MMIT Lohegaon
3.	4/8/23	Bumble bee preprimary school
4.	7/8/23	~~Imma~~ Immanuel School
5.	17/8/23	Time kids Dhanori
6.	22/8/23	Tapas foundation
7.	24/8/23	Kidzenia Dhanori
8.	31/8/23	DY Patil International School
9.	2/9/23	Little sprout preschool
10.	5/9/23	Shinining star school
11.		
12.		
13.		
14.		
15.		

Satellite Centre Postings

PHC Charholi

Sr No	Date	Signature
1.	30/7/23	
2.	5/8/23	
3.	12/8/23	
4.	21/8/23	
5.	25/8/23	
6.	31/8/23	
7.	4/9/23	
8.	6/9/23	

Late Shri Rajeev Gandhi Hospital, Yerwada

Sr No	Date	Signature
1.	7/9/23	
2.	15/9/23	
3.	18/9/23	
4.	21/9/23	
5.	23/9/23	
6.	25/9/23	
7.	27/9/23	
8.	4/10/23	
9.	6/10/23	

Comphrensive Dental Care in Integrated Clinic

Sl No	Date	OPD No	Name of Patient	Treatment	Sign
1.	25/7/23	113315	Manihar Waseem	Scaling	
2.	28/7/23	131449	Siddhesh Patil	Extraction.	
3.	27/7/23	113321	Sumita Devi	Extraction	
4.	28/7/23	131450	Prajwal Patil	Extraction.	
5.	29/7/23	113268	Sunny Dalvi	Oral Prophylaxis	
6.	31/7/23	131452	Durgesh Sapkal	Scaling	
7.	1/8/23	113271	Omkar Dhotre	Extraction	
8.	2/8/23	131466	Sumedh Lokhande	Scaling	
9.	3/8/23	113273	Akash Sumindre.	Scaling	
10.	4/8/23	131471	Pranay Shinde	Scaling.	
11.	5/8/23	113275	Sachin Jadhav	Extraction	
12.	6/8/23	131415	Tanvi Jadhav	Scaling	
13.	7/8/23	133527	Kiran Devkar	Scaling	
14.	8/8/23	133528	Amruta Pawar	Extraction	
15.	9/8/23	133529	Sanjay Patil	Oral Prophylaxis	

D Y PATIL DENTAL SCHOOL

Department of Public Health Dentistry

This is to certify that Intern named Mr/Ms Aglave Sakshi Suresh,

Roll No 2 has satisfactorily completed the work of this department as per the DCI guidelines.

I hereby give him/her the certification of internship completion from this department.

Date: 9/10/23

PROFESSOR & HEAD
Dept. of Public Health Dentistry
D Y Patil Dental School
D Y Patil Knowledge City
Charoli (Bk), Via Lohegaon, Pune - 412105

Head of the Department

Department of Public Health Dentistry

ASSIGNED CLINICAL EXERCISES AND OUTREACH PROGRAM DURING INTERNSHIP

1.	Organizing Dental Camp	5
2.	Participation in Dental Camp	10
3.	Satellite Center Charholi PHC	5
4.	Rajiv Gandhi Hospital Posting	5
5.	Comphrensive Dental Care in Integrated Clinic	10

OUTREACH ACTIVITIES

No of camps organised:

Sr No	Date	Venue
1.	3/8/23	MMIT
2.	4/8/23	Bumble Bee preprimary School
3.	7/8/23	Immanual school.
4.		
5.		
6.		
7.		
8.		
9.		
10.		

No of Camps Attended:

Sr No	Date	Venue
1.	28/7/23	Ikids Paradise Preschool
2.	3/8/23	MMIT Lohegaon
3.	4/8/23	Bumble Bee preprimary school
4.	7/8/23	Immanual School
5.	17/8/23	Time kids Dhanori
6.	22/8/23	Tapas foundation.
7.	24/8/23	Kidzenia Dhanori
8.	31/8/23	DY Patil International School
9.	2/9/23	Little sprout preschool
10.	5/9/23	Shinning star School.
11.		
12.		
13.		
14.		
15.		

Satellite Centre Postings

PHC Charholi

Sr No	Date	Signature
1.	30/7/23	
2.	5/8/23	
3.	12/8/23	
4.	21/8/23	
5.	25/8/23	
6.	31/8/23	
7.	4/9/23	
8.	6/9/23	

Late Shri Rajeev Gandhi Hospital, Yerwada

Sr No	Date	Signature
1.	7/9/23	
2.	15/9/23	
3.	18/9/23	
4.	21/9/23	
5.	23/9/23	
6.	25/9/23	
7.	27/9/23	
8.	4/10/23	
9.	6/10/23	

Comphrensive Dental Care in Integrated Clinic

Sl No	Date	OPD No	Name of Patient	Treatment	Sign
1.	25/7/23	133530	Chandama Naik	Scaling	
2.	26/7/23	133531	Anuj Kawale	Extraction	
3.	27/7/23	133532	Anjali Shelke	Extraction	
4.	28/7/23	133533	Amar Barwase	Extraction	
5.	29/7/23	133534	Pooja Gawane.	Extraction	
6.	31/7/23	133535	Dhanashree Mane	Scaling	
7.	1/8/23	133536	Reshma Bhagat.	Extraction	
8.	2/8/23	130075	Tejal Kadam	Scaling	
9.	3/8/23	127376	Bharat Shahane.	Scaling	
10.	4/8/23	130085	Dipak rathod	Scaling	
11.	5/8/23	127372	Shivaji Birajdar.	Scaling	
12.	6/8/23	130093	Kavita Patil	Scaling	
13.	7/8/23	127364	Sunil Pawar	Extraction	
14.	8/8/23	130097	Sangita Pawar	Extraction	
15.	9/8/23	127364	Anand Shendge.	Scaling	

Satellite Centre Postings

PHC Charholi

Sr No	Date	Signature
1.	2/10/22	
2.	4/10/22.	
3.	6/10/22	
4.	7/10/22	
5.	8/10/22.	
6.	9/10/22	
7.	12/10/22.	
8.	19/10/22	

Late Shri Rajeev Gandhi Hospital, Yerwada

Sr No	Date	Signature
1.	21/10/22	
2.	24/10/22	
3.	28/10/22.	
4.	29/10/22	
5.	2/11/22	
6.	3/11/22.	
7.	7/11/22.	
8.	9/11/22	
9.	11/11/22	

Record Book Details

Internship

Department of Oral Medicine and Radiology

D Y PATIL
DENTAL SCHOOL
(Affiliated to Maharashtra University of health Sciences, Nashik)
Dr D Y Patil Knowledge City, CharoliBudruk, via Lohegaon, Pune 412 105

INTERNSHIP PERFORMANCE DATA BOOK

Department of Oral Medicine and Radiology

Name of the Student: Priyansh Bhimani

Academic Year : 2021-22

Year of Admission : 2017

Year of Passing Final BDS : 2021

PROFESSOR & HEAD
Dept. of Oral Medicine & Radiology
D Y Patil Dental School
D Y Patil Knowledge City
Charoli (Bk.), Via Lohegaon, Pune - 412105

D Y PATIL
DENTAL SCHOOL
(Affiliated to Maharashtra University of health Sciences, Nashik)
Dr D Y Patil Knowledge City, CharoliBudruk, via Lohegaon, Pune 412 105

Internship Completion Certificate

This is to certify that –

Mr. ~~Miss./Mrs.~~ Brijaush Bhimani

Has satisfactorily completed the departmental work as per the DCI guidelines within his/her clinical posting.Further it is stated that during the clinical posting period, his /her clinical work and conduct was found to be satisfactory.

Head of the Department

Department of Oral Medicine and Radiology

PROFESSOR & HEAD
Dept. Of Oral Medicine & Radiology
D Y Patil Dental School
D Y Patil Knowledge City
Charoli (Bk), Via Lohegaon, Pune - 412105.

Oral Medicine & Radiology

- Standardized examination of patients 25
- Radiographs (IOPA) 25
- Special cases 5
- Extra oral Radiographs 1
- Cephalogram 1

Internship Programme Work Done

A) Standardized Examination of Patients with common Dental complaints

Sr No.	OPD No	Name of the Patient	Age/Sex	Diagnosis	Signature of Staff
1	99219	Kanchan Lad	23/F	Decayed ↓.	
2	99463	Krushnali Akarkare	17/F	Decayed ↓.	
3	99228	Krishnakant A.	30/M	Mobile ↓.	
4	99169	Mahadev Redkar	28/M	Decayed ↓.	
5	99257	Priyanka Babar	30/F	Fractured ↓.	
6	44622	Malisha Alambare	25/F	Decayed ↓.	
7	99223	Saneebsha	22/F	Fractured ↓.	
8	99186	Rupali Nalawade	30/F	Missing teeth	
9	99258	Madhuri Divekar	50/M	Mobile teeth	
10	99259	Ravi Puri	24/M	Decayed ↓.	
11	99184	Sumit Rathod	21/M	Decayed ↓.	
12	99170	Kailas Sande	37/M	Mobile ↓.	
13	99175	Gautam Bhosale	25/M	Missing ↓.	
14	99218	Narayan Surve	37/M	Decayed	
15	99222	Sanjivan Jadhav	30/F	Decayed	
16	99227	Pramod Rai	50/M	Mobile	
17	99221	Kamlesh Verma	41/M	Missing	
18	99229	Shriram D.	56/M	Decayed	
19	99197	Namrata T.	51/F	Missing	
20	99199	Yogita Raut	41/F	Decayed.	

B) Special cases

Sr No.	OPD No	Name of the Patient	Age/Sex	Diagnosis	Signature of Staff
1	93276	Shubhash Orhal	52/M	Leuq. Tongue	
2	93872	Shantidevi Gautam	63/F	Candidiasis	
3	94056	Altej Inamdar	19/M	Tobacco pouch	
4	86906	Vijayshree Shinde	45/F	OKC	

C) Radiographs (IOPA)

Sr No.	Date	OPD No	Name of the Patient	Number and types of Radiographs		Signature of Staff
1	13/7/22	99219	Kanchan Lad	IOPA	1	
2	13/7	94463	Krushnali Akambare	IOPA	1	
3	15/7	99228	Krishnakant A.	IOPA	1	
4	15/7	99169	Mahadev Redkar	IOPA	1	
5	15/7	99257	Priyanka Babar	IOPA	2	
6	15/7	94622	Mrunal Adambare	IOPA	2	
7	16/7	99223	Saneebsha	IOPA	1	
8	16/7	99186	Rupali Nalawade	IOPA	2	
9	16/7	99258	Madhuri Divekar	IOPA	2	
10	18/7	99259	Ravi Puri	IOPA	1	
11	18/7	99184	Sumit Rathod	IOPA	1	
12	18/7	99170	Kailas Sande	IOPA	1	
13	18/7	99175	Gautam Bhosale	IOPA	2	
14	19/7	99219	Narayan Surve	IOPA	1	
15	19/7	99222	Sanjana Jadhav	IOPA	2	
16	19/7	99227	Pramod Rai	IOPA	1	
17	20/7	99221	Kamlesh Verma	IOPA	1	
18	20/7	99224	Shivaay P.	IOPA	1	
19	20/7	99197	Namrata T.	IOPA	1	

D Y PATIL
DENTAL SCHOOL
(Affiliated to Maharashtra University of health Sciences, Nashik)
Dr D Y Patil Knowledge City, CharoliBudruk, via Lohegaon, Pune 412 105

INTERNSHIP PERFORMANCE DATA BOOK

Department of Oral Medicine and Radiology

Name of the Student: Nidhi Deglurkar

Academic Year : 2020 - 22

Year of Admission : 2017

Year of Passing Final BDS : 2021

D Y PATIL
DENTAL SCHOOL
(Affiliated to Maharashtra University of health Sciences, Nashik)
Dr D Y Patil Knowledge City, CharoliBudruk, via Lohegaon, Pune 412 105

Internship Completion Certificate

This is to certify that –

Mr. /Miss./Mrs. Nidhi Deglurkar

Has satisfactorily completed the departmental work as per the DCI guidelines within his/her clinical posting.Further it is stated that during the clinical posting period, his /her clinical work and conduct was found to be satisfactory.

Head of the Department

Department of Oral Medicine and Radiology

PROFESSOR & HEAD
Dept. Of Oral Medicine & Radiology
D Y Patil Dental School
D Y Patil Knowledge City
Charoli (Bk), Via Lohegaon, Pune - 412105.

Oral Medicine & Radiology

- Standardized examination of patients 25
- Radiographs (IOPA) 25
- Special cases 5
- Extra oral Radiographs 1
- Cephalogram 1

Internship Programme Work Done

A) Standardized Examination of Patients with common Dental complaints

Sr No.	OPD No	Name of the Patient	Age/Sex	Diagnosis	Signature of Staff
1	99012	Mangal Zambore	45/F	Decayed	
2	99013	Phulabai Bhore	69/F	Mobility	
3	99008	Bhavna Singh	79/F	Missing 7.	
4	98939	Shrikar Dabhiya	42/M	Decayed	
5	98999	Kamod Joshi	57/M	Mobility	
6	98994	Jyita Tiwari	44/F	Decayed	
7	98948	Falguni Kini	35/F	Cavity	
8	99016	Jeevan Magan	51/M	Mobility	
9	99023	Monika Patil	38/F	Decayed	
10	80084	Ujjavala Nigut	47/F	Missing	
11	98981	Lata Joshi	76/F	Missing	
12	98953	Ravikant Tiwari	32/M	Decayed	
13	98979	Harsh Bidhu	56/M	Missing	
14	98943	Pravin Joshi	24/M	Missing	
15	99032	Savita Bhingude	46/F	Decayed	
16	98950	Rajan Kini	87/M	Mobility	
17	98944	Sudhir Chitale	64/M	Mobility	
18	98980	Hemali Mota	68/F	Missing	
19	98965	Gajanan Deekar	63/M	Missing	
20	98988	Vijay Gangar	70/M	Missing	
21	98963	Dakan Kumar	58/M	Mobility	
22	98971	Dinesh Mehta	55/F	Decayed	

B) Special cases

Sr No.	OPD No	Name of the Patient	Age/Sex	Diagnosis	Signature of Staff
1	100721	Balu Narayankar	38/M	Leukoplakia	
2	100945	Akash Katake	22/M	Leukoplakia	
3	101068	Sunanda Gaikwad	60/F	Leukoplakia	

C) Radiographs (IOPA)

Sr No.	Date	OPD No	Name of the Patient	Number and types of Radiographs		Signature of Staff
1	14/8/22	99012	Mangal Zanzarde	IOPA	1	
2	14/8	99013	Phulabai Bhoye	IOPA	2	
3	14/8	99008	Bhavana Singh	IOPA	1	
4	16/8	98939	Shivika Dadhiya	IOPA	1	
5	16/8	98999	Ramod Joshi	IOPA	2	
6	16/8	98994	Jivita Tewari	IOPA	2	
7	16/8	98948	Falguni Kini	IOPA	1	
8	17/8	99016	Jeevan Magan	IOPA	3	
9	17/8	99023	Monika Patil	IOPA	1	
10	17/8	800824	Ujjwala Nighot	IOPA	1	
11	17/8	98981	Asha Joshi	IOPA	1	
12	20/8	99953	Ravikant Divali	IOPA	1	
13	20/8	98979	Harsh Bidhu	IOPA	2	
14	20/8	98943	Pravin Joshi	IOPA	2	
15	20/8	99032	Savita Bhingade	IOPA	1	
16	21/8	98850	Rajan Kini	IOPA	3	
17	21/8	98944	Saddin Chitale	IOPA	4	
18	21/8	98980	Hemali Mato	IOPA	1	
19	22/8	98968	Gajanan Trehan	IOPA	1	
20	22/8	98988	Vijay Gangar	IOPA	2	
21	22/8	98963	Dasan Kumar	IOPA	1	
22	22/8	98971	Dinesh Mehta	IOPA	1	

D) Extra-oral Radiographs

Sr No.	Date	OPD No	Name of the Patient	Projection		Signature of Staff
1	16/8	99013	Bhulabai Bhoi	OPG		
2	23/8	98995	Tanmaya Kumar		Lat Ceph	

D Y PATIL
DENTAL SCHOOL
(Affiliated to Maharashtra University of health Sciences, Nashik)
Dr D Y Patil Knowledge City, CharoliBudruk, via Lohegaon, Pune 412 105

INTERNSHIP PERFORMANCE DATA BOOK

Department of Oral Medicine and Radiology

Name of the Student: Nishika Deole

Academic Year : 2021 - 22

Year of Admission : 2017

Year of Passing Final BDS : 2021

D Y PATIL
DENTAL SCHOOL
(Affiliated to Maharashtra University of health Sciences, Nashik)
Dr D Y Patil Knowledge City, CharoliBudruk, via Lohegaon, Pune 412 105

Internship Completion Certificate

This is to certify that –

Mr. /Miss./Mrs. Nishika Deole

Has satisfactorily completed the departmental work as per the DCI guidelines within his/her clinical posting.Further it is stated that during the clinical posting period, his /her clinical work and conduct was found to be satisfactory.

Head of the Department

Department of Oral Medicine and Radiology

PROFESSOR & HEAD
Dept. Of Oral Medicine & Radiology
D Y Patil Dental School
D Y Patil Knowledge City
Charoli (Bk), Via Lohegaon, Pune - 412105.

Oral Medicine & Radiology

- Standardized examination of patients 25
- Radiographs (IOPA) 25
- Special cases 5
- Extra oral Radiographs 1
- Cephalogram 1

Internship Programme Work Done

A) Standardized Examination of Patients with common Dental complaints

Sr No.	OPD No	Name of the Patient	Age/Sex	Diagnosis	Signature of Staff
1	99669	Pramod Nikhbhane	62/M	Mobility	
2	99679	Shanbar Thorat	70/M	Missing	
3	99650	Deepali Ghule	21/F	Decayed	
4	99711	Rajdevi Agarwal	64/F	Mobility	
5	99668	Jayshree Mitama	38/F	Multiple caries	
6	99643	Nikhil Pawar	18/M	Decayed	
7	99663	Beeti Narode	27/F	Decayed	
8	99665	Anuradha Shinde	30/F	Missing + .	
9	99657	Sitaram Patre	79/F	Mobile + .	
10	99672	Sushil Kedari	27/M	Missing + .	
11	99639	Yogesh Waghmare	35/M	Decayed + .	
12	99690	Kuldeep Patekar	50/M	Mobile +	
13	99637	Amol Kotwal	27/M	Decayed + .	
14	99644	Arati Shinde	21/M	Decayed + .	
15	99648	Malini Pandey	44/F	Mobile + .	
16	99661	Rupali ~~Shinde~~ Patil	40/F	Mobile + .	
17	99683	Ajay Shinde	45/M	Decayed + .	
18	99660	Sunita Pandey	39/F	Decayed +	
19	99656	Ashwini Shinde	17/F	Fractured +	

B) Special cases

Sr No.	OPD No	Name of the Patient	Age/Sex	Diagnosis	Signature of Staff
1	98239	Gangadhar Anreeja	67/M	OSMF	
2	98361	Shilpa Patil	31/F	Supernumerary teeth	
3	96652	Hari Kekan	46/M	OSMF	

C) Radiographs (IOPA)

Sr No.	Date	OPD No	Name of the Patient	Number and types of Radiographs		Signature of Staff
1	13/8	99669	Kamod Nhimabhau	IOPA	1	
2	13/8	99679	Shankar Thorat	IOPA		
3	14/8	99650	Deepali Phule	IOPA	1	
4	14/8	99711	Rajdevi Rawal	IOPA	2	
5	14/8	99668	Tayshree Hitawa	IOPA	2	
6	14/8	99643	Nikhil Pawar	IOPA	1	
7	16/8	99663	Preeti Narode	IOPA	1	
8	16/8	99665	Anuradha Shinde	IOPA	1	
9	16/8	99657	Sitaram Kute	IOPA	2	
10	16/8	99672	Sushil Kedari	IOPA	3	
11	17/8	99639	Yogesh Waghmare	IOPA	1	
12	17/8	99690	Kuldeep Pathan	IOPA	1	
13	17/8	99637	Amol Kotwal	IOPA	2	
14	18/8	99644	Arati Shinde	IOPA	1	
15	18/8	99648	Malini Pandey	IOPA	2	
16	18/8	99661	Rupali Patil	IOPA	2	
17	18/8	99683	Ajay Shinde	IOPA	1	
18	19/8	99660	Santosha Pandey	IOPA	1	
19	19/8	99656	Ashwini Shinde	IOPA	1	

D) Extra-oral Radiographs

Sr No.	Date	OPD No	Name of the Patient	Projection		Signature of Staff
1	17/8	99679	Shankar Thorat	OPG		
2	21/8	99644	Arati Shinde		Lat Ceph.	

D Y PATIL
DENTAL SCHOOL
(Affiliated to Maharashtra University of health Sciences, Nashik)
Dr D Y Patil Knowledge City, CharoliBudruk, via Lohegaon, Pune 412 105

INTERNSHIP PERFORMANCE DATA BOOK

Department of Oral Medicine and Radiology

Name of the Student: Lakshmi Bandebuche

Academic Year : 2021-22

Year of Admission : ~~2018~~ 2017

Year of Passing Final BDS : 2021

PROFESSOR & HEAD
Dept. Of Oral Medicine & Radiology
D.Y. Patil Dental School
Dr. D.Y. Patil Knowledge City
Charoli (Bk.), Via Lohegaon, Pune - 412 105.

D Y PATIL
DENTAL SCHOOL
(Affiliated to Maharashtra University of health Sciences, Nashik)
Dr D Y Patil Knowledge City, CharoliBudruk, via Lohegaon, Pune 412 105

Internship Completion Certificate

This is to certify that –

Mr. /Miss./Mrs. Lakshmi Bandebuche

Has satisfactorily completed the departmental work as per the DCI guidelines within his/her clinical posting.Further it is stated that during the clinical posting period, his /her clinical work and conduct was found to be satisfactory.

Head of the Department

Department of Oral Medicine and Radiology

PROFESSOR & HEAD
Dept. Of Oral Medicine & Radiology
D Y Patil Dental School
D Y Patil Knowledge City
Charoli (Bk), Via Lohegaon, Pune - 412105.

Oral Medicine & Radiology

- Standardized examination of patients 25
- Radiographs (IOPA) 25
- Special cases 5
- Extra oral Radiographs 1
- Cephalogram 1

Internship Programme Work Done

A) Standardized Examination of Patients with common Dental complaints

Sr No.	OPD No	Name of the Patient	Age/Sex	Diagnosis	Signature of Staff
1	99774	Bhavesh Govind Chavan-Sawant	39/M	Mobility	
2	99810	Kumar Dubey	45/M	Decayed	
3	99783	Sohita Tabib	58/F	Decayed	
4	99785	Sujata Kanade	68/F	Mobility	
5	99782	Pratiksha Dandgawal	48/F	Missing	
6	99778	Vishaksha Thote	30/F	Mobility +.	
7	99801	Rajaram Pawde	78/M	Decayed +.	
8	99809	Brijanka Chougule	31/F	Missing +.	
9	99790	Shivram Jadhav	60/M	Decayed +.	
10	99789	Shubhangi Tambe	78/F	Decayed +.	
11	99784	Pushpa Pasi	35/F	Missing +.	
12	99803	Suchalata Shirap	73/F	Decayed +.	
13	99832	Rasika Remde	58/F	Decayed +.	
14	99792	Shashikant Teli	49/M	Missing +.	
15	99822	Unnati Choudhari	39/F	Decayed	
16	99786	Santosh Kalande	32/M	Decayed	
17	99802	Ramesh Sonawane	42/M	Decayed	
18	99803	Munida Ruhi	38/M	Mobility	
19	99793	Ganpat Kadam	81/M	Mobility	
20	99880	Khan Pawar	27/M	Decayed.	

B) Special cases

Sr No.	OPD No	Name of the Patient	Age/Sex	Diagnosis	Signature of Staff
1	98361	Shilpa Patil	31/F	Supernumerary Teeth	
2	98612	Vikas Sonawane	40/M	OSMF	

C) Radiographs (IOPA)

Sr No.	Date	OPD No	Name of the Patient	Number and types of Radiographs		Signature of Staff
1		99774	Govind Sawant	IOPA	2	
2		99810	Kiran Dubey	IOPA	2	
3		99763	Sohita Habib	IOPA	3	
4		99785	Sujata Kanade	IOPA	1	
5		99782	Pratiksha Pandgaonal	IOPA	4	
6		99778	Vishakha Thote	IOPA	2	
7		99807	Rajaram Pawale	IOPA	1	
8		99809	Priyanka Chougule	IOPA	1	
9		99790	Shriram Jadhav	IOPA	1	
10		99789	Shubhangi Jambre	IOPA	1	
11		99784	Pushpa Pasi	IOPA	2	
12		99803	Snehalata Shirap	IOPA	2	
13		99832	Rasika Rewale	IOPA	2	
14		99792	Shashikant Teli	IOPA	2	
15		99822	Umati Choudhari	IOPA	1	
16		99786	Santosh Kalande	IOPA	3	
17		99802	Ramesh Sonawane	IOPA	1	
18		99803	Manifa Ridli	IOPA	1	
19		99793	Ganpat Kadam	IOPA	1	
20		99820	Kunal Pawar	IOPA	1	

D) Extra-oral Radiographs

Sr No.	Date	OPD No	Name of the Patient	Projection		Signature of Staff
1	22/1/22	98038	Rangali Mankar	OPG		
2	23/1/22	97016	Harshita Jadhao	B	Cat Cephl	

D Y PATIL
DENTAL SCHOOL
(Affiliated to Maharashtra University of health Sciences, Nashik)
Dr D Y Patil Knowledge City, CharoliBudruk, via Lohegaon, Pune 412 105

INTERNSHIP PERFORMANCE DATA BOOK

Department of Oral Medicine and Radiology

Name of the Student: Adte Swaraj Gopal

Academic Year : 2021 - 22

Year of Admission : 2017

Year of Passing Final BDS : 2021

PROFESSOR & HEAD
Dept. Of Oral Medicine & Radiology
D Y Patil Dental School
D Y Patil Knowledge City
Charoli (BK), Via Lohegaon, Pune - 412105

D Y PATIL
DENTAL SCHOOL
(Affiliated to Maharashtra University of health Sciences, Nashik)
Dr D Y Patil Knowledge City, CharoliBudruk, via Lohegaon, Pune 412 105

Internship Completion Certificate

This is to certify that –

Mr. /~~Miss./Mrs.~~ Ashte Swaraj Gopal

Has satisfactorily completed the departmental work as per the DCI guidelines within his/her clinical posting.Further it is stated that during the clinical posting period, his /her clinical work and conduct was found to be satisfactory.

Head of the Department

Department of Oral Medicine and Radiology

PROFESSOR & HEAD
Dept. Of Oral Medicine & Radiology
D Y Patil Dental School
D Y Patil Knowledge City
Charoli (Bk), Via Lohegaon, Pune - 412105.

Oral Medicine & Radiology

- Standardized examination of patients 25
- Radiographs (IOPA) 25
- Special cases 5
- Extra oral Radiographs 1
- Cephalogram 1

Internship Programme Work Done

A) Standardized Examination of Patients with common Dental complaints

Sr No.	OPD No	Name of the Patient	Age/Sex	Diagnosis	Signature of Staff
1	99743	Vijaya Mokeel	40/F	Decayed teeth	
2	99777	Shailesh Sabpal	18/M	Malaligned	
3	99760	Rayjana Kali	31/F	Unclean teeth	
4	99770	Hemant Buller	30/M	Decayed teeth	
5	99769	Varsha Kadam	50/F	Decayed teeth	
6	99751	Pandy Malkar	25/M	Mobility	
7	99756	Vaibhav Thakur	30/M	Decayed t.	
8	99936	Arun Surale	18/M	Mobile	
9	99780	Kshitij Rao	38/F	Mobile	
10	99764	Yamini Kali	71/F	Decayed t.	
11	99797	Gayatri Shirap	17/F	Decay teeth	
12	99763	Bhushan Bhatkar	28/M	Unclean teeth	
13	99765	Mrunalini Koli	48/F	Missing teeth	
14	99736	Ankit Chavan	20/M	Decayed t.	
15	99766	Chetan Sande	18/M	Decayed t.	
16	99795	Hemant More	32/M	Decayed t.	
17	99761	Ankita Dube	16/F	Missing t.	
18	99755	Dharmendra Patil	35/M	Decayed t.	
19	99746	Pranali Mayekar	14/F	Missing t.	
20	99809	Ummye Kolu	21/M	Decayed t.	
21	99789	Priyanka Chonghde	31/F	Decayed t.	
22	99791	Mita Mayat	19/F	Mobility	
23	99765	Shalan Khanna	34/M	Decayed t.	
24	99741	Nilesh Pawar	25/M	Mobility	
25	99712	Narendra Bhat	46/M	Missing t.	

B) Special cases

Sr No.	OPD No	Name of the Patient	Age/Sex	Diagnosis	Signature of Staff
1	85839	Kishor Jagtap	52/M	Leukoplakia	
2	85935	Arvind Darkar	57/M	Leukoplakia	
3	86102	~~Dhiraj~~ Vetal Kasabe	22/M	~~Tb~~ Melanosis	
4	86548	Arbaaz Pathan	22/M	OSMF	
5	86554	Sagar Gaikwad	24/M	Leukoplakia	

C) Radiographs (IOPA)

Sr No.	Date	OPD No	Name of the Patient	Number and types of Radiographs		Signature of Staff
1	12/7/22	99743	Vijaya Mokal	IOPA	1	
2	12/7/22	99777	Shailesh Sakpal	IOPA	2	
3	13/7/22	99760	Ranjana Kali	IOPA	2	
4	13/7/22	99770	Hemant Buller	IOPA	1	
5	13/7/22	99769	Varsha Kadam	IOPA	1	
6	13/7/22	99751	Pandy Malkar	IOPA	3	
7	15/7/22	99756	Vaibhav Thakur	IOPA	1	
8	15/7/22	99736	Chun Surale	IOPA	1	
9	15/7/22	99797	Kshitij Rao	IOPA	2	
10	15/7/22	99763	Yamini Kali	IOPA	2	
11	16/7/22	99799	Gayatri Shirap	IOPA	2	
12	16/7/22	99736	Bhushan Bhatka	IOPA	1	
13	16/7/22	99766	Mrunalini Koli	IOPA	2	
14	17/7/22	99795	Ankur Chawan	IOPA	1	
15	17/7/22	99761	Chetan Sande	IOPA	1	
16	19/7/22	99755	Hemant More	IOPA	2	
17	19/7/22	99746	Ankita ~~Chawan~~ Pube	IOPA	1	
18	19/7/22	99809	Dharmender Patil	IOPA	3	
19	20/7/22	99789	Priyanka Chougale	IOPA	1	
20	20/7/22	99791	Mita Mayat	IOPA	1	
21	20/7/22	99765	Shalan Khanan	IOPA	2	
22	20/7/22	99741	Nilesh Pawar	IOPA	2	
23	20/7/22	99712	Narendra Bhal	IOPA	1	

D) Extra-oral Radiographs

Sr No.	Date	OPD No	Name of the Patient	Projection		Signature of Staff
1	27/5/22	95538	Rajesh Choudhary	OPG		
2	28/5/22	98016	Shahab Shaista		Lat Ceph	

D Y PATIL
DENTAL SCHOOL
(Affiliated to Maharashtra University of health Sciences, Nashik)
Dr D Y Patil Knowledge City, CharoliBudruk, via Lohegaon, Pune 412 105

INTERNSHIP PERFORMANCE DATA BOOK

Department of Oral Medicine and Radiology

Name of the Student: Ajmera Krishna

Academic Year : 2021 - 22

Year of Admission : 2017

Year of Passing Final BDS : 2021

D Y PATIL
DENTAL SCHOOL
(Affiliated to Maharashtra University of health Sciences, Nashik)
Dr D Y Patil Knowledge City, CharoliBudruk, via Lohegaon, Pune 412 105

Internship Completion Certificate

This is to certify that –

Mr. /~~Miss./Mrs.~~ Ajmera Krishna

Has satisfactorily completed the departmental work as per the DCI guidelines within his/her clinical posting.Further it is stated that during the clinical posting period, his /her clinical work and conduct was found to be satisfactory.

Head of the Department

Department of Oral Medicine and Radiology

PROFESSOR & HEAD
Dept. Of Oral Medicine & Radiology
D Y Patil Dental School
D Y Patil Knowledge City
Charoli (Bk), Via Lohegaon, Pune - 412105.

Oral Medicine & Radiology

- Standardized examination of patients 25
- Radiographs (IOPA) 25
- Special cases 5
- Extra oral Radiographs 1
- Cephalogram 1

Internship Programme Work Done

A) Standardized Examination of Patients with common Dental complaints

Sr No.	OPD No	Name of the Patient	Age/Sex	Diagnosis	Signature of Staff
1	99012	Mangal Zambade	45/F	Gingival hyperpl.	
2	99013	Rukhabai Bhore	64/F	Edentulous alveo	
3	99008	Bhavana Singh	79/F	Mobile teeth.	
4	98939	Shrikar Dabkiya	42/M	Unclean teeth	
5	98999	Pramod Joshi	57/M	Mobile teeth	
6	98994	Jivita Tiwari	44/F	Unclean teeth	
7	98948	Falguni Kini	35/F	Unclean teeth	
8	99016	Jeevan Magar	51/M	Localised perio.	
9	99023	Monika Patil	38/F	Unclean teeth.	
10	80084	Ujjwala Nighut	47/F	Dental caries	
11	98981	Lata Joshi	76/F	Mobile teeth	
12	98953	Ravikant Divati	32/M	Unclean teeth	
13	98979	Harsh Bidhe	58/M	Mobile teeth	
14	98943	Pravin Joshi	24/M	Unclean teeth	
15	99032	Savita Bhingarde	46/F	Multiple caries	
16	98950	Rajan Kini	87/M	Missing teeth	
17	98944	Subhash Chitale	64/M	Missing teeth	
18	98980	Hamati Mato	68/F	Mobility	
19	98965	Gajanan Treekar	83/M	Missing teeth	
20	98988	Vijay Gangar	70/M	Mobility	
21	98963	Dasdu Kushwar	58/M	Decayed teeth	
22	98971	Dinesh Mehta	50/F	Decayed teeth	
23	99033	Pallavi Kamble	35/F	Spacing	
24	98976	Mahendra Kumar	50/M	Unclean teeth	
25	98995	Tanmayee Kumar	18/F	Decayed teeth	

B) Special cases

Sr No.	OPD No	Name of the Patient	Age/Sex	Diagnosis	Signature of Staff

C) Radiographs (IOPA)

Sr No.	Date	OPD No	Name of the Patient	Number and types of Radiographs		Signature of Staff
1	13/4/22	92015	Megha Dhotre	IOPA	1	
2	13/4/22	92017	Vidyasagar Patil	IOPA	2	
3	13/4/22	92019	Hema Peshwani	IOPA	2	
4	13/4/22	92021	Avni Alhad	IOPA	1	
5	13/4/22	92037	Dayanand Vairagi	IOPA	3	
6	22/4/22	77687	Aishwarya Shinde	IOPA	1	
7	22/4/22	92549	Suputra Harirao	IOPA	2	
8	22/4/22	92548	Piyush Utthan	IOPA	1	
9	23/4/22	92477	Balkhan Thakur	IOPA	1	
10	23/4/22	92644	Siddharth Shelar	IOPA	1	
11	23/4/22	92642	Arvind Mhaske	IOPA	2	
12	23/4/22	92640	Sakshi Borse	IOPA	2	
13	25/4/22	92723	Akash Londhe	IOPA	2	
14	25/4/22	92736	Sunil Shinde	IOPA	3	
15	25/4/22	92753	Monika Wankhede	IOPA	1	
16	26/4/22	92133	Anuv Bhat	IOPA	2	
17	26/4/22	92849	Atharv Bhosale	IOPA	1	
18	26/4/22	92028	Avni Avhad	IOPA	1	
19	26/4/22	92851	Atharv Gaikwad	IOPA	2	
20	26/4/22	92854	Ajay Radhan	IOPA	2	
21	27/4/22	92966	Sanjay Upadhyay	IOPA	1	
22	27/4/22	92972	Shankar Kokare	IOPA	1	
23	27/4/22	92974	Aryan Bhise	IOPA	1	
24	29/4/22	7002	Rohan Ghodke	IOPA	1	

25	27/4/22	92976	Vinita Kumari	IOPA	2	

D) Extra-oral Radiographs

Sr No.	Date	OPD No	Name of the Patient	Projection	Signature of Staff
1.	13/4/22	98944	Kishor Kadam	Lateral Cephs	
2.	13/4/22	98945	Kiran Patil	OPG	

D Y PATIL
DENTAL SCHOOL
(Affiliated to Maharashtra University of health Sciences, Nashik)
Dr D Y Patil Knowledge City, CharoliBudruk, via Lohegaon, Pune 412 105

INTERNSHIP PERFORMANCE DATA BOOK

Department of Oral Medicine and Radiology

Name of the Student: Akshada Deshpande

Academic Year : 2021-22

Year of Admission : 2017

Year of Passing Final BDS : 2021

D Y PATIL
DENTAL SCHOOL
(Affiliated to Maharashtra University of health Sciences, Nashik)
Dr D Y Patil Knowledge City, CharoliBudruk, via Lohegaon, Pune 412 105

Internship Completion Certificate

This is to certify that –

Mr. /Miss./Mrs. Akshada Deshpande

Has satisfactorily completed the departmental work as per the DCI guidelines within his/her clinical posting.Further it is stated that during the clinical posting period, his /her clinical work and conduct was found to be satisfactory.

Head of the Department

Department of Oral Medicine and Radiology

PROFESSOR & HEAD
Dept. Of Oral Medicine & Radiology
D Y Patil Dental School
D Y Patil Knowledge City
Charoli (Bk), Via Lohegaon, Pune - 412105

Oral Medicine & Radiology

- Standardized examination of patients 25
- Radiographs (IOPA) 25
- Special cases 5
- Extra oral Radiographs 1
- Cephalogram 1

Internship Programme Work Done

A) Standardized Examination of Patients with common Dental complaints

Sr No.	OPD No	Name of the Patient	Age/Sex	Diagnosis	Signature of Staff
1	99867	Savita Ghule	51/F	Mobile	
2	99831	Sanjivi Mofite	35/F	Decayed	
3	99821	Shiv Prasad	25/M	Decayed	
4	99863	Pramod Patil	20/M	Decayed	
5	99873	Ritesh Pawar	41/M	Decayed	
6	99862	Sauli Kale	72/F	Mobile	
7	99872	Santosh Pandit	65/M	Missing	
8	99861	Suresh Pawar	51/M	Mobile	
9	99575	Mangala Pali	75/F	Missing	
10	99859	Archana More	18/F	Decayed	
11	99903	Ganpat Rishi	87/M	Missing	
12	99851	Shivanya Dalvi	19/F	Decayed	
13	99828	Dnyaneshwari M.	79/M	Mobile	
14	99879	Kalpesh Shinde	28/M	Decayed	
15	99772	Radhika More	28/M	Decayed	
16	99887	Sumit Khandare	78/F	Mobile	
17	99883	Rupesh Gosavi	16/M	Decayed	
18	99844	Subhash G.	29/M	Decayed	
19					
20					

B) Special cases

Sr No.	OPD No	Name of the Patient	Age/Sex	Diagnosis	Signature of Staff
1	92121	Abhishek Kumar	37/M	OSMF	
2	91931	Sitaram Rajapati	22/M	Fluorosis	
3	93074	Sohel Ansari	23/m	OSMF	

C) Radiographs (IOPA)

Sr No.	Date	OPD No	Name of the Patient	Number and types of Radiographs		Signature of Staff
1	2/5/22	99867	Savita Shinde	IOPA	11	
2	2/5	99831	Sanjivi Mohite	IOPA	2	
3	2/5	99821	Shiv Prasad	IOPA	2	
4	3/5	99863	Pramod Patil	IOPA	1	
5	3/5	99873	Ritesh Pawar	IOPA	1	
6	3/5	99862	Sunil Koli	IOPA	3	
7	4/5	99872	Santosh Pandit	IOPA	1	
8	4/5	99861	Suresh Panase	IOPA	1	
9	4/5	99575	Mangala Pali	IOPA	1	
10	4/5	99859	Archana More	IOPA	1	
11	4/5	99903	Ganpat Rishi	IOPA	4	
12	5/5	99851	Shivanya Dalvi	IOPA	2	
13	5/5	99828	Rautakri M.	IOPA	3	
14	5/5	99879	Kalpesh Shinde	IOPA	1	
15	6/5	99899	Radhika More	IOPA	1	
16	6/5	99722	Sumit Khandare	IOPA	1	
17	6/5	99887	Rupesh Ponare	IOPA	1	
18	7/5	99883	Subhash	IOPA	2	

D) Extra-oral Radiographs

Sr No.	Date	OPD No	Name of the Patient	Projection		Signature of Staff
1	5/5	99722	Radhika More	OPG		
2	6/5	99887	Amrit Khandare		Lat Ceph.	

D Y PATIL
DENTAL SCHOOL
(Affiliated to Maharashtra University of health Sciences, Nashik)
Dr D Y Patil Knowledge City, CharoliBudruk, via Lohegaon, Pune 412 105

INTERNSHIP PERFORMANCE DATA BOOK

Department of Oral Medicine and Radiology

Name of the Student: Ishwari Deshmukh

Academic Year : 2021-22

Year of Admission : 2017

Year of Passing Final BDS : 2021

D Y PATIL
DENTAL SCHOOL
(Affiliated to Maharashtra University of health Sciences, Nashik)
Dr D Y Patil Knowledge City, CharoliBudruk, via Lohegaon, Pune 412 105

Internship Completion Certificate

This is to certify that –

Mr. /Miss./Mrs. Pawari Deshmukh

Has satisfactorily completed the departmental work as per the DCI guidelines within his/her clinical posting.Further it is stated that during the clinical posting period, his /her clinical work and conduct was found to be satisfactory.

Head of the Department

Department of Oral Medicine and Radiology

PROFESSOR & HEAD
Dept. Of Oral Medicine & Radiology
D Y Patil Dental School
D Y Patil Knowledge City
Charoli (Bk), Via Lohegaon, Pune - 412105.

Oral Medicine & Radiology

- Standardized examination of patients 25
- Radiographs (IOPA) 25
- Special cases 5
- Extra oral Radiographs 1
- Cephalogram 1

Internship Programme Work Done

A) Standardized Examination of Patients with common Dental complaints

Sr No.	OPD No	Name of the Patient	Age/Sex	Diagnosis	Signature of Staff
1	99774	Govind Sawant	39/M	Mobility	
2	99810	Kumar Dubey	45/M	Decayed	
3	99783	Sohita Tabib	58/F	Mobility	
4	99785	Sujata Tamade	68/F	Mobile	
5	99782	Pratiksha Dandgaval	48/F	Decayed	
6	99778	Vishakha Thote	30/F	Decayed	
7	99807	Rajaram Pawale	75/M	Missing	
8	99809	Bijlamba Chougule	31/F	Decayed	
9	99790	Shriram Jadhav	60/M	Mobility	
10	99789	Shubhangi Tambe	75/F	Mobile	
11	99784	Pushpa Pasi	35/F	Decayed	
12	99803	Sneelalata Shirap	73/F	Missing	
13	99832	Rubika Rende	58/F	Decayed	
14	99792	Shashikant Tele	49/M	Decayed	
15	99822	Umrati Choudhari	39/F	Decayed	
16	99786	Santosh Kalande	32/F	Missing	
17	99802	Ramesh Sonawane	42/M	Decayed	
18	99805	Manila Ruhi	38/F	Missing	
19	99793	Jayant Kadam	51/M	Decayed	
20	99820	Kiran Pawar	27/M	Fractured	

B) Special cases

Sr No.	OPD No	Name of the Patient	Age/Sex	Diagnosis	Signature of Staff
1	98361	Shilpa Patil	31/F	Sup. teeth	
2	98612	Vikas Sonawane	40/M	OSMF	

C) Radiographs (IOPA)

Sr No.	Date	OPD No	Name of the Patient	Number and types of Radiographs		Signature of Staff
1	2/5/22	99774	Govind Sawant	IOPA	2	
2	2/5	99810	Kunal Dubey	IOPA	2	
3	2/5	99783	Sohita Tabid	IOPA	3	
4	3/5	99485	Sujata Kamade	IOPA	1	
5	3/5	99778	Ratiksha Dandgaval	IOPA	1	
6	3/5	99807	Vishakha Thote	IOPA	1	
7	3/5	99809	Rajaram Pawale	IOPA	1	
8	4/5	99790	Priyanka Chougule	IOPA	2	
9	4/5	99789	Shivram Jadhav	IOPA	1	
10	4/5	99784	Shubhangi Tambe	IOPA	1	
11	6/5	99803	Pushpa Pasi	IOPA	2	
12	6/5	99832	Shahalat Shirap	IOPA	1	
13	6/5	99792	Rasika Ramul	IOPA	2	
14	7/5	99822	Shashikant Teli	IOPA	3	
15	7/5	99786	Umrati Choudhari	IOPA	1	
16	9/5	99802	Santosh Kalande	IOPA	2	
17	9/5	99803	Ramesh Sonaw.	IOPA	1	
18	9/5	99793	Munija Rathi	IOPA	1	
19	9/5	99820	Gangaram Kadam	IOPA	1	
20	11/5	99821	Kiran Pawar	IOPA	1	

D) Extra-oral Radiographs

Sr No.	Date	OPD No	Name of the Patient	Projection		Signature of Staff
1	4/5	98038	Prajjali Mankar	OPG		
2	4/5	97016	Harshita Jadhav		Lat Ceph	

D Y PATIL
DENTAL SCHOOL
(Affiliated to Maharashtra University of health Sciences, Nashik)
Dr D Y Patil Knowledge City, CharoliBudruk, via Lohegaon, Pune 412 105

INTERNSHIP PERFORMANCE DATA BOOK

Department of Oral Medicine and Radiology

Name of the Student: Snehal Dhaigude

Academic Year : 2021 - 22

Year of Admission : 2017

Year of Passing Final BDS : 2021

D Y PATIL
DENTAL SCHOOL
(Affiliated to Maharashtra University of health Sciences, Nashik)
Dr D Y Patil Knowledge City, CharoliBudruk, via Lohegaon, Pune 412 105

Internship Completion Certificate

This is to certify that –

Mr. /Miss./Mrs. Snehal Dhaigude

Has satisfactorily completed the departmental work as per the DCI guidelines within his/her clinical posting.Further it is stated that during the clinical posting period, his /her clinical work and conduct was found to be satisfactory.

Head of the Department

Department of Oral Medicine and Radiology

PROFESSOR & HEAD
Dept. Of Oral Medicine & Radiology
D Y Patil Dental School
D Y Patil Knowledge City
Charoli (Bk), Via Lonegaon, Pune - 412105.

Oral Medicine & Radiology

- Standardized examination of patients 25
- Radiographs (IOPA) 25
- Special cases 5
- Extra oral Radiographs 1
- Cephalogram 1

Internship Programme Work Done

A) Standardized Examination of Patients with common Dental complaints

Sr No.	OPD No	Name of the Patient	Age/Sex	Diagnosis	Signature of Staff
1	101121	Ravindra Sawant	46/M	Missing	
2	101111	Shivram Govind	62/M	Mobile	
3	101145	Priti Mishra	35/F	Decayed	
4	101139	Amit Rajbhoj	32/M	Caries	
5	101152	Brija Alikam	30/F	Missing	
6	101144	Vasant Patnam	73/M	Mobility	
7	101153	Visual Prathi	43/M	Caries	
8	101130	Deepali Parik	61/F	Mobile	
9	101149	Sunil Rana	40/M	Missing	
10	101135	Prashant Tondare	16/M	Decayed	
11	101156	Ambar Pawar	25/M	Mobile	
12	101137	Manali Tanpt	16/F	Missing	
13	101136	Rishi Shankar	24/M	Decayed	
14	101168	Aniket Jha	24/M	Decayed	
15	101125	Ritvik Sharma	25/M	Decayed	
16	101139	Sainayan Jha	25/M	Mobile	
17	101131	Priyanka S.	20/F	Decayed	
18	101170	Akash Kadam	35/M	Caries	
19	101191	Prasad Dhate	24/M	Decayed	
20	101127	Rutuja Kubde	21/M	Mobile	

B) Special cases

Sr No.	OPD No	Name of the Patient	Age/Sex	Diagnosis	Signature of Staff
1)	101720	Jyanoba Mhaske	60/M	Leukoplakia	
2)	102635	Girish Mukute	35/M	Aphthous ulcer	
			58/F	Keratosis	
3)	102680	Ratan			

C) Radiographs (IOPA)

Sr No.	Date	OPD No	Name of the Patient	Number and types of Radiographs		Signature of Staff
1	2/5/22	101121	Ravindra Sawant	IOPA	1	
2	2/5	101145	Shivam Govind	IOPA	2	
3	2/5	101145	Briti Mishra	IOPA	1	
4	3/5	10139	Amit Rajbhoj	IOPA	1	
5	3/5	110052	Briya Adikari	IOPA	2	
6	3/5	101164	Vasant Patwari	IOPA	1	
7	3/5	101130	Vishal Bhatni	IOPA	1	
8	4/5	101140	Deepak Parish	IOPA	1	
9	4/5	101158	Jairaj Rana	IOPA	1	
10	4/5	101136	Jyashant Tondare	IOPA	5	
11	4/5	101167	Ankur Pawar	IOPA	1	
12	5/5	101131	Manali Jitkar	IOPA	1	
13	5/5	101171	Rishi Shankar	IOPA	2	
14	5/5	101191	Anibet Jha	IOPA	1	
15	6/5	101129	Ritvik Sharma	IOPA	1	
16	6/5	101153	Jainayan Jha	IOPA	2	
17	6/5	101134	Priyanka S.	IOPA	1	
18	7/5	101148	Akash Kadam	IOPA	1	
19	7/5	101145	Prasad Dhote	IOPA	1	
20	7/5	101144	Ritika Kulde	IOPA	1	

D) Extra-oral Radiographs

Sr No.	Date	OPD No	Name of the Patient	Projection		Signature of Staff
1	2/5	101121	Ravindra Sawant	OPG		
2	2/5	101121	Ravindra Sawant		Lat Ceph.	

D Y PATIL
DENTAL SCHOOL
(Affiliated to Maharashtra University of health Sciences, Nashik)
Dr D Y Patil Knowledge City, CharoliBudruk, via Lohegaon, Pune 412 105

INTERNSHIP PERFORMANCE DATA BOOK

Department of Oral Medicine and Radiology

Name of the Student: Prashant Bhagse

Academic Year : 2021-22

Year of Admission : 2017

Year of Passing Final BDS : 2021

D Y PATIL
DENTAL SCHOOL
(Affiliated to Maharashtra University of health Sciences, Nashik)
Dr D Y Patil Knowledge City, CharoliBudruk, via Lohegaon, Pune 412 105

Internship Completion Certificate

This is to certify that –

Mr. ~~Miss./Mrs.~~ Prashant Bhagat

Has satisfactorily completed the departmental work as per the DCI guidelines within his/her clinical posting.Further it is stated that during the clinical posting period, his /her clinical work and conduct was found to be satisfactory.

Head of the Department

Department of Oral Medicine and Radiology

PROFESSOR & HEAD
Dept. Of Oral Medicine & Radiology
D Y Patil Dental School
D Y Patil Knowledge City
Charoli (Bk), Via Lohegaon, Pune - 412105.

Oral Medicine & Radiology

- Standardized examination of patients 25
- Radiographs (IOPA) 25
- Special cases 5
- Extra oral Radiographs 1
- Cephalogram 1

Internship Programme Work Done

A) Standardized Examination of Patients with common Dental complaints

Sr No.	OPD No	Name of the Patient	Age/Sex	Diagnosis	Signature of Staff
1	99867	Sarika Ighule	51/F	Missing T.	
2	99831	Sanjivi Mohite	35/F	Decayed teeth	
3	99821	Shiv Prasad	25/M	Decayed teeth	
4	99863	Pramod Patil	20/M	Mobility	
5	99873	Ritesh Pawar	41/M	Ap. pain.	
6	99862	Sauli Kale	72/F	Decayed T.	
7	99872	Santosh Pandit	65/M	Decayed T.	
8	99861	Suresh Pangare	51/M	Missing T.	
9	99575	Mangala Pali	75/F	Decayed T.	
10	99859	Archana More	18/F	Missing T.	
11	99903	Archana More	18/F	Decayed T.	
12	99851	Jaya Rishi	87/M	Decayed T.	
13	99828	Shivanya Dalvi	19/F	Missing T.	
14	99879	Rantestri Maurya	79/M	Missing T.	
15	99849	Kalpesh Shinde	28/M	Decayed T.	
16	99722	Radhika More	78/F	Mobile T.	
17	99887	Sumit Khankare	16/M	Decayed T.	
18	99883	Rupesh Gonare	29/M	Decayed T	
19	99844	Subhash Gupta	62/M	Mobility	

B) Special cases

Sr No.	OPD No	Name of the Patient	Age/Sex	Diagnosis	Signature of Staff
1	92121	Abhishek Kumar	37/M	OSMF	
2	91931	Sitaram Rajapati	22/M	Fluorosis	
3	93074	Sohel Ansari	23/M	OSMF	

C) Radiographs (IOPA)

Sr No.	Date	OPD No	Name of the Patient	Number and types of Radiographs		Signature of Staff
1	13/7/22	99867	Savita Ghule	IOPA		
2	13/7	99831	Sanjivi Mohite	IOPA		
3	13/7	99821	Shiv Prasad	IOPA		
4	14/7	99863	Pramod Patil	IOPA		
5	14/7	99873	Ritesh Pawar	IOPA		
6	14/7	99862	Sunil Kole	IOPA		
7	15/7	99872	Santosh Pandit	IOPA		
8	15/7	99861	Suresh Panase	IOPA		
9	15/7	99575	Mangala Pali	IOPA		
10	15/7	99859	Archana More	IOPA		
11	16/7	99903	Yaspal Rishi	IOPA		
12	16/7	99851	Shivanya Palvi	IOPA		
13	17/7	99828	Rantoshri Mauge	IOPA		
14	17/7	99879	Kalpesh Shinde	IOPA		
15	17/7	99899	Radhika More	IOPA		
16	17/7	99722	Sumit Khandave	IOPA		
17	20/7	99887	Rupesh Gonare	IOPA		
18	20/7	99883	Subhash —	IOPA		
19	20/7	99844	Sarika Ghule	IOPA		

D) Extra-oral Radiographs

Sr No.	Date	OPD No	Name of the Patient	Projection		Signature of Staff
1	17/7	99722	Radhika More	OPG		
2	17/7	99857	Sumit Khandewa		Lat Ceph	

Record Book Details

Internship

Department of Oral and Maxillofacial Surgery

DYPDS, PUNE

Department of Oral and Maxillofacial Surgery

INTERNS LOGBOOK

NAME: PRITI KADAM

ROLL NO.: 5

YEAR: 2018-19

DEPARTMENT OF ORAL

AND

MAXILLOFACIAL SURGERY

This is to certify that Intern Roll no. -5 Named Mr./Miss PRITIKADAM

has satisfactorily completed the work of this department as per the D.C.I guidelines . I hereby give him / her the Certification of completion of Internship programme for this department.

Date 20/09/2019

SIGNATURE

HEAD OF THE DEPARTMENT

ORAL AND MAXILLOFACIAL URGERY

PROFESSOR & HEAD
Dept. of Oral & Maxillofacial Surgery
D Y Patil Dental School
D Y Patil Knowledge City
Charoli (Bk), Via Lohegaon, Pune - 41210

Name of Procedures	No. of Procedures
Total Extractions	115
Minor Surgery	06
Assisted Surgery	35
G.A. Cases(Major surgery)	-
Seminars	1
Projects	ARMAMENTARIUM
Present days	43
Absent days	2
C.L / L.W.P	2
H.O.D Sign	for Kapila

CLINICAL EXERCISES TO BE PERFORMED DURING

INTERNSHIP PROGRAMME

(A)

1. Simple Extractions,
2. Surgical Extraction,
3. Dis-impactions,Surgical Extractions of Third molar,
4. Inter- maxillary Fixation + Inter- Dental wiring
5. Cyst enucleation
6. Alveoloplasty, Biopsies, Frenectomies

The interns shall have 15 days posting in emergency services of Dental/ General Hospital with extended responsibilities in Emergency Dental Care in wards. During this period they shall attend all emergencies under the direct supervision of Oral Surgeon during any operation.

1. EMERGENCIES:

1. Toothache
2. Trigeminal Neuralgia
3. Bleeding from mouth due to trauma, post – extraction, Bleeding disoders.
4. Airway obstruction due to fractured mandible and maxilla, dislocation of mandible, syncope or vasovagal attacks, Ludwig's Angina,Tooth fracture, Poat inter- maxillary fixation after general anesthesia.

Sr No.	Date	Case No.	Name of Patients	Treatment	Sign
1	23/06/18	15954	SWAPNALI JADHAV	EXTRACTION 11 12	
2	25/06/18	12762	SAYALI JOSHI	EXTRACTION 46	
3	26/06/18	15624	SHIVAM KARDURE	EXTRACTION 38	
4	02/07/18	20147	SAYALI SALUNKE	EXTRACTION 18	
5	09/07/18	17425	KIRAN MULJE	EXTRACTION 47	
6	11/07/18	13564	ADITYA PATIL	EXTRACTION 15 25	
7	15/07/18	12456	MANJIRI KULKARNI	EXTRACTION 45	
8	21/07/18	15426	VAISHNAVI KHER	EXTRACTION 35	
9	27/07/18	13648	SAKSHI AGRE	EXTRACTION 36	
10	30/07/18	12584	SWAPNALI GAME	EXTRACTION 27	
11	01/08/18	14352	DHIRAJ KAMBLE	EXTRACTION 31	
12	03/08/18	16245	YOGITA SONTAKKE	EXTRACTION 46	
13	10/08/18	12635	PRATHMESH CHAVAN	EXTRACTION18	
14	20/08/18	14256	PALLAVI GAIKWAD	EXTRACTION 28	
15	25/08/18	13562	ARIF SHAIKH	EXTRACTION 24	
16	09/09/18	13958	AKANKSHA PATIL	EXTRACTION 25	
17	11/09/18	16420	SHAMIM QURESHI	EXTRACTION 37	
18	26/09/18	10624	AVINASH BHOSALE	EXTRACTION47	
19	30/09/18	13254	ROHAN PAWAR	EXTRACTION 21	
20	13/10/18	12581	CHANNAVIR KORE	EXTRACTION 24	
21	01/11/18	12312	PRATIKSHA BIRAJDAR	EXTRACTION22	
22	03/11/18	20145	AMOL BURNAPALLE	EXTRACTION46	
23	07/11/18	20135	BHAVNA CHAUDHARY	EXTRACTION38	
24	23/11/18	20365	ISAK SHAIKH	EXTRACTION 35	
25	05/12/18	19526	SUNDAR JADHAV	EXTRACTION 15	
26	13/12/18	18632	OMKAR MALI	EXTRACTION 24	
27	19/12/18	19354	SHRUTI SHEWALE	EXTRACTION 24 14	
28	28/12/18	12654	PURVA PUDALE	EXTRACTION 16	
29	04/01/19	13264	SANIKA SHIPALKAR	EXTRACTION 28	

30	12/01/19	15874	RADHIKA KALE	EXTRACTION 36	

DYPDS, PUNE

Department of Oral and Maxillofacial Surgery

INTERNS LOGBOOK

NAME: VARUNA PILLAY

ROLL NO.: 18

YEAR: 2018-19

DEPARTMENT OF ORAL AND MAXILLOFACIAL SURGERY

This is to certify that Intern Roll no. - 18

Named Mr./Miss VARUNA PILLAY
has satisfactorily completed the work of this department as per the D.C.I guidelines . I hereby give him / her the Certification of completion of Internship programme for this department.

Date 16/09/19

SIGNATURE
HEAD OF DEPARTMENT
ORAL AND MAXILLOFACIAL SURGERY

PROFESSOR & HEAD
Dept. of Oral & Maxillofacial Surgery
D Y Patil Dental School
D Y Patil Knowledge City
Charoli (Bk), Via Lohegaon, Pune - 41210

Name of Procedures	No. of Procedures
Total Extractions	83
Minor Surgery	05
Assisted Surgery	32
G.A. Cases(Major surgery)	-
Seminars	2
Projects	ARMAMENTARIUM
Present days	44
Absent days	01
C.L / L.W.P	01 C.L
H.O.D Sign	

CLINICAL EXERCISES TO BE PERFORMED DURING

INTERNSHIP PROGRAMME

(A)

1. Simple Extractions,
2. Surgical Extraction,
3. Dis-impactions,Surgical Extractions of Third molar,
4. Inter- maxillary Fixation + Inter- Dental wiring
5. Cyst enucleation
6. Alveoloplasty, Biopsies, Frenectomies

The interns shall have 15 days posting in emergency services of Dental/ General Hospital with extended responsibilities in Emergency Dental Care in wards. During this period they shall attend all emergencies under the direct supervision of Oral Surgeon during any operation.

1.EMERGENCIES:

1. Toothache
2. Trigeminal Neuralgia
3. Bleeding from mouth due to trauma, post – extraction, Bleeding disoders.
4. Airway obstruction due to fractured mandible and maxilla, dislocation of mandible, syncope or vasovagal attacks, Ludwig's Angina,Tooth fracture, Poat inter- maxillary fixation after general anesthesia.

Sr No.	Date	Case No.	Name of Patients	Treatment	Sign
1	21/06/18	16754	RADHIKA WANDRE	EXTRACTION 16 12	
2	24/06/18	14767	DEVYANI PATIL	EXTRACTION 44	
3	27/06/18	12124	SHIVAM DUBE	EXTRACTION 28	
4	05/07/18	17647	NIKITA SALUNKE	EXTRACTION 18	
5	08/07/18	18725	KIRAN YADAV	EXTRACTION 47	
6	13/07/18	14564	SHIRISH LALANI	EXTRACTION 15 25	
7	18/07/18	12456	ALISHA GAME	EXTRACTION 45	
8	20/07/18	15426	ANUSHKA HOLE	EXTRACTION 35	
9	26/07/18	13448	SWAPNALI SHEKH	EXTRACTION 36	
10	31/07/18	15324	AARTI GAIKWAD	EXTRACTION 27	
11	04/08/18	18652	ADITI PAWAR	EXTRACTION 31	
12	07/08/18	12445	ANUJA GHODKE	EXTRACTION 46	
13	16/08/18	16235	TANVI DEVKATE	EXTRACTION18	
14	22/08/18	14526	ROHIT GARDE	EXTRACTION 28	
15	29/08/18	15362	YUTHIKHA JAIN	EXTRACTION 24	
16	06/09/18	19358	SANIYA SALVE	EXTRACTION 25	
17	13/09/18	14620	RUTIKA KUBDE	EXTRACTION 37	
18	25/09/18	12664	SUJATA AYRADE	EXTRACTION47	
19	29/09/18	12354	PRAGATI DESHMUKH	EXTRACTION 21	
20	11/10/18	15281	POOJA TELANG	EXTRACTION 24	
21	02/11/18	13212	SAKSHI PANCHAL	EXTRACTION22	
22	06/11/18	16245	ADITI MURBE	EXTRACTION46	

23	10/11/18	16535	DHYAN GURAV	EXTRACTION38	
24	19/11/18	20255	AMIT JADHAV	EXTRACTION 35	
25	06/12/18	18246	GAYATRI SALUNKHE	EXTRACTION 15	
26	17/12/18	18632	UDAY THAKUR	EXTRACTION 24	
27	22/12/18	19154	DEVIKA SWAMI	EXTRACTION 24 14	
28	29/12/18	13654	PRIYANKA PUDALE	EXTRACTION 16	
29	07/01/19	19324	SANIKA CHOUDHARI	EXTRACTION 28	
30	13/01/19	16734	SUJATA MANE	EXTRACTION 36	

DYPDS, PUNE

Department of Oral and Maxillofacial Surgery

INTERNS LOGBOOK

NAME: Akshay Chavan

ROLL NO.: 8

YEAR: 2019-2020

DEPARTMENT OF ORAL AND MAXILLOFACIAL SURGERY

This is to certify that Intern Roll no. - 8 Named Mr./Miss Akshay Chavan has satisfactorily completed the work of this department as per the D.C.I guidelines . I hereby give him / her the Certification of completion of Internship programme for this department.

Date 19/9/2020

SIGNATURE

HEAD OF THE DEPARTMENT

ORAL AND MAXILLOFACIAL SURGERY

PROFESSOR & HEAD
Dept. of Oral & Maxillofacial Surgery
D Y Patil Dental School
D Y Patil Knowledge City
Charoli (Bk), Via Lohegaon, Pune - 41210

Name of Procedures	No. of Procedures
Total Extractions	*152*
Minor Surgery	*02*
Assisted Surgery	*25*
G.A. Cases(Major surgery)	*--*
Seminars	*--*
Projects	*Armamentarium*
Present days	*44*
Absent days	*1*
C.L / L.W.P	*1*
H.O.D Sign	

CLINICAL EXERCISES TO BE PERFORMED DURING INTERNSHIP PROGRAMME

(A)

1. Simple Extractions,
2. Surgical Extraction,
3. Dis-impactions,Surgical Extractions of Third molar,
4. Inter- maxillary Fixation + Inter- Dental wiring
5. Cyst enucleation
6. Alveoloplasty, Biopsies, Frenectomies

The interns shall have 15 days posting in emergency services of Dental/ General Hospital with extended responsibilities in Emergency Dental Care in wards. During this period they shall attend all emergencies under the direct supervision of Oral Surgeon during any operation.

1. EMERGENCIES:

1. Toothache
2. Trigeminal Neuralgia
3. Bleeding from mouth due to trauma, post – extraction, Bleeding disoders.
4. Airway obstruction due to fractured mandible and maxilla, dislocation of mandible, syncope or vasovagal attacks, Ludwig's Angina,Tooth fracture, Poat inter- maxillary fixation after general anesthesia.

Sr No.	Date	Case No.	Name of Patients	Treatment	Sign
1	27/06	28062	Jayaram	Extraction 31	
2	27/06	27101	Balwant	Extraction 46	Kapila
3	27/06	21545	Tukaram	Extraction 24	
4	29/06	21566	Yogita	Extraction 37	
5	29/06	28454	Meerabai	Extraction 36	Kapila
6	29/06	26487	Sunita	Extraction 14	
7	29/06	25985	Bhavesh	Extraction 45	
8	01/07	24563	Abhay	Extraction 23	Kapila
9	01/07	21452	Vasanti	Extraction 15	Kapila
10	01/07	75411	Bharat	Extraction 36	
11	01/07	46956	Devyani	Extraction 25	
12	01/07	15639	Sheela	Extraction 16	Kapila
13	01/07	45898	Anita	Extraction 25	
14	01/07	78564	Seema	Extraction 26	
15	01/07	45633	Unnati	Extraction 35	
16	03/07	25475	Sushma	Extraction 26	
17	03/07	25894	Deepali	Extraction 46	
18	03/07	21456	Rajendra	Extraction 45	Kapila
19	03/07	21561	Satish	Extraction 35	
20	03/07	25475	Deepak	Extraction 45	
21	03/07	23568	Rajani	Extraction 45	

22	05/07	26587	Nirmala	Extraction 46	
23	05/07	29874	Pramilabai	Extraction 46	
24	05/07	24683	Purushottam	Extraction 36	
25	05/07	25876	Bhalachandra	Extraction 35	
26	05/07	44584	Nilam	Extraction 26	
27	05/07	411189	Priya	Extraction 15	
28	05/07	14755	Ganesh	Extraction 16	
29	05/07	74122	Preeti	Extraction 15	
30	05/07	14563	Vaishnavi	Extraction 15	

DYPDS, PUNE

Department of Oral and Maxillofacial Surgery

INTERNS LOGBOOK

NAME: VAISHNAVI CHAUDHARY

ROLL NO.: 10

YEAR: 2019-20

DEPARTMENT OF ORAL AND MAXILLOFACIAL SURGERY

This is to certify that Intern Roll no.-10

Named Mr./Miss VAISHNAVI CHAUDHARY

has satisfactorily completed the work of this department as per the D.C.I guidelines . I hereby give him / her the Certification of completion of Internship programme for this department.

Date 15/9/2020

SIGNATURE

HEAD OF THE DEPARTMENT

ORAL AND MAXILLOFACIAL SURGERY

PROFESSOR & HEAD
Dept. of Oral & Maxillofacial Surgery
D Y Patil Dental School
D Y Patil Knowledge City
Charoli (Bk), Via Lohegaon, Pune - 41210

Name of Procedures	No. of Procedures
Total Extractions	176
Minor Surgery	08
Assisted Surgery	38
G.A. Cases(Major surgery)	-
Seminars	2
Projects	ARMAMENTARIUM
Present days	45
Absent days	0
C.L / L.W.P	0

H.O.D Sign	for Kapil

CLINICAL EXERCISES TO BE PERFORMED DURING INTERNSHIP PROGRAMME

(A)

1. Simple Extractions,
2. Surgical Extraction,
3. Dis-impactions,Surgical Extractions of Third molar,
4. Inter- maxillary Fixation + Inter- Dental wiring
5. Cyst enucleation
6. Alveoloplasty, Biopsies, Frenectomies

The interns shall have 15 days posting in emergency services of Dental/ General Hospital with extended responsibilities in Emergency Dental Care in wards. During this period they shall attend all emergencies under the direct supervision of Oral Surgeon during any operation.

1.EMERGENCIES:

1. Toothache
2. Trigeminal Neuralgia
3. Bleeding from mouth due to trauma, post – extraction, Bleeding disoders.
4. Airway obstruction due to fractured mandible and maxilla, dislocation of mandible, syncope or vasovagal attacks, Ludwig's Angina,Tooth fracture, Poat inter- maxillary fixation after general anesthesia.

Sr No.	Date	Case No.	Name of Patients	Treatment	Sign
1	21/06/19	16756	YOGESH GOCHADE	EXTRACTION 16 12	
2	24/06/19	14786	SACHIN GOSAVI	EXTRACTION 44	
3	27/06/19	12190	GOVIND DABKE	EXTRACTION 28	
4	05/07/19	17645	NIKITA BHOJNE	EXTRACTION 18	
5	08/07/19	18702	MAITHILI BANSODE	EXTRACTION 47	
6	13/07/19	14523	ABHISHEK TALE	EXTRACTION 15 25	
7	18/07/19	12497	DEVLI HOLKAR	EXTRACTION 45	
8	20/07/19	15423	BHAKTI SWAMI	EXTRACTION 35	
9	26/07/19	13495	PRANAV KAKDE	EXTRACTION 36	
10	31/07/19	15367	SUNIL MADDE	EXTRACTION 27	
11	04/08/19	18634	LIMBAJI MANGRULE	EXTRACTION 36	
12	07/08/19	12477	SHRUTI SONTAKKE	EXTRACTION 46	
13	16/08/19	16255	BAJRANG BIRADAR	EXTRACTION16	
14	22/08/19	14589	AMAR TAGARKHEDE	EXTRACTION 28	
15	29/08/19	15321	ISHITA AGARWAL	EXTRACTION 23	
16	06/09/19	19367	AROHI KALE	EXTRACTION 25	
17	13/09/19	14699	NINAD MASKE	EXTRACTION 37	
18	25/09/19	12632	SURAJ KHADKE	EXTRACTION47	
19	29/09/19	12364	SHUBHAM YADAV	EXTRACTION 21	
20	11/10/19	15285	ASHISH BAGAL	EXTRACTION 24	
21	02/11/19	13263	KRUSHNA SALUNKE	EXTRACTION22	
22	06/11/19	16247	SUMIT SHINDE	EXTRACTION41	

23	10/11/19	16558	SURAJ BHADADE	EXTRACTION38	
24	19/11/19	20236	TANVI CHAVAN	EXTRACTION 35	
25	06/12/19	18278	SANIYA SURVASE	EXTRACTION 15	
26	17/12/19	18656	AMOL GAIKWAD	EXTRACTION 24	
27	22/12/19	19122	DIPAK PHADNIS	EXTRACTION 27 14	
28	29/12/19	13696	SAKSHANT PITLE	EXTRACTION 16	
29	07/01/20	19326	SAMADHAN PAWAR	EXTRACTION 28	
30	13/01/20	16734	UMESH SHINDE	EXTRACTION 37	

DYPDS

PUNE

Department of Oral and Maxillofacial Surgery

INTERNS LOGBOOK

NAME: Shraddha Patil

ROLL NO.: 46

YEAR:2020-21

DEPARTMENT OF ORAL

AND

MAXILLOFACIAL SURGERY

This is to certify that Intern Roll no.-46
Named Mr./Miss Shraddha Patil

has satisfactorily completed the work of this department as per the D.C.I guidelines . I hereby give him / her the Certification of completion of Internship programme for this department.

Date 18/09/2021

SIGNATURE

HEAD OF THE DEPARTMENT

ORAL AND MAXILLOFACIAL SURGERY

PROFESSOR & HEAD
Dept. of Oral & Maxillofacial Surgery
D Y Patil Dental School
D Y Patil Knowledge City
Charoli (Bk), Via Lohegaon, Pune - 41210

Name of Procedures	No. of Procedures
Total Extractions	*102*
Minor Surgery	*08*
Assisted Surgery	*37*
G.A. Cases(Major surgery)	*-*
Seminars	*2*
Projects	*Armentarium*
Present days	*44*
Absent days	*1*
C.L / L.W.P	*1*
H.O.D Sign	

CLINICAL EXERCISES TO BE PERFORMED DURING INTERNSHIP PROGRAMME

(A)

1. Simple Extractions,
2. Surgical Extraction,
3. Dis-impactions,Surgical Extractions of Third molar,
4. Inter- maxillary Fixation + Inter- Dental wiring
5. Cyst enucleation
6. Alveoloplasty, Biopsies, Frenectomies

The interns shall have 15 days posting in emergency services of Dental/ General Hospital with extended responsibilities in Emergency Dental Care in wards. During this period they shall attend all emergencies under the direct supervision of Oral Surgeon during any operation.

1. EMERGENCIES:

1. Toothache
2. Trigeminal Neuralgia
3. Bleeding from mouth due to trauma, post – extraction, Bleeding disoders.
4. Airway obstruction due to fractured mandible and maxilla, dislocation of mandible, syncope or vasovagal attacks, Ludwig's Angina,Tooth fracture, Poat inter- maxillary fixation after general anesthesia.

Sr No.	Date	Case No.	Name of Patients	Treatment	Sign
1	3/01	25984	Sweta	Extraction16	
2	3/01	45686	Sweety	Extraction37	
3	4/01	54588	Tapaswini	Extraction35	
4	5/01	57488	Priya	Extraction44	
5	7/01	47828	Reshma	Extraction45	
6	7/01	74574	Ayan	Extraction11	
7	8/01	57448	Sabyasachi	Extraction24	
8	9/01	48748	Debolina	Extraction37	
9	11/01	84874	Rajaram	Extraction32	
10	12/01	65248	Suman	Extraction31	
11	12/01	48578	Shahaji	Extraction46	
12	13/0	7788	Pradeep	Extraction2	

	1	4		5	
13	14/01	26546	Sourabh	Extraction14	
14	15/01	25484	Kiran	Extraction35	
15	17/01	45484	Jaydeep	Extraction47	
16	17/01	47451	Tejas	Extraction22	
17	17/01	48874	Sitaram	Extraction16	
18	20/01	48758	Jayshree	Extraction36	
19	20/01	45856	Shravan	Extraction47	
20	20/01	15466	Manoj	Extraction45	
21	21/01	55487	Rohit	Extraction25	
22	21/01	54878	Kamlabai	Extraction45	
23	22/01	54854	Pandurang	Extraction25	
24	22/01	48887	Kajal	Extraction36	
25	24/01	54788	Shital	Extraction45	

26	24/01	74155	Atif	Extraction14	
27	26/01	24544	Ashutosh	Extraction33	
28	28/01	66544	Kedar	Extraction45	
29	28/01	15487	Chetan	Extraction27	
30	29/01	45488	Jagdeep	Extraction45	

DYPDS

PUNE

Department of Oral and Maxillofacial Surgery

INTERNS LOGBOOK

NAME: Mansi Suryavanshi

ROLL NO.: 59

YEAR:2020-21

DEPARTMENT OF ORAL AND MAXILLOFACIAL SURGERY

This is to certify that Intern Roll no.-59
Named Mr./Miss Mansi Suryavanshi

has satisfactorily completed the work of this department as per the D.C.I guidelines . I hereby give him / her the Certification of completion of Internship programme for this department.

Date 18/06/2021

SIGNATURE

HEAD OF THE DEPARTMENT

ORAL AND MAXILLOFACIAL SURGERY

PROFESSOR & HEAD
Dept. of Oral & Maxillofacial Surgery
D Y Patil Dental School
D Y Patil Knowledge City
Charoli (Bk), Via Lohegaon, Pune - 41210

Name of Procedures	No. of Procedures
Total Extractions	*98*
Minor Surgery	*10*
Assisted Surgery	*41*
G.A. Cases(Major surgery)	*-*
Seminars	*2*
Projects	*Armentarium*
Present days	*45*
Absent days	*0*
C.L / L.W.P	*0*
H.O.D Sign	Borade

CLINICAL EXERCISES TO BE PERFORMED DURING INTERNSHIP PROGRAMME

(A)

1. Simple Extractions,
2. Surgical Extraction,
3. Dis-impactions,Surgical Extractions of Third molar,
4. Inter- maxillary Fixation + Inter- Dental wiring
5. Cyst enucleation
6. Alveoloplasty, Biopsies, Frenectomies

The interns shall have 15 days posting in emergency services of Dental/ General Hospital with extended responsibilities in Emergency Dental Care in wards. During this period they shall attend all emergencies under the direct supervision of Oral Surgeon during any operation.

2. EMERGENCIES:

5. Toothache
6. Trigeminal Neuralgia
7. Bleeding from mouth due to trauma, post – extraction, Bleeding disoders.
8. Airway obstruction due to fractured mandible and maxilla, dislocation of mandible, syncope or vasovagal attacks, Ludwig's Angina,Tooth fracture, Poat inter- maxillary fixation after general anesthesia.

9.

Sr No.	Date	Case No.	Name of Patients	Treatment	Sign
1	26/01	54415	Ram	Extraction46	
2	27/01	55444	Yasmin	Extraction27	
3	28/01	45445	Tuhin	Extraction25	
4	29/01	45485	Tapan	Extraction44	
5	29/01	48879	Ranju	Extraction45	
6	30/01	12112	Disha	Extraction11	
7	30/01	45526	Kajal	Extraction24	
8	31/01	45528	Sejal	Extraction37	
9	2/02	45581	Rudra	Extraction42	
10	3/02	41235	Maahi	Extraction21	
11	4/02	12152	Pratik	Extraction46	
12	4/02	2121	Sneha	Extraction3	

		2		5	
13	5/02	12121	Sadhana	Extraction36	Kapil
14	6/02	25254	Vaishali	Extraction22	Kapil
15	7/02	15412	Nisha	Extraction37	Kapil
16	8/02	42325	Sujal	Extraction45	Kapil
17	8/02	24565	Aayush	Extraction15	Kapil
18	9/02	14426	Varun	Extraction35	
19	10/02	52411	Siya	Extraction15	Kapil
20	10/02	54122	Nargisha	Extraction25	
21	10/02	11552	Datta	Extraction25	
22	11/02	52155	Sanjay	Extraction16	Kapil
23	12/02	22555	Atul	Extraction26	
24	12/02	12254	Aatmaram	Extraction36	Kapil
25	12/02	12152	Navin	Extraction45	

26	13/02	55422	Sonia	Extraction13	Kapil
27	14/02	25656	Sana	Extraction46	
28	15/02	12154	Shahid	Extraction45	Kapil
29	15/02	12155	Fatima	Extraction44	
30	16/02	45454	Terence	Extraction42	Kapil

DYPDS, PUNE

Department of Oral and Maxillofacial Surgery

INTERNS LOGBOOK

NAME: SWARAJ ASTHE

ROLL NO.: 03

YEAR: 2021-2022

DEPARTMENT OF ORAL
AND
MAXILLOFACIAL SURGERY

This is to certify that Intern Roll no-03 Named Mr./Miss. SWARAJ ASTHE satisfactorily completed the work of this department as per the D.C.I guidelines . I hereby give him / her the Certification of completion of Internship programme for this department.

Date 29/9/2022

SIGNATURE

HEAD OF THE DEPARTMENT

ORAL AND MAXILLOFACIAL SURGERY

PROFESSOR & HEAD
Dept. of Oral & Maxillofacial Surgery
D Y Patil Dental School
D Y Patil Knowledge City
Charoli (Bk), Via Lohegaon, Pune - 41210

Name of Procedures	No. of Procedures
Total Extractions	*200*
Minor Surgery	*03*
Assisted Surgery	*37*
G.A. Cases(Major surgery)	*01*
Seminars	-
Projects	
Present days	*43*
Absent days	*2*
C.L / L.W.P	*2*
H.O.D Sign	Borande

CLINICAL EXERCISES TO BE PERFORMED DURING INTERNSHIP PROGRAMME

(A)

1. Simple Extractions,
2. Surgical Extraction,
3. Dis-impactions,Surgical Extractions of Third molar,
4. Inter- maxillary Fixation + Inter- Dental wiring
5. Cyst enucleation
6. Alveoloplasty, Biopsies, Frenectomies

The interns shall have 15 days posting in emergency services of Dental/ General Hospital with extended responsibilities in Emergency Dental Care in wards. During this period they shall attend all emergencies under the direct supervision of Oral Surgeon during any operation.

1.EMERGENCIES:

1. Toothache
2. Trigeminal Neuralgia
3. Bleeding from mouth due to trauma, post – extraction, Bleeding disoders.
4. Airway obstruction due to fractured mandible and maxilla, dislocation of mandible, syncope or vasovagal attacks, Ludwig's Angina,Tooth fracture, Poat inter- maxillary fixation after general anesthesia.

Sr No.	**Date**	**Case No.**	**Name of Patients**	**Treatment**	**Sign**
1	1/7	55454	Rohit Tarade	Extraction24	
2	2/7	65623	Rahul Mor	Extraction17	
3	3/7	96562	Rohan Pise	Extraction36	
4	3/7	56565	Brijesh Patil	Extraction18	
5	4/7	65656	Mihika Patil	Extraction23	
6	4/7	95656	Khushi Rathi	Extraction15	
7	5/7	87779	Isha Chandak	Extraction16	
8	5/7	44848	Pratik Rahate	Extraction28	
9	7/7	48975	Mamta Patil	Extraction34	
10	7/7	44888	Abdul Shaikh	Extraction26	
11	9/7	85455	Charanjeet Singh	Extraction41	
12	12/7	74659	Venkat Iyer	Extraction16	
13	12/7	45465	Harish Shende	Extraction 48	
14	13/7	59659	Manju Jadhav	Extraction14	
15	13/7	99565	Sachin Rathi	Extraction24	
16	13/7	44545	Aditya Roy	Extraction11	

17	15/7	88846	Zeeshan Zaffar	Extraction36	
18	15/7	84454	Ramesh Pawar	Extraction 37	
19	19/7	48888	Sayali Patil	Extraction11	
20	21/7	96565	Nikita Mane	Extraction15	
21	23/7	84846	Swati Shinde	Extraction38	
22	24/7	45454	Mukta Patil	Extraction21	
23	26/7	55554	Vinod Bhave	Extraction12	
24	29/7	44665	Vrushali Shete	Extraction17	
25	30/7	56663	Pramod Thorat	Extraction11	
26	1/8	96997	Chaitanya Koli	Extraction25	
27	1/8	66266	Raghav Patil	Extraction26	
28	2/8	65659	Pratiksha Lokhande	Extraction36	
29	2/8	44999	Sakshi Shinde	Extraction36	
30	3/8	99874	Vaishnavi Satpute	Extraction46	

DYPDS , PUNE

Department of Oral and Maxillofacial Surgery

INTERNS LOGBOOK

NAME: Ankita Mudsinge

ROLL NO.: 45

YEAR: 2021-22

DEPARTMENT OF ORAL AND MAXILLOFACIAL SURGERY

This is to certify that Intern Roll no. -45
Named Mr./Miss Ankita Mudsinge

has satisfactorily completed the work of this department as per the D.C.I guidelines . I hereby give him / her the Certification of completion of Internship programme for this department.

Date 29/9/2022

SIGNATURE

HEAD OF THE DEPARTMENT

ORAL AND MAXILLOFACIAL SURGERY

PROFESSOR & HEAD
Dept. of Oral & Maxillofacial Surgery
D Y Patil Dental School
D Y Patil Knowledge City
Charoli (Bk), Via Lohegaon, Pune - 41210

Name of Procedures	No. of Procedures
Total Extractions	*130*
Minor Surgery	*04*
Assisted Surgery	*35*
G.A. Cases(Major surgery)	*01*
Seminars	*02*
Projects	*Armamentarium*
Present days	*45*
Absent days	*0*
C.L / L.W.P	*0*
H.O.D Sign	

CLINICAL EXERCISES TO BE PERFORMED DURING INTERNSHIP PROGRAMME

(A)

1. Simple Extractions,
2. Surgical Extraction,
3. Dis-impactions,Surgical Extractions of Third molar,
4. Inter- maxillary Fixation + Inter- Dental wiring
5. Cyst enucleation
6. Alveoloplasty, Biopsies, Frenectomies

The interns shall have 15 days posting in emergency services of Dental/ General Hospital with extended responsibilities in Emergency Dental Care in wards. During this period they shall attend all emergencies under the direct supervision of Oral Surgeon during any operation.

1. EMERGENCIES:

1. Toothache
2. Trigeminal Neuralgia
3. Bleeding from mouth due to trauma, post – extraction, Bleeding disoders.
4. Airway obstruction due to fractured mandible and maxilla, dislocation of mandible, syncope or vasovagal attacks, Ludwig's Angina,Tooth fracture, Poat inter- maxillary fixation after general anesthesia.

Sr No.	Date	Case No.	Name of Patients	Treatment	Sign
1	26/6	45451	Abhijeet Khande	Extraction 34	
2	27/6	45455	Sunita Kamble	Extraction 45	
3	28/6	88449	Rohini Hande	Extraction 12	
4	30/6	94546	Pravin Karande	Extraction 36	
5	2/7	49466	Mansi Choure	Extraction 36	
6	3/7	94466	Rounak Chourasiya	Extraction 46	
7	5/7	64646	Rohit Bhave	Extraction 25	
8	7/7	46464	Kshitija Kale	Extraction 14	
9	8/7	46465	Abhishek Gore	Extraction 47	
10	9/7	99595	Rutuja Hinjawade	Extraction 28	
11	10/7	99779	Rohan Mane	Extraction 16	
12	11/7	47865	Gourav Shinde	Extraction 15	
13	12/7	48884	Pratik Gaikwad	Extraction 27	
14	14/7	87877	Mangesh Hande	Extraction 37	
15	15/7	78565	Mukta Thorat	Extraction 15	
16	18/7	56569	Mangal Shinde	Extraction 32	

17	19/7	99995	Urmila Rajput	Extraction 17	
18	20/7	99595	Sagar Patil	Extraction 25	
19	22/7	48884	Pooja Singh	Extraction 46	
20	23/7	84885	Anush Raut	Extraction 11	
21	24/7	88448	Mamta Patil	Extraction 22	
22	26/7	48888	Priyanka Jadhav	Extraction 45	
25	27/7	84815	Sadhana Galave	Extraction11	
26	27/7	48484	Aayush Salgar	Extraction25	
27	28/9	48889	Rutika Patil	Extraction36	
28	28/9	44884	Prasad Patel	Extraction46	
29	29/9	98484	Jayshree Waksay	Extraction36	
30	30/9	98779	Datta Patil	Extraction16	

DYPDS, PUNE

Department of Oral and Maxillofacial Surgery

INTERNS LOGBOOK

NAME:MARIA NOOR

ROLL NO.:47

YEAR:2022-23

DEPARTMENT OF ORAL

AND

MAXILLOFACIAL SURGERY

This is to certify that Intern Roll no. -47
Named Mr./Miss MARIA NOOR

has satisfactorily completed the work of this department as per the D.C.I guidelines . I hereby give him / her the Certification of completion of Internship programme for this department.

Date 27/9/2023

SIGNATURE

HEAD OF THE DEPARTMENT

ORAL AND MAXILLOFACIAL SURGERY

PROFESSOR & HEAD
Dept. of Oral & Maxillofacial Surgery
D Y Patil Dental School
D Y Patil Knowledge City
Charoli (Bk), Via Lohegaon, Pune - 41210

Name of Procedures	No. of Procedures
Total Extractions	*87*
Minor Surgery	*3*
Assisted Surgery	*25*
G.A. Cases(Major surgery)	*-*
Seminars	*3*
Projects	*Armamentarium*
Present days	*45*
Absent days	*0*
C.L / L.W.P	*0*
H.O.D Sign	

CLINICAL EXERCISES TO BE PERFORMED DURING INTERNSHIP PROGRAMME

(A)

1. Simple Extractions,
2. Surgical Extraction,
3. Dis-impactions,Surgical Extractions of Third molar,
4. Inter- maxillary Fixation + Inter- Dental wiring
5. Cyst enucleation
6. Alveoloplasty, Biopsies, Frenectomies

The interns shall have 15 days posting in emergency services of Dental/ General Hospital with extended responsibilities in Emergency Dental Care in wards. During this period they shall attend all emergencies under the direct supervision of Oral Surgeon during any operation.

1.EMERGENCIES:

1. Toothache
2. Trigeminal Neuralgia
3. Bleeding from mouth due to trauma, post – extraction, Bleeding disoders.
4. Airway obstruction due to fractured mandible and maxilla, dislocation of mandible, syncope or vasovagal attacks, Ludwig's Angina,Tooth fracture, Poat inter- maxillary fixation after general anesthesia.

Sr No.	Date	Case No.	Name of Patients	Treatment	Sign
1	25/3	45523	Puja	Extraction12	
2	25/3	54551	Sanjeev	Extraction25	
3	26/3	55151	Sharmin	Extraction36	
4	27/3	65516	Rupali	Extraction45	
5	28/3	64416	Arup	Extraction47	
6	29/3	66545	Neha	Extraction46	
7	30/3	65445	Bikram	Extraction15	
8	2/3	45454	Pritam	Extraction12	
9	2/3	15511	Chanchal	Extraction11	
10	3/3	51518	Rukshat	Extraction36	
11	4/3	11155	Megha	Extraction25	
12	4/3	51551	Neetabai	Extraction15	
13	5/3	15215	Kanchan	Extraction45	
14	5/3	51515	Jayprakash	Extraction46	
15	6/3	15155	Ganesh	Extraction26	
16	6/3	15543	Swaroop	Extraction27	

17	7/3	54666	Geetanjali	Extraction37	
18	8/3	78965	Poonam	Extraction36	Vaishali
19	9/3	78944	Santosh	Extraction33	
20	10/3	74848	Rutuja	Extraction34	Vaishali
21	10/3	89849	Prabhat	Extraction45	Kapil
22	11/3	98859	Jyoti	Extraction42	Vaishali
23	11/3	98816	Aakash	Extraction41	Vaishali
24	12/3	84516	Sudhir	Extraction11	
25	15/3	44157	Vanita	Extraction16	Vaishali
26	15/3	49694	Deepak	Extraction17	
27	17/3	49699	Madhuri	Extraction25	Kapil
28	17/3	51854	Shyam	Extraction26	Vaishali
29	18/3	26545	Mohini	Extraction14	Vaishali
30	18/3	45448	Swati	Extraction13	Vaishali

DYPDS, PUNE

Department of Oral and Maxillofacial Surgery

INTERNS LOGBOOK

NAME:NEHA PITALE

ROLL NO.:66

YEAR:2022-23

DEPARTMENT OF ORAL

AND

MAXILLOFACIAL SURGERY

This is to certify that Intern Roll no. -66
Named Mr./Miss NEHA PITALE

has satisfactorily completed the work of this department as per the D.C.I guidelines . I hereby give him / her the Certification of completion of Internship programme for this department.

Date 27/09/2023

SIGNATURE

HEAD OF THE DEPARTMENT

ORAL AND MAXILLOFACIAL SURGERY

PROFESSOR & HEAD
Dept. of Oral & Maxillofacial Surgery
D Y Patil Dental School
D Y Patil Knowledge City
Charoli (Bk), Via Lohegaon, Pune - 41210

Name of Procedures	No. of Procedures
Total Extractions	*96*
Minor Surgery	*05*
Assisted Surgery	*28*
G.A. Cases(Major surgery)	*-*
Seminars	*2*
Projects	*Armamentarium*
Present days	*43*
Absent days	*2*
C.L / L.W.P	*2*
H.O.D Sign	Kerande

CLINICAL EXERCISES TO BE PERFORMED DURING INTERNSHIP PROGRAMME

(A)

1. Simple Extractions,
2. Surgical Extraction,
3. Dis-impactions,Surgical Extractions of Third molar,
4. Inter- maxillary Fixation + Inter- Dental wiring
5. Cyst enucleation
6. Alveoloplasty, Biopsies, Frenectomies

The interns shall have 15 days posting in emergency services of Dental/ General Hospital with extended responsibilities in Emergency Dental Care in wards. During this period they shall attend all emergencies under the direct supervision of Oral Surgeon during any operation.

2. EMERGENCIES:

5. Toothache
6. Trigeminal Neuralgia
7. Bleeding from mouth due to trauma, post – extraction, Bleeding disoders.
8. Airway obstruction due to fractured mandible and maxilla, dislocation of mandible, syncope or vasovagal attacks, Ludwig's Angina,Tooth fracture, Poat inter- maxillary fixation after general anesthesia.

Sr No.	Date	Case No.	Name of Patients	Treatment	Sign
1	26/6	45451	Abhijeet Khande	Extraction 34	
2	27/6	45455	Sunita Kamble	Extraction 45	
3	28/6	88449	Rohini Hande	Extraction 12	
4	30/6	94546	Pravin Karande	Extraction 36	
5	2/7	49466	Mansi Choure	Extraction 36	
6	3/7	94466	Rounak Chourasiya	Extraction 46	
7	5/7	64646	Rohit Bhave	Extraction 25	
8	7/7	46464	Kshitija Kale	Extraction 14	
9	8/7	46465	Abhishek Gore	Extraction 47	
10	9/7	99595	Rutuja Hinjawade	Extraction 28	
11	10/7	99779	Rohan Mane	Extraction 16	
12	11/7	47865	Gourav Shinde	Extraction 15	
13	12/7	48884	Pratik Gaikwad	Extraction 27	
14	14/7	87877	Mangesh Hande	Extraction 37	
15	15/7	78565	Mukta Thorat	Extraction 15	
16	18/7	56569	Mangal Shinde	Extraction 32	

17	19/7	99995	Urmila Rajput	Extraction 17	
18	20/7	99595	Sagar Patil	Extraction 25	
19	22/7	48884	Pooja Singh	Extraction 46	
20	23/7	84885	Anush Raut	Extraction 11	
21	24/7	88448	Mamta Patil	Extraction 22	
22	26/7	48888	Priyanka Jadhav	Extraction 45	
25	27/7	84815	Sadhana Galave	Extraction11	
26	27/7	48484	Aayush Salgar	Extraction25	
27	28/9	48889	Rutika Patil	Extraction36	
28	28/9	44884	Prasad Patel	Extraction46	
29	29/9	98484	Jayshree Waksay	Extraction36	
30	30/9	98779	Datta Patil	Extraction16	

Record Book Details

Internship

Department of Prosthodontics and Crown and Bridge

D Y PATIL
DENTAL SCHOOL
(Affiliated to Maharashtra University of health Sciences, Nashik)
Dr D Y Patil Knowledge City, Charoli Budruk, via Lohegaon, Pune 412 105

INTERNSHIP PERFORMANCE DATA BOOK

Department of Prosthodontics and Crown and Bridge

Name of the Intern: Anjali Jadhav.

Academic Year: 2022 - 23

Year of Admission: 2018

Year of Passing Final BDS: 2022.

D Y PATIL
DENTAL SCHOOL
(Affiliated to Maharashtra University of health Sciences, Nashik)
Dr D Y Patil Knowledge City, Charoli Budruk, via Lohegaon, Pune 412 105

Internship Completion Certificate

This is to certify that -

Mr. /Miss./Mrs. Anjali Jadhav.

Has satisfactorily completed department work as per the DCI guideline within his/her clinical posting. Further it is stated that during this period, his /her clinical work and conduct was found to be satisfactory.

Head of Department of Prosthodontics
DY PATIL DENTAL SCHOOL
DY Patil Knowledge City, Charholi
Lohegaon,Pune - 412105

Head of Department

Department of Prosthodontics and Crown and Bridge

D Y Patil Dental School, Pune
Department of Prosthodontics
Internship Summary Format (Academic Year 2022-2024)

Name of the Student: Anjali Jadhav.

Sr. No.	Activity Performed	MUHS Recommended Mandatory Quota	Work Done	Grade/ Points	Signature of Instructors
1.	Standardized Examination of the Patients with common Prosthodontic complains	25	25	A	
2.	Alginate Impression	10	10	B+	
3.	Putty Impression	10	10	B+	
4.	Crown Cementation	10	10.	B+	

Signature :	
Name :	Dr. Kamal Shigli
(Head of Department)	

Head of Department of Prosthodontics
DY PATIL DENTAL SCHOOL
Patil Knowledge City, Charholi
Pune-412105

1. Standardized Examination of the Patients with common Prosthodontics complaints.

Sr. No.	OPD No.	Name of the Patient	Age/Sex	Diagnosis	Signature of Staff
1.	76374.	Varsha Mane	22/F	Missing teeth	
2.	76345	Nitin Parkar	15/M	PoR seen	
3.	76400	Supriya Patil	27/F	Food lodgment	
4.	76414.	Udaykumar P.	17/M.	Disloged Prosthesis	
5.	84790.	Deepak Patil	38/M	PoR seen	
6.	84019	Aniket Pawar	26/M.	Recementation	
7.	83992	Deepika B.	37/F	Missing teeth.	
8.	83994	Mahesh Sasane	47/M.	Completed denture	
9.	84015.	Vaishali Bangar	33/F	PoR seen	
10	84006	Rakesh Sharma	37/M	Missing teeth	
11.	83999	Swati Bhosale	35/F	Dislogeded Prost	
12.	68856.	Ashirrad K	27/M	Recementation	
13	69135	Manisha Agare	25 /F	Dislogeded Prosthesis	
14.	69128	Prakash B.	50/M	PoR seen	
15.	69104	Mohammad K.	31/M.	Missing teeth	
16.	69096	Sakina Mulla	25/F	Disloged Prosthesis	
17.	69089	Priyanka Lodge	28/F	PoR seen	
18.	69073	Khalid Patel	28/M	Missing teeth	
19.	74760	Manikrao Pawar	50/M	PoR seen	
20.	74766	Rupali Kakade	52/F	Dislodged Prosthesis	
21.	74797	Vimal Sonawane	52/F	Complete denture	
22.	74844	Ramdas Dethe	56/M.	Missing teeth	
23.	83984.	Komal Gaikwad	24/F	PoR seen	
24.	84118.	Pradika Barkar	29/F	Recementation	
25.	84082	Pravar Sathe	28/M.	Dislodged Prosthesis	
26.	84073	Anil Mohite	37/M.	Missing teeth	

Department of Prosthodontics

Work record

3. Putty Impression

Sr. No.	OPD No.	Name of the Patient	Age/Sex	Signature of Staff
1.	97684	Raju Jadhav.	29/M	
2.	99903	Ashish Sharma	38/M	
3.	98842	Vishal Ghugeay.	61/M	
4.	98839.	Anusaya Wadkar	71/F	
5.	98163	Pramod Wadekar	85/M	
6	102460	Jagdish Raibhiya	60/M	
7.	102480	Sunna Kapoor.	54/F	
8.	105808	Rajiv Khardl	69/M	
9.	105822	Gyaran khardave.	58/M	
10.	61157	Atul Bansodl	41/M.	

2. Alginate Impression

Sr. No.	OPD No.	Name of the Patient	Age/Sex	Signature of Staff
1.	98959.	Kareri Malusure	59/M	
2.	98946	Seema Chitale	64/F	
3.	97335	Dinesh Mane	72/M	
4.	97509.	Prabhawati Gaud	62/F	
5.	97574	Pratibha Gade	50/F	
6.	99910	Suvarda Pimparkar	52/F	
7.	10/061	Kundalik Murkute	40/F	
8.	64726	Nargis Saifi	32/F	
9.	3 6868	Indira Tanver	39/F	
10.	92015	Megha Dhote	32/F	

Department of Prosthodontics

Work record

4. Crown Cementation

Sr. No.	OPD No.	Name of the Patient	Age/Sex	Signature of Staff
1.	98366	Sunil Kumvar	51/M.	
2.	98365	Harsh Bhadarl	55/M	
3.	97282	Manisha Pawar	44/F	
4.	97318	Madhu Gaikwad.	45/F	
5.	101984	Gaurav Gadekar	26/M	
6.	36868	Indira Tanra.	67/F	
7.	98432	Ravindra Mali	41/M	
8.	98376	Pandit Bhill.	59/M.	
9.	98372	Shantaram Bhawarl	58/M	
10.	98364	Rajaram Mali	78/M.	

D Y PATIL
DENTAL SCHOOL
(Affiliated to Maharashtra University of health Sciences, Nashik)
Dr D Y Patil Knowledge City, Charoli Budruk, via Lohegaon, Pune 412 105

INTERNSHIP PERFORMANCE DATA BOOK

Department of Prosthodontics and Crown and Bridge

Name of the Intern: Neha Girish Pitale.

Academic Year: 2022-23

Year of Admission: 2018

Year of Passing Final BDS: 2022

D Y PATIL
DENTAL SCHOOL
(Affiliated to Maharashtra University of health Sciences, Nashik)
Dr D Y Patil Knowledge City, Charoli Budruk, via Lohegaon, Pune 412 105

Internship Completion Certificate

This is to certify that -

Mr. /Miss./Mrs. Neha Pitale

Has satisfactorily completed department work as per the DCI guideline within his/her clinical posting. Further it is stated that during this period, his /her clinical work and conduct was found to be satisfactory.

Head of Department of Prosthodontics
DY PATIL DENTAL SCHOOL
DY Patil Knowledge City, Charoli
Lohegaon, Pune - 412105

Head of Department

Department of Prosthodontics and Crown and Bridge

D Y Patil Dental School, Pune
Department of Prosthodontics
Internship Summary Format (Academic Year 2022-2023)

Name of the Student: Neha Pitale

Sr. No.	Activity Performed	MUHS Recommended Mandatory Quota	Work Done	Grade/ Points	Signature of Instructors
1.	Standardized Examination of the Patients with common Prosthodontic complains	25	25	A+	
2.	Alginate Impression	10	10	B+	
3.	Putty Impression	10	10	B+	
4.	Crown Cementation	10	10	A	

Signature :
Name : Dr. Kaustal Shighi
(Head of Department)

Head of Department of Prosthodontics
DY PATIL DENTAL SCHOOL
DY Patil Knowledge City, Charholi
Lohegaon,Pune - 412105

Department of Prosthodontics

Work record

1. **Standardized Examination of the Patients with common Prosthodontics complaints.**

Sr. No.	OPD No.	Name of the Patient	Age/Sex	Diagnosis	Signature of Staff
1.	98610	Anil Bachare	61/M	Completely edentulous max & mand arch	
2.	98517	Pravin shirke	40/M	POR seen.	
3.	98588	Anuradha Mali	58/F	Disloged Prosthesis.	
4.	98579.	Pratima Patil.	43/F	missing teeth	
5.	98522.	Vidya kamble	40/F	POR Done	
6.	43946	Suresh Gado	51/M	Disloged Prosthesis.	
7.	43877	Bharti Jadhav	56/F	Missing teeth	
8.	39122	Saurabh Roy	48/M	POR seen.	
9.	43661	Pangrabad Nath	61/M	POR seen.	
10.	84121	Pramila krojya	30/F	Faulty Prosthesis	
11.	84315	Kiran Kalkumbe	27/M	Food lodgement	
12.	98719	Laila Shaikh	40/F	Missing teeth	
13.	94649	Maruti Shinde	85/M	Disloged Prosthesis.	
14.	97731	Shivajikashid.	52/M	Faulty Prosthesis.	
15.	97707	Krishna More	70/M	POR seen.	
16.	35091	Shweta Nandev	45/F	Missing teeth.	
17.	83620	vithal kumbhar	51/M.	Disloged Prosthesis.	
18.	29709	Savita Hajare	32/F	Missing teeth	
19	73862	Sushila Pandit	85/F	POR seen	
20.	73847	Madhav Gorak	58/M	Disloged Prosthesis.	
21.	73837	Dinkar Gaikwad	80/M	POR seen	
22.	73884	Jyotishirsath	57/F	Missing teeth	
23.	73857	Ganesh Jadhav	51/M	Missing teeth	
24.	102344	Anila Ayyar	50/F	POR seen	
25.	102328	Kavita Joshi	47/F	Disloged Prosthesis.	

2. Alginate Impression

Sr. No.	OPD No.	Name of the Patient	Age/Sex	Signature of Staff
1.	94355	Sneha Shelar	18/F	
2.	101984	Gaurav Gade	18/F	
3.	98483	Yogita Artale	45/F	
4.	10136	Harish Lade	71/M	
5.	10/357	Rajaram Naik	70/M	
6.	101115	Satyakant Ghatge	68/M	
7	102526	Fulabai Sunwasd	65/F	
8.	102386	Vishwanath Naik	60/M.	
9.	102416	Rishav Arya	18/M	
10.	102318	Rajen Pandikh	57/M	

Department of Prosthodontics

Work record

4. Crown Cementation

Sr. No.	OPD No.	Name of the Patient	Age/Sex	Signature of Staff
1.	101371	Mohan Sawant	78/M	
2.	101367	Pramila Vartak	71/F	
3.	101353	Chandrakant Khatu	67/M	
4.	102321	Kiran Gala	52/M	
5.	102328	Sandeep Mali	54/M	
6.	90106	Anil Thakare	60/M	
7.	100304	Seema Choudhary	34/F	
8.	57980	Maya Sharma	36/F	
9.	90251	Sanjay Yadav	46/M	
10.	90245	Kusum Kale	41/F	

Department of Prosthodontics

Work record

3. Putty Impression

Sr. No.	OPD No.	Name of the Patient	Age/Sex	Signature of Staff
1.	82672	Rekha Adap.	42/F	
2.	88081	Mandar Patil	21/M	
3.	88932	Pratibha Metkari	53/F.	
4.	77510	Pramod Gophane	60/M	
5.	99917	Anand Ostwal	28/M	
6.	83784	Jyoti More	22/F	
7.	23490	Ramchandra Saste	54/M	
8.	70275	Madhav Pawar	46/M	
9.	104854	Nasreen Ansari	30/F	
10.	94356	Rajkumari Choudhary	27/F	

D Y PATIL
DENTAL SCHOOL
(Affiliated to Maharashtra University of health Sciences, Nashik)
Dr D Y Patil Knowledge City, Charoli Budruk, via Lohegaon, Pune 412 105

INTERNSHIP PERFORMANCE DATA BOOK

Department of Prosthodontics and Crown and Bridge

Name of the Intern: Nikhil Menghani

Academic Year: 2021 - 2022

Year of Admission: 2017

Year of Passing Final BDS: 2021

D Y PATIL
DENTAL SCHOOL
(Affiliated to Maharashtra University of health Sciences, Nashik)
Dr D Y Patil Knowledge City, Charoli Budruk, via Lohegaon, Pune 412 105

Internship Completion Certificate

This is to certify that -

Mr. /Miss./Mrs. Nikhil Menghani

Has satisfactorily completed department work as per the DCI guideline within his/her clinical posting. Further it is stated that during this period, his /her clinical work and conduct was found to be satisfactory.

Head of Department of Prosthodontics
DY PATIL DENTAL SCHOOL
DY Patil Knowledge City, Charoli
Lohegaon,Pune -412105

Head of Department

Department of Prosthodontics and Crown and Bridge

D Y Patil Dental School, Pune
Department of Prosthodontics
Internship Summary Format (Academic Year 2021 2022)

Name of the Student: Nikhil Menghani

Sr. No.	Activity Performed	MUHS Recommended Mandatory Quota	Work Done	Grade/ Points	Signature of Instructors
1.	Standardized Examination of the Patients with common Prosthodontic complains	25	21	A++	
2.	Alginate Impression	10	10	—	
3.	Putty Impression	10	10	A+	
4.	Crown Cementation	10	10	A++	

Signature :
Name : Dr. Kaunal Shighi
(Head of Department)

Head of Department of Prosthodontics
DY PATIL DENTAL SCHOOL
DY Patil Knowledge City, Charholi
Lohegaon,Pune - 412105

Department of Prosthodontics

Work record

1. Standardized Examination of the Patients with common Prosthodontics complaints.

Sr. No.	OPD No.	Name of the Patient	Age/Sex	Diagnosis	Signature of Staff
1	77628	Suraj Sharma	55/M	POR seen	
2	79032	Sakshi Goswami	28/F	Missing teeth	
3	78996	Nikita Mali	28/F	Dislodged prosthesis	
4	77615	Madhav Pagare	50/M	faulty prosthesis	
5	77634	Pravin Mhaske	51/M	Missing teeth	
6	77646	Mahish Jadhav	55/M	Missing teeth	
7	77663	Prerna Kulkarni	52/F	POR seen	
8	33435	Yashwant Chauhan	61/M	dislodged prosthesis	
9	78666	Vanita Pol	60/F	Missing teeth	
10	78745	Ramatai Dange	55/F	POR seen	
11	78778	Vaman Mhaske	52/M	POR seen	
12	78796	Atmaram More	55/M	faulty prosthesis	
13	78709	Vinay Kadam	56/M	Missing teeth	
14	78692	Bhavana Khedkar	55/F	POR seen	
15	78683	Sanjay Kedari	56/M	Missing teeth	
16	78673	Dinesh Gaikwad	59/M	POR seen	
17	78714	Rupali Sabale	53/F	POR seen	
18	71575	Ajay Thakur	43/M	POR seen	
19	71593	Aapeksha Gitte	22/F	food lodgement	
20	71614	Pramod Kulkarni	20/M	Food lodgement	
21	71509	Lalit Sutar	31/M	faulty prosthesis	

Department of Prosthodontics

Work record

2. Alginate Impression

Sr. No.	OPD No.	Name of the Patient	Age/Sex	Signature of Staff
1	72563	Suraj Landge	33/M	
2	72557	Mohit Ranad.	32/M	
3	72549	Suraj Mate	24/M	
4	72544	Priyanka Gaikwad	32/F	
5	72537	Deepak Pawar	34/F	
6	72525	Ganpat Patil	44/M	
7	28618	Sunil Rahane	51/M	
8	81821	Sachin Parkh.	17/M	
9	8163	Sunny Jadhav	17/M	
10	81608	Ruchika Sabal.	22/F	

Department of Prosthodontics

Work record

3. Putty Impression

Sr. No.	OPD No.	Name of the Patient	Age/Sex	Signature of Staff
1	31733	Ramesh Salakhe	34/M	
2	70329	Anita Shelar	35/F	
3	70326	Manohar Rase	46/M	
4	70273	Prabha Dhange	29/F	
5	70320	Khandubha Sule	41/M	
6	52315	Krishnakant Mavinkar	58/M	
7	47907	Deepak Bhise	24/M	
8	48903	Pooja Gaikwad	28/F	
9	68841	Bharti Sesai	60/F	
10	81626	Ashwini Bhagat	33/F	

4. Crown Cementation

Sr. No.	OPD No.	Name of the Patient	Age/Sex	Signature of Staff
1	81528	Jaikishor Jadhav	41/M	
2	83101	Vinayak Bhosale	51/M	
3	80471	Shivaji Mastud	36/M	
4	82502	Gopikishan Surange	29/M	
5	74470	Dr S.M. Khairnar	54/M	
6	40377	Swapnil Khandare	21/M	
7	66567	Bhimrao Ahire	32/M	
8	82402	Ashok Bhangade	65/M	
9	76617	Vaishali Khandare	42/F	
10	80004	Karan Kamble	20/M	

D Y PATIL
DENTAL SCHOOL
(Affiliated to Maharashtra University of health Sciences, Nashik)
Dr D Y Patil Knowledge City, Charoli Budruk, via Lohegaon, Pune 412 105

INTERNSHIP PERFORMANCE DATA BOOK

Department of Prosthodontics and Crown and Bridge

Name of the Intern: Swaraj Asthe

Academic Year: 2021 - 2022

Year of Admission: 2017

Year of Passing Final BDS: 2021.

D Y PATIL
DENTAL SCHOOL
(Affiliated to Maharashtra University of health Sciences, Nashik)
Dr D Y Patil Knowledge City, Charoli Budruk, via Lohegaon, Pune 412 105

Internship Completion Certificate

This is to certify that -

Mr. /~~Miss./Mrs.~~ Swaraj Asthe

Has satisfactorily completed department work as per the DCI guideline within his/her clinical posting. Further it is stated that during this period, his /her clinical work and conduct was found to be satisfactory.

Head of Department of Prosthodontics
DY PATIL DENTAL SCHOOL
DY Patil Knowledge City, Charholi
Lohegaon,Pune - 412105

Head of Department

Department of Prosthodontics and Crown and Bridge

D Y Patil Dental School, Pune
Department of Prosthodontics
Internship Summary Format (Academic Year 2021 2022)

Name of the Student: Swaraj Asthe

Sr. No.	Activity Performed	MUHS Recommended Mandatory Quota	Work Done	Grade/ Points	Signature of Instructors
1.	Standardized Examination of the Patients with common Prosthodontic complains	25	25	B++	
2.	Alginate Impression	10	10	A	
3.	Putty Impression	10	10	B++	
4.	Crown Cementation	10	10	B++	

Signature :
Name : Dr. Kamal Shigli
(Head of Department)

Head of Department of Prosthodontics
D Y PATIL DENTAL SCHOOL
D Y Patil Knowledge City, Charholi
Pune

Department of Prosthodontics

Work record

1. Standardized Examination of the Patients with common Prosthodontics complaints.

Sr. No.	OPD No.	Name of the Patient	Age/Sex	Diagnosis	Signature of Staff
1.	28018	Rohit Waghre	28/M	Missing tooth	
2.	83076	Lalit Joshi	39/M	POR seen	
3.	73406	Vinod Dhakane	44/M	dislodged Restorat	
4.	81127	Pramod Gupta	33/M	Food lodgement	
5.	81124	Varit Gaikwad	24/F	Missing teeth	
6.	81097	Seema Kavade	27/F	dislodged Prosthesis	
7.	76851	Jayad Patole	51/M	POR seen	
8.	76869	Savitri Nimal	62/F	dislodged Prosthesis	
9.	76893	purabh Mohite	42/M	dislodged Prosthesis	
10.	80819	Nitin Pardeshi	46/M	POR seen	
11.	87423	Sanjana Borade	29/F	Missing teeth	
12.	85241	Mohan Kadam	32/M	Missing teeth	
13.	87291	Rekha Bhabare	35/F	Food lodgement	
14.	86242	Subhash Jawade	40/M	dislodged Prosthesis	
15.	79241	Mohini Gawahre	30/F	POR seen	
16.	78124	Sanika Joshi	26/F	POR seen	
17.	34571	Gautami kamble	24/F	Missing tooth	
18.	84510	Rohini Mahadik	34/F	Food lodgement	
19.	85678	Sarket Choudhari	28/M	Missing tooth	
20.	89120	Vaishali Kedekar	46/F	POR seen	
21.	81175	Krushana kamble	40/F	POR seen	
22.	89241	Birendra Chavan	55/M	Complete denture	
23.	88241	Adesh Dagade	29/M	Missing teeth	
24.	85648	Santosh Dhumal	39/M	dislodged Prosthesis	
25.	88122	Vijay Chandane	34/M	dislodged Prosthesis	

2. Alginate Impression

Sr. No.	OPD No.	Name of the Patient	Age/Sex	Signature of Staff
1.	53449.	Dnyeshwari Bhosale	33/M.	
2.	71339	Pratibha Pandit	42/F	
3.	77488	Santosh Rao.	54/M	
4.	79929.	Vaishali Dalvi	28/F	
5.	79855	Aditi Mane	34/F	
6.	55794	Atharva Mane	25/M	
7.	55780	Rohit Malkhede	31/M	
8.	81346	Krista Chaubey	29/F	
9.	55754	Baburao Chavan	58/M	
10.	55788	Laxman Kakad	53/M	

Department of Prosthodontics

Work record

4. Crown Cementation

Sr. No.	OPD No.	Name of the Patient	Age/Sex	Signature of Staff
1.	73453	Pawan kunwar.	44/M	
2.	43366	Indu Chaubey	45/F	
3.	79319	Puran kumpawat	28/M	
4.	80291	Usha Daulkar	21/F	
5.	81346	krishna Chaubey	38/F	
6.	43366	Prajakta Medhe	40/F	
7.	30571	Babasaheb Unarmare	60/M	
8.	82967	Madhuri Mashud	54/F	
9.	79312	Shivaji kakade	52/M	
10.	80472	Pramod Patil	41/M	

Department of Prosthodontics

Work record

3. Putty Impression

Sr. No.	OPD No.	Name of the Patient	Age/Sex	Signature of Staff
1.	83097	Sandeep Tupe	32/M	
2.	83101	Vinayak Bhosale	41/M	
3.	83108	Dilip shetty	51/M	
4.	83105	Lalit Prajapati	60/M	
5.	83113	Savita Pawar	35/F	
6.	83117	Rupali Gaikwad	45/F	
7.	83137	Taruja Pawar.	48/F	
8.	83178	Vinayak Gokhale	28/M	
9.	83182	Sitabai Badade	65/F	
10.	80184	Ratikaran Chavan	57/F	

D Y PATIL
DENTAL SCHOOL
(Affiliated to Maharashtra University of health Sciences, Nashik)
Dr D Y Patil Knowledge City, Charoli Budruk, via Lohegaon, Pune 412 105

INTERNSHIP PERFORMANCE DATA BOOK

Department of Prosthodontics and Crown and Bridge

Name of the Intern: Vaibhav Shivale.

Academic Year: 2019 – 2020

Year of Admission: 2015

Year of Passing Final BDS: 2019.

D Y PATIL
DENTAL SCHOOL
(Affiliated to Maharashtra University of health Sciences, Nashik)
Dr D Y Patil Knowledge City, Charoli Budruk, via Lohegaon, Pune 412 105

Internship Completion Certificate

This is to certify that -

Mr. /~~Miss./Mrs.~~ Vaibhav Shinde.

Has satisfactorily completed department work as per the DCI guideline within his/her clinical posting. Further it is stated that during this period, his /her clinical work and conduct was found to be satisfactory.

Head of Department of Prosthodontics
DY PATIL DENTAL SCHOOL
DY Patil Knowledge City, Charholi
Lohegaon, Pune - 412105

Head of Department

Department of Prosthodontics and Crown and Bridge

D Y Patil Dental School, Pune
Department of Prosthodontics
Internship Summary Format (Academic Year 2019 2020)

Name of the Student: Vaibhav Shinde

Sr. No.	Activity Performed	MUHS Recommended Mandatory Quota	Work Done	Grade/ Points	Signature of Instructors
1.	Standardized Examination of the Patients with common Prosthodontic complains	25	25	B	
2.	Alginate Impression	10	10	A+	
3.	Putty Impression	10	10	B+	
4.	Crown Cementation	10	10	A	

Signature :
Name : Dr. Kamal Shigli
(Head of Department)

Head of Department of Prosthodontics
DY PATIL DENTAL SCHOOL
DY Patil Knowledge City, Charholi
Talegaon Phata, Pune-412105

Department of Prosthodontics

Work record

1. **Standardized Examination of the Patients with common Prosthodontics complaints.**

Sr. No.	OPD No.	Name of the Patient	Age/Sex	Diagnosis	Signature of Staff
1.	38524.	Ajaykumar. D.	64/M	Missing tooth	
2.	34191	Seema. C.	45/F	POR seen	
3.	44396	Shreepati Kamble	62/M	Missing teeth	
4.	43484	Madhukar P.	60/M	Complete denture	
5.	42949	Rupesh Pardey	45/M	Dislodged Prosthesis	
6.	44000	Saira Karke	20/F	Missing teeth	
7.	43487	Gawade Nakesh	70/M	POR seen	
8.	44641	Mubarak Khan	63/M	POR seen	
9.	38435	Yashwant C.	61/M	Dislodged Prosthesis.	
10.	23283	Vaishali Ambure	33/F	Missing teeth	
11.	42511	Akash Gawade	46/M	Missing teeth	
12.	39471	Vinod Chire	46/M	POR seen.	
13.	41989	Sunil Khese	50/M	Food lodgement	
14.	39484	Sairath Murde	60/M	Missing teeth	
15.	41606	Sakhubai More	55/F	Dislodged Prosthesis.	
16.	12058	Anandkumar J.	61/M	Complete denture	
17.	42898	Firoz Musawar	42/M	Missing teeth	
18.	44769	Anil Dangi	52/M	POR seen	
19.	39578	Reshma Kolekar	58/F	dislodged Prosthesis.	
20.	44285	Sahil Ahmad	40/M	Missing teeth	
21.	43129	Farooq Khan	55/M	POR seen	
22.	37801	Vishal D.	40/M	POR seen	
23.	44376	Somnath D.	61/M	Complete denture	
24.	88662	Anil Patil	51/M	Missing teeth	
25.	99039.	Ashit Sharma	28/M	Missing teeth	
26.	45140	Kajal Nitkar	24/F	POR seen	
.					

2. Alginate Impression

Sr. No.	OPD No.	Name of the Patient	Age/Sex	Signature of Staff
1.	24849	Mayuri Panchmukhe	18/F	
2.	23833	Khushi Bhake	20/F	
3.	25639	Meena Pathare	24/F	
4.	28392	Sanjay Gogare	50/M	
5.	26027	Abhijeet Shelar	41/M	
6.	23571	Shailesh Pawar	55/M	
7.	34375	Sandhya Sonawane.	29/F	
8.	93508	Pratibha Gawali	53/F	
9.	65361	Vidya More	42/F	
10.	98920	Rahul Tomar	20/M	

Department of Prosthodontics

Work record

3. Putty Impression

Sr. No.	OPD No.	Name of the Patient	Age/Sex	Signature of Staff
1.	63830	Mohammad Shaikh.	20/M	[signature]
2.	98920	Shaina2 Shaikh.	4/F	[signature]
3.	92979	Bindu Agarwal	55/F	[signature]
4.	99355	Kajol Vitkar	24/F	[signature]
5.	99573	Godavari Munde	57/F	[signature]
6.	38914	Bhaurao Kakde	52/M	[signature]
7.	37698	Anish Kadam	48/M	[signature]
8.	36901	Shashi Mokate	36/F	[signature]
9.	40287	Manjeet Kaur	51/F	[signature]
10.	38023	Dinanath Chavan.	40/M	[signature]

Department of Prosthodontics

Work record

4. Crown Cementation

Sr. No.	OPD No.	Name of the Patient	Age/Sex	Signature of Staff
1.	88602.	Anil Patil	51/M	
2.	99917	Abhishek Shivgavakar	20/M	
3.	46386	Anita Paul	60/F	
4.	98143	Arkita deshmukh	28/F	
5.	96889	Santosh Paul.	51/F	
6.	56716	Geeta Chavan	44/F	
7.	82502	Gopikishan Sukerya	29/M	
8.	93709	Neeta Ambap	46/F	
9.	10050	Sudam Jagdand	65/M	
10.	84124.	Pramila Krajiya	30/F	

D Y PATIL
DENTAL SCHOOL
(Affiliated to Maharashtra University of health Sciences, Nashik)
Dr D Y Patil Knowledge City, Charoli Budruk, via Lohegaon, Pune 412 105

INTERNSHIP PERFORMANCE DATA BOOK

Department of Prosthodontics and Crown and Bridge

Name of the Intern: Ashwini Pawar

Academic Year: 2019 - 2020.

Year of Admission: 2015

Year of Passing Final BDS: 2019

D Y PATIL
DENTAL SCHOOL
(Affiliated to Maharashtra University of health Sciences, Nashik)
Dr D Y Patil Knowledge City, Charoli Budruk, via Lohegaon, Pune 412 105

Internship Completion Certificate

This is to certify that -

Mr. /Miss./Mrs. Ashwini Pawar

Has satisfactorily completed department work as per the DCI guideline within his/her clinical posting. Further it is stated that during this period, his /her clinical work and conduct was found to be satisfactory.

Head of Department of Prosthodontics
DY PATIL DENTAL SCHOOL
DY Patil Knowledge City, Charoli

Head of Department

Department of Prosthodontics and Crown and Bridge

D Y Patil Dental School, Pune
Department of Prosthodontics
Internship Summary Format (Academic Year 2013 2014)

Name of the Student: Ashwini Pawar.

Sr. No.	Activity Performed	MUHS Recommended Mandatory Quota	Work Done	Grade/ Points	Signature of Instructors
1.	Standardized Examination of the Patients with common Prosthodontic complains	25	25	B	
2.	Alginate Impression	10	10	B++	
3.	Putty Impression	10	10	B	
4.	Crown Cementation	10	10.	B	

Signature :	
Name :	Dr. kaushik Singh
(Head of Department)	

Head of Department of Prosthodontics
DY PATIL DENTAL SCHOOL
D. Y. Patil Knowledge City, Charholi
Pune - 412 105

Department of Prosthodontics

Work record

1. **Standardized Examination of the Patients with common Prosthodontics complaints.**

Sr. No.	OPD No.	Name of the Patient	Age/Sex	Diagnosis	Signature of Staff
1.	32181	Deepak Sarode	35/M	Missing teeth	
2.	45231	Madhumala B.	54/F	Dislodged Prosthesis.	
3.	30241	Chiranjiva Singh	60/M	PoR seen	
4.	42437	Madhuri Shetkar	28/F	Dislodged Prosthesis	
5.	32172	Sushila Singh	40/F	Missing teeth	
6.	45418	Manohar Ankush	80/M	PoR seen.	
7.	43316	Mohan tharad	82/M	Missing teeth	
8.	41584	Lata Shelkarde	48/F	Food lodgement	
9.	43165	Cyril Crasto.	80/M	Dislodged Prosthesis.	
10.	43366	Indu Chaubey	45/F	Missing teeth	
11.	44984	Namdev Tambre	72/M	PoR seen.	
12.	34588	Pooja Sharma	28/F	Missing teeth.	
13.	45526	Keshav Patil	38/M	Dislodged Prosthesis	
14.	34558	Pooja Sharma	28/F	PoR seen	
15.	24220	Harshada J.	27/F	Dislodged Prosthesis.	
16.	44172	Sandhya dubey	25/F	PoR seen.	
17.	38186	Urmila Srivastav	65/F	Food lodgement	
18	44163	Yashwant Sapkar	79/M	Missing teeth	
19.	45113	Tukaram K.	63/M	Missing teeth	
20.	34681	Divakar Bhambal	70/M	Dislodged Prosthesis.	
21.	41967	Vishal Muttur	35/M	PoR seen.	
22.	44152	Viraj K.	68/M	Missing teeth	
23.	45691	Rajaram Lavad	65/M	Food lodgement	
24.	40355	Bhavana Dolse	33/F	Dislodged Prosthesis.	
25.	42322	Suvarna Sorawar	30/F	Missing teeth	

2. Alginate Impression

Sr. No.	OPD No.	Name of the Patient	Age/Sex	Signature of Staff
1.	32181	Deepak Sawale	35/M	
2.	43144	Sawadhan Gaikwad	25/M	
3.	43366	Indu Chaubey	45/F	
4.	44075	Parikabai Bhanarkar	60/F	
5.	35907	Pratiksha Tapkir	24/F	
6.	32782	Salman Ansari	22/M	
7.	44165	Shubana Sapkal	54/F	
8.	42280	Narayan Dhotre	64/M	
9.	31892	Atish Kamble	23/M	
10.	18881.	Suraj Phadtare	23/M.	

Department of Prosthodontics

Work record

3. Putty Impression

Sr. No.	OPD No.	Name of the Patient	Age/Sex	Signature of Staff
1.	41738	Prabhakar Bhalerao	48/M	
2.	44076	Maruda Dhole	42/F	
3.	22823	Sanjay Ballal	34/M	
4.	44152	Vijay Kolwandkar	45/M	
5.	48216	Rushikesh Jamadar	16/M	
6.	41897	Neelam Sharma	41/F	
7.	43787	Samadhan Nikambh	38/M.	
8.	44289.	Bholi Sharma	45/F	
9.	46395	Meera Dange	47/F	
10.	48247	Kiran Sapkal	33/F	

Department of Prosthodontics

Work record

4. Crown Cementation

Sr. No.	OPD No.	Name of the Patient	Age/Sex	Signature of Staff
1.	33651	Prerna Kolekar	33/F	
2.	42511	Akash Gawade	46/M	
3.	41989	Sunil Khese	50/M	
4.	39484	Sairath Munde	50/M	
5.	41606	Sakhubai More	55/F	
6.	40072	Rukmini Kamale	44/F	
7.	41931	Manohar Pol.	50/M	
8.	41099.	Indira Shah	42/M	
9.	34191	Seema Choudhary	45/F	
10.	31666	Namrata Wani	35/F	

D Y PATIL
DENTAL SCHOOL
(Affiliated to Maharashtra University of health Sciences, Nashik)
Dr D Y Patil Knowledge City, Charoli Budruk, via Lohegaon, Pune 412 105

INTERNSHIP PERFORMANCE DATA BOOK

Department of Prosthodontics and Crown and Bridge

Name of the Intern: Siddhi Raut.

Academic Year: 2018 - 2019.

Year of Admission: 2014.

Year of Passing Final BDS: 2018.

D Y PATIL
DENTAL SCHOOL
(Affiliated to Maharashtra University of health Sciences, Nashik)
Dr D Y Patil Knowledge City, Charoli Budruk, via Lohegaon, Pune 412 105

Internship Completion Certificate

This is to certify that -

Mr. /Miss./Mrs. Siddhi Raut

Has satisfactorily completed department work as per the DCI guideline within his/her clinical posting. Further it is stated that during this period, his /her clinical work and conduct was found to be satisfactory.

Head of Department of Prosthodontics
DY PATIL DENTAL SCHOOL
DY Patil Knowledge City, Charholi
Lohegaon,Pune-412105

Head of Department

Department of Prosthodontics and Crown and Bridge

D Y Patil Dental School, Pune
Department of Prosthodontics
Internship Summary Format (Academic Year 2018-2019)

Name of the Student: Siddhi Raut.

Sr. No.	Activity Performed	MUHS Recommended Mandatory Quota	Work Done	Grade/ Points	Signature of Instructors
1.	Standardized Examination of the Patients with common Prosthodontic complains	25	25	A	
2.	Alginate Impression	10	10	B	
3.	Putty Impression	10	10	A	
4.	Crown Cementation	10	10	A	

Signature :
Name : Dr. Kamal Shigli
(Head of Department)

Head of Department of Prosthodontics
DY PATIL DENTAL SCHOOL
DY Patil Knowledge City, Charholi
Lohegaon, Pune - 412105

1. Standardized Examination of the Patients with common Prosthodontics complaints.

Sr. No.	OPD No.	Name of the Patient	Age/Sex	Diagnosis	Signature of Staff
1.	20595	Nifaz Shaikh	30/F	Missing teeth	
2.	23874	Tara Pathak	65/F	Complete denture	
3.	16717	Kisan Bhosale	70/M	Complete denture	
4.	22305	Deepak Panchal	42/M	POR seen	
5.	2109	Avinash S.	30/M	POR seen	
6.	19176	Hemalata S.	54/F	dislodged Prosthesis	
7.	22066	Indu Uball	50/F	Food lodgement	
8.	16768	Anil kadam	58/M	Complete denture	
9.	23823	Chabubai S.	63/F	Missing teeth	
10.	64405	Kashmira Thakkar	55/F	POR seen	
11.	19467	Lalita Jadhav	28/F	Missing teeth	
12	23621.	Anand Adsul	60/M	Complete denture	
13.	2189	Maruti Dere	33/M	POR seen	
14.	19600	Pandurang Shinde	51/M	Missing teeth	
15.	23823	Atul Wagh	36/M	Dislodged Prosthesis	
16.	57645	Mehmuda shaikh	36/F	POR seen	
17.	23804	Vinod kashid	45/M	Missing teeth	
18.	26747	Rohan Purohit	40/M	Missing teeth	
19.	10710	Yogesh Chandlang	21/M	Dislodged Prosthesis	
20	14974	Ashok kate	66/M	Complete denture	
21.	19176	Hemalata S.	52/F	Dislodged Prosthesis	
22.	10712	Bhanu Charoun	54/M	Missing teeth	
23.	68405	Kishore Patil	63/M	Complete denture	
24.	12553	Vikas Nirmal	38/M	POR seen	
25.	19989	Laxmi kadam	65/F	Missing teeth	

2. Alginate Impression

Sr. No.	OPD No.	Name of the Patient	Age/Sex	Signature of Staff
1.	17811	Arti Nawal	42/F	
2.	14265	Bipin Pradhan	37/M	
3.	24661	Chandrakant kumbhar	70/M	
4.	21819	Maruti Desai	33/M	
5.	21044	Jayshree kaul	50/F	
6.	24722	Tanmay Mazumdaar	45/M	
7.	23623	Shashikala Shewal	61/F	
8.	14248	Pradip kalbe	80/M	
9.	24149	Subash Telbale	24/M	
10.	19749	Pooja yadav.	19/F	

Department of Prosthodontics

Work record

3. Putty Impression

Sr. No.	OPD No.	Name of the Patient	Age/Sex	Signature of Staff
1.	21002	Sakshi Lokhande	24/F	
2.	18593	Kuber Kumbure	54/M	
3.	21946	Sunita Khatwani	44/F	
4.	71123	Sushitra kamble	20/F	
5.	24974	Asha Kand	40/F	
6.	16768	Anil kadam	48/M	
7.	20762	Avinash Salunke	25/M	
8.	20840	Ramhari Pachpute.	36/M	
9.	25116	Mrunal Bhosale	26/M	
10.	2282	Renuka Ballal	33/F	

Department of Prosthodontics

Work record

4. Crown Cementation

Sr. No.	OPD No.	Name of the Patient	Age/Sex	Signature of Staff
1.	22464	Mahesh Mahite	20/M	
2.	86612	Mayuri Patil	29/F	
3.	20739	Yogesh Jagtap.	25/M	
4.	25583	Pravin Bhandari	55/M	
5.	24784	Tanmay Shah	34/M	
6.	19542	Mandabai Dhole	75/F	
7.	69833	Geeta Pathare	28/F	
8.	13563	Suvarna Suryawanshi	31/F	
9.	23347	Baban Kalbhor	56/M	
10.	23259.	Pratima Mali.	54/F	

D Y PATIL
DENTAL SCHOOL
(Affiliated to Maharashtra University of health Sciences, Nashik)
Dr D Y Patil Knowledge City, Charoli Budruk, via Lohegaon, Pune 412 105

INTERNSHIP PERFORMANCE DATA BOOK

Department of Prosthodontics and Crown and Bridge

Name of the Intern: Shreya Kothari

Academic Year: 2018 - 2019

Year of Admission: 2014

Year of Passing Final BDS: 2018.

D Y PATIL
DENTAL SCHOOL
(Affiliated to Maharashtra University of health Sciences, Nashik)
Dr D Y Patil Knowledge City, Charoli Budruk, via Lohegaon, Pune 412 105

Internship Completion Certificate

This is to certify that -

Mr. /Miss./Mrs. Shreya Kothari

Has satisfactorily completed department work as per the DCI guideline within his/her clinical posting. Further it is stated that during this period, his /her clinical work and conduct was found to be satisfactory.

Head of Department of Prosthodontics
DY PATIL DENTAL SCHOOL
DY Patil Knowledge City, Charholi
Lohegaon, Pune - 412105

Head of Department

Department of Prosthodontics and Crown and Bridge

D Y Patil Dental School, Pune
Department of Prosthodontics
Internship Summary Format (Academic Year 2018-2019)

Name of the Student: Shreya Kothari

Sr. No.	Activity Performed	MUHS Recommended Mandatory Quota	Work Done	Grade/ Points	Signature of Instructors
1.	Standardized Examination of the Patients with common Prosthodontic complains	25	25	A+	
2.	Alginate Impression	10	10	B	
3.	Putty Impression	10	10	A+	
4.	Crown Cementation	10	10	A	

Signature :
Name : Dr. Kamal Shigli
(Head of Department)

Head of Department of Prosthodontics
DY PATIL DENTAL SCHOOL
DY Patil Knowledge City, Charholi
Lohegaon,Pune - 412105

Department of Prosthodontics

Work record

1. Standardized Examination of the Patients with common Prosthodontics complaints.

Sr. No.	OPD No.	Name of the Patient	Age/Sex	Diagnosis	Signature of Staff
1.	8877	Vithal Burale	66/M	Missing teeth	
2.	19989	Laxmi kadam	85/F	Complete denture	
3.	15767	Mohan Chavan	47/M	Complete denture	
4.	25088	Prabhakar B.	75/M	POR seen	
5.	19018	Sunil Pawar	32/M	POR seen	
6.	26194	Ashok Bhosale	83/M	dislodged Prosthesis	
7.	22259	Mohamad S.	72/M	Fod lodgment.	
8.	24967	Dnyaneshwar D.	47/M	complete denture	
9.	23490	Ramchandra Sasane	54/M	missing teeth	
10.	20762	Avinash Salunke	54/M	POR seen.	
11.	25870	A.K. Shrivastav	25/M	Missing teeth	
12.	17405	Lata Gholap	65/M	Complete denture	
13.	17675	Mayuri Prasad	41/F	POR seen	
14.	22068	Vikas kumar	20/M	missing teeth	
15.	23011	Mangal More	31/M	Dislodged Prosthesis	
16.	24003	Sakat Tekale	43/F	Complete denture	
17.	23845	Tejas Garud	15/M	Dislodged Prosthesis	
18.	22058	Ganesh Khedkar	16/M	missing teeth.	
19.	22481	Sangita Bhonge	36/F	POR seen	
20	23776	Halima Gafur	53/F	missing teeth	
4	24400	Pravin Nikam.	23/M	POR seen	
22	25166	Sukhdev Ghorpade	52/M	dislodged prosthesis	
23	25376	Mahadev Shirale	28/M	complete denture	
24.	12343	Prakash Chaudhary	52/M	POR seen	
25.	21667	Vithal Tasane	45/M	missing teeth	
26.	22068	Vikas kumar	31/M	missing	
27.	16384	Rubina Shaikh.	21/F	POR seen.	

Department of Prosthodontics

Work record

2. Alginate Impression

Sr. No.	OPD No.	Name of the Patient	Age/Sex	Signature of Staff
1.	89729	Sunita Singh	84/F	
2.	26307	Ashok Kadam	64/M	
3.	23691	Anand Adsul	60/M	
4.	26565	Dattatray Mayghe.	64/M	
5.	25716	Eknath Pawar	54/M	
6.	26324	Govind Dongre	47/M	
7.	24880	Amruta Bhalerao	26/F	
8.	26288	Dhanvanti Babar	48/F	
9.	26409	Satendra Palvi	42/M	
10.	26399	Kristal Pal.	25/F	

Department of Prosthodontics

Work record

3. Putty Impression

Sr. No.	OPD No.	Name of the Patient	Age/Sex	Signature of Staff
1.	27009	Surarda Kadam	50/F	
2.	26289	Sunita Bugade	53/F	
3.	14721	Devika Dhavi	35/F	
4.	23677	Leela Shirale	50/M	
5.	25650	Ankita Kharade	31/F	
6.	26396	Nimal Karale	56/F	
7.	26508	Simran Parade	41/F	
8.	26756	Swati Padelkar	41/F	
9.	26756	Nishal Gawali	24/F	
10.	27089	Dhigambar Ovle	44/M.	

Department of Prosthodontics

Work record

4. Crown Cementation

Sr. No.	OPD No.	Name of the Patient	Age/Sex	Signature of Staff
1.	24529	Dhiraj Nikumbh	35/M	
2	23490	Ravindra Tupe	54/M	
3.	24674	Nikhil Awade	34/M	
4	26660	Aniruddha Madake	28/M	
5.	27120	Baban Khandare	60/M	
6.	98930	Bhagwan Kakade	60/M	
7.	27222	Mangal Wahekar	54/F	
8.	26935	Vijay Takle	24/M	
9.	19010	Nikhil Sonawane	28/M	
10.	19613	Jyoti Ubale	50/F	

Record Book Details

Internship

Department of Conservative and Endodontics

Year 2018-19

DEPARTMENT OF CONSERVATIVE DENTISTRY & ENDODONTICS

CLINICAL WORK

Sr. NO	Date	OPD No.	Patient's Name.	Work Done	Staff sign
1	20/12/18	25651	Shweta Kokinde	class V restoratⁿ c̄ 34, 35	[signature]
2	20/12/18	25899	Mitesh Thakkar	Amalgam Restoratⁿ c̄ 48	[signature]
3.	21/12/18	21995	Kunal Tambe	POR done c̄ 47	[signature]
4.	26/12/18	28295	Priyanka Tapkir	GIC restoratⁿ c̄ 26	[signature]
5.	27/12/18	26057	Ashwini Chavan	Amalgam restoratⁿ c̄ 47	[signature]
6.	27/12/18	28257	Shubhangi Salve	Amalgam restoratⁿ c̄ 36	[signature]
7.	28/12/18	14433	Rohit Jadhav	Class I amalgam restoratⁿ c̄ 36	[signature]
8.	28/12/18	27289	Savita Kamble	~~ROC~~ POR c̄ 14	[signature]
9.	29/12/18	28469	Rama Kulkarni	POR done c̄ 47	[signature]
10.	31/12/18	28472	Anitesha Bhosale	Class I amalgam restoratⁿ c̄ 37.	[signature]
11.	31/12/18	28452	Urmila Ranjwan	Class I amalgam resto c̄ 47	[signature]

~~Sr No~~ Sr No	Date	OPD No.	Patient's Name	Work Done	Staff Sign
12	1/1/19	28411	Neelam Sharma	class II amalgam restorat^{n} c̄ 36	
13	1/1/19	27496	Sujata Kamble	class I amalgam restorat^{n} c̄ 25, 26	
14	1/1/19	26619	Tanvi Patil	RCO c̄ 13	
15	1/1/19	26362	Roma Aghave	class I Amalgam restorat^{n} c̄ 15	
16	2/1/19	88862	Balu Botre	GIC restorat^{n} c̄ 36	
17	2/1/19	28990	Ruchika Aage	ROC c̄ 12	
18	3/1/19	28301	Archana Bhilar	Temporary restorat^{n} c̄ 47	
19	3/1/19	26619	Tanvi Patil	BMP, obturation c̄ 13	
20	4/1/19	28716	Monali Pavale	GIC restorat^{n} c̄ 47 & Buccal subbase.	
21	4/1/19	28990	Ruchika Aage	BMP, obturation c̄ 12	
22	5/1/19	27564	Vishal Shrivasan	Caries exctract^{n} & temporary restorat^{n} c̄ 11, 14, 21	
23	5/1/19	28779	Bhausaheb Kadam	RCO c̄ 15	

Sr. No.	Date	OPD No.	Patient's Name	Work Done	Staff Sign.
24.	7/1/19	27564	Vishal Shrivasan	class I restorat^{n} ē 13	
25.	7/1/19	28677	Pushpa Bhosale	GIC restora^{n} ē 36	
26	7/1/19	80406	Shilpa Kale	class II restorat^{n} ē 16	
27.	8/1/19	28424	Sanjay Haibate	RCO ē 44	
28.	8/1/19	28779	Bhausaheb Kadam	BMP, obturation ē 15	
29.	10/1/19	85031	Ketan Jadhav	AO ē 11 & BMP	
30.	10/1/19	28424	Sanjay Haibate	BMP, obturation ē 44	
31	12/1/19	27565	Vishal Shrivastav	composite restorat^{n} ē 11, 21	

DEPARTMENT OF CONSERVATIVE DENTISTRY & ENDODONTICS.

classmate Date Page

EXTRACTED TEETH WORK DONE DURING POSTING

Sr. no.	Tooth no.	Step Performed	Staff Sign
1.	16	RC opening cleaning & shaping Obturation	
2.	27	RC opening cleaning & shaping obturation	
3.	36	RC opening cleaning & shaping obturation	
4.	26	RC opening cleaning & shaping obturation	
5.	46	RC opening cleaning & shaping Obturat.n	
6.	47	RC opening cleaning & shaping Obturation	

Sr. NO.	Tooth NO.	Steps Performed.	Staff sign.
7.	17.	RC opening cleaning & shaping obturation.	

Year 2019-20

DEPARTMENT OF CONSERVATIVE DENTISTRY & ENDODONTICS

CLINICAL WORK

Sr. No.	Date	OPD no.	Patient's Name	Work Done	Staff Sign
1.	13/1/20	32248	Aakash Bhapikar	IPC done $\bar{c}$ 27 composite done	
2.	13/1/20	40500	Sessical Kanaskar	Follow up done	
3.	20/1/20	38977	Saniya Bhor	RCO done $\bar{c}$ 44	
4.	20/1/20	42732	Megha Jagtap	Amalgam restoration done $\bar{c}$ 46	
5.	21/1/20	34093	Chandrashekar sakore	Composite POR $\bar{c}$ 45	
6.	21/1/20	21065	Mamta Sharma	Composite restoration 13, 24	
7.	22/1/20	41314	Lata Gawade	POR done $\bar{c}$ 36, composite done $\bar{c}$ 35	
8.	22/1/20	38977	Saniya Bhor	BMP & obstruction done $\bar{c}$ 44	

Scanned with OKEN Scanner

Sr. no.	Date	OPD no.	Patient's Name	Work Done	Staff Sign
9.	24/1/20	41810	Sajida Ali	Follow up done	
10.	24/1/20	44152	Nalini Kadam	RCT done $\overline{2}$ 11	
11.	25/1/20	46500	Jessica Kavaskar	Caries excavation, GIC base & composite restoration done $\overline{2}$ 37	
12	25/1/20	44792	Aslwon Kumar	Temporary restoration $\overline{2}$ 36	
13.	25/1/20	43570	Zeenat Shaikh	follow up done.	
14.	27/1/20	42732	Megha Jagtap	Class II (Disto occlusal) composite $\overline{2}$ 46	
15.	27/1/20	44152	Nalini Kadam	BMP & obturation done $\overline{2}$ 11	
16.	27/1/20	38087	Anjum Shaikh	follow up done	
17.	27/1/20	40750	Malindra Shirsat	follow up done	

Scanned with OKEN Scanner

Sr. no	Date	OPD. No	Patient's Name	Work done	Staff sign
18.	27/1/20	42732	Megha Jagtap	composite $\overline{6}$	
19.	28/1/20	18956	Pinky Chavan	composite $\overline{c}$ 36	
20.	29/1/20	40809	Sudhir Kumar	Temporary cementation $\overline{c}$ 26	
21	30/1/20	87354	Dasharath Tarde	Composite restoration $\overline{c}$ 15	
22	30/1/20	44416	Sandeep Sudke	Composite restoration $\overline{c}$ 37	
23.	30/1/20	41525	Priya Chandarkar	follow up done	
4.	30/1/20	18956	Pinky Chavan	follow up done	
.	6/2/20	44803	Mumtaj Shaikh	Amalgam restoration done $\overline{c}$ 37	

Scanned with OKEN Scanner

Srno.	Date	OPD.NO	Patient's Name	Work done.		
26.	6/3/20	45965	Prashant Bhigardive	Amalgam restoration done $\bar{c}$ 36		
27.	6/3/20	45965	Prashant Blingardine	Amalgam Restoration done $\bar{c}$ 37		
28.	22/10/20	48943	Santosh shinde	GIC done $\bar{c}$ 17		
29.	23/10/20	36871	Gurunath zkkalaki	POR done $\bar{c}$ 26		
30.	7/12/20	56609	Najakat shaikh	IPC $\bar{c}$ 36 done		
31.	8/12/20	56042	Parvati sharma	follow up done		
32.	8/12/20	46479	majuri veer	GIC restoration done $\bar{c}$ 37		
33.	9/12/20	56163	Tanuja Jadhav	IPC done $\bar{c}$ 36		

Scanned with OKEN Scanner

Sr.no	Date	OPD. NO	Patient's Name	work done	Staff sign
34.	10/12/20	56163	Tanuja Jadhav	IPC done ☐ 26	
35.	10/12/20	56695	Sneha Gursale	GIC done ☐ 27	
36.	12/12/20	56959	Pratik Kuandave	IPC ☐ 36 done	
37.	12/12/20	57090	Kanifnath Kajale	POR ☐ 47 done	
38.	12/12/20	18587	Hemlata Gholive	IPC done ☐ 37	
39.	14/12/20	56959	Pratik Kuandaave	Caries excavation ☐ 46 temporary restoration given.	
40.	23/12/20	56959	Pratik Kuandave	IPC doue ☐ 17	
41.	23/12/20	36862	Lata Salve	follow up done.	
42	24/12/20	~~57928 Madhuri~~	Madhuri Lathande	follow up done	

Scanned with OKEN Scanner

Department of CONSERVATIVE DENTISTRY & ENDODONTICS

classmate Date Page

Extracted Teeth Work Done During Posting.

Sr. NO	Tooth no	step Performed	staff sign
1.	26	RC opening, cleaning & shaping, obturation	
2.	16	RC opening, cleaning & shaping, obturation	
3.	47	RC opening, cleaning & shaping, obturation	
4	36	RC opening, cleaning & shaping, obturation	
5	27	RC opening, cleaning & shaping, obturation	
6	17	RC, opening, cleaning & shaping, obturation	
7.	47	RC opening cleaning & shaping, obturation	

Scanned with OKEN Scanner

Year

2020-21

DEPARTMENT OF ENDODONTICS & CONSERVATIVE DENTISTRY

CLINICAL WORK

Sr no.	Date	OPD no.	Patient's name	Work Done	staff sign
1>	1/12/20	49697	Vidhyani Kumbhar	GIC $\bar{c}$ ~~+7~~ done	
2>	1/12/20	39671	Pradeep Magdum	GIC $\bar{c}$ ~~+6~~ done	
3>	5/12/20	39671	Pradeep Magdum	IPC done $\bar{c}$ ~~+6~~	
4>	9/12/20	55364	Satish Unde	GIC done $\bar{c}$ ~~5+~~	
5>	10/12/20	56892	Nikita Shotn	RCO done $\bar{c}$ ~~4+~~	
6>	11/12/20	57015	Ashwini Rao	Caries excava° & temporary resto	
7>	11/12/20	561212	Alka Patil	POR $\bar{c}$ ~~+4~~ done	
8>	12/12/20	57090	Kanifnath Kajale	POR $\bar{c}$ ~~7+~~ done	
9>	12/12/20	56610	Lakshmi Loknar	GIC done $\bar{c}$ ~~6+~~	
10>	12/12/20	56892	Nikita Shotn	BMP & obtura° done $\bar{c}$ ~~4+~~	
11>	14/12/20	57072	Vikas Gawade	IPC $\bar{c}$ ~~7+~~	
12>	23/12/20	45484	Shashikant Thorat	GIC restor° done ~~+6~~	
13>	23/12/20	55825	Suresh Khaire	RCO done $\bar{c}$ ~~+3~~	

Sr.no.	Date	OPD no.	Patient's name	Work Done	Staff sign.
14.>	26/12/20	55825.	Suresh Kharse	BMP & obturation ~~13~~	
15.>	1/1/21	28760	Sandeep Gore	POR ~~17~~	
16.>					

DEPARTMENT OF CONSERVATIVE DENTISTRY & ENDODONTICS

EXTRACTED TEETH WORK DONE DURING POSTING

Sr.No.	Tooth no.	Steps performed	Staff sign
1>	47	RC opening Cleaning & Shaping Obtura	
2>	36	RC opening Cleaning & Shaping Obtura	
3>	16	RC opening Cleaning & shaping Obtura	

Year

2021-22

DEPARTMENT OF ...
DENTISTRY & ENDODONTICS.

CLINICAL WORK.

Sr. No.	Date	OPD No.	Patient's Name	Work Done	Staff sign
1	11/2/21	56047	Gorakhnath mahale	GIC restoratⁿ c̄ 14, 42, 44	
2	15/2/21	61697	Janardhan Parab	IPC done c̄ 16	
3.	16/2/21	35563	Krishna Patel.	POR c̄ 37.	
4.	23/2/21	61952	Darshana Jadhav	Indirect pulp capping c̄ 46	
5	1/3/21	58954	Ramesh mungse	caries excavatⁿ, CaOH, GIC base, composite restoratⁿ c̄ 16.	
6.	3/3/21	47948	CD singh.	POR c̄ 43.	
7.	4/3/21	32305	Sujata Bansode	POR c̄ 46.	
8.	6/3/21	18337	Javed Pathan	composite restoratⁿ c̄ 46.	
9	6/3/21	53049	Simran mule	ROC c̄ 13.	
10	9/3/21	53049	Simran Mule	BMP, obturatⁿ c̄ 13.	
11.	10/3/21	62382	Alka Marathe.	IPC c̄ 25.	
12.	10/3/21	56800.	Deep marathe.	ROC c̄ 12.	
13.	13/3/21	60359	Poonam Agrawal.	Amalgam Restoratⁿ c̄ 47.	

Sr. No.	Date	OPD NO	Patient's Name	Work Done	Staff Sign
14.	13/3/21	45347	Mayur Gaikwad	POR c 15	
15.	13/3/21	56800	Deep Marathe	BMP, Obturat^{n} c 12	
16.	15/3/21	60421	Ruchika Dane	POR done	
17.	17/3/21	60637	Shridharan Nantiyar	GIC restorat^{n} c 15, 24, 25, 35, 46	
18	17/3/21	45596	Mansi Mall.		
19	18/3/21	56332	Tanishka Murkute	~~ROT~~ RCO c 44.	
20	18/3/21	62382	Alka Marathe	POR c 16	
21.	18/3/21	61183	Madhuka Pawar	caries excavat^{n} c 37	
22.	20/3/21	63836	Chhabutai Harale	Buccal pit composite c 47	
				composite restorat^{n} done.	
23.	20/3/21	45596	Mansi Mall	BMP, obturat^{n} c 44	
24	23/3/21	63419	Pratap Shinde	caries excavat^{n} & evaluat^{n} c 15	
25	24/3/21	63159	Prashant Gaikwad	BMP done c 24	
26	25/3/21	62398	Taibunisa Siddique	composite restorat^{n} c 36	

Sr. No.	Date	OPD No.	Patient Name	Work done	Staff sign
27	25/3/21	63045	Amit Shukle	composite restoration c 17	
28	26/3/21	63159	Prashant Gaikwad	Obturation c 14	
29	27/3/21	63410	Kisan Shirurkar	comp restoration c 15, 16	
30	27/3/21	63238	rushal chauraisia	comp. restoration c 24	

DEPARTMENT OF CONSERVATIVE DENTISTRY & ENDODONTICS

EXTRACTED TEETH WORK DONE DURING POSTING.

Sr. No.	Tooth No.	steps performed	Staff sign.
1)	16	RC opening cleaning & shaping obturation	
2)	47	RC opening cleaning & shaping obturation	
3)	36	RC opening cleaning & shaping obturation.	

Year 2022-23

DEPARTMENT OF CONSERVATIVE DENTISTRY & ENDODONTICS

CLINICAL WORK

Sr.No.	Date	OPD No.	Patient's Name	Work Done	Staff sign
1.	10/5/22	48527	Dilip Thakre	composite restorat^{n} ē 27,28	
2.	17/5/22	94365	Anika Darade	Obturation done ē 45	
3.	17/5/22	92476	Kamalakar Karande	Access opening & WL taken ē 25.	
4.	18/5/22	92476	Kamalakar Karande	BMP done ē 25	
5.	20/5/22	94818	~~Arya~~ Ajay Magar	composite restorat^{n} ē 46.	
6.	23/5/22	92476	Kamlakar Karande	Obturation done ē 25	
7.	23/5/22	94365	Anika Darade	Follow up done.	
8.	24/5/22	82689	Surekha Andhre	Follow up done.	
9.	30/5/22	92476	Kamalakar Karande	POR done ē 25	
10.	30/5/22	94159	Kanchan Kothambire	~~TMP~~ Temp Given ē 16,15.	
11.	30/5/22	95635	Venket Dongare	AO & BMP done ē 21	
12.	01/6/22	32104	Gauri Khandue	Follow up done	
				Follow up done	

Sr. No.	Date	OPD No.	Patient's Name	Work done	Staff sign
13.	01/6/22	95979	Sai Palande	AO & working length ☐ 15	
14.	02/6/22	92127	Kapileshwar Pawar	AO Done ☐ 16	
15.	02/6/22	94159	Kanchan Kothambire	BMP ☐ 21	
16.	03/6/22	92127	Kapileshwar Pawar	BMP ☐ 16	
17.	03/6/22	95979	Sai Palande	BMP, Obturation ☐ 15	
18.	03/6/22	93905	Priyanka Dangmali	Follow up Done	
19.	04/6/22	92476	Kamlakar Karande	Temporary Restoration 15, 16	
20.	04/6/22	92127	Kapileshwar Pawar	Obturation ☐ 16	
21.	04/6/22	89226	Bhuwaneshwar Prasad	Follow up done	
22.	04/6/22	84315	Kiran Kalkume	AO ☐ 26	
23.	04/6/22	89535	Manojkumar Mane	AO ☐ 45	
24.	06/6/22	95438	Kalpana Wani	PCO ☐ 26, 28 AO ☐ 41, 42	
25.	06/6/22	95979	Sai Palande	POR ☐ 15	

Sr. No	Date	OPD No.	Patient's Name	Work Done	Staff sign
26.	6/6/22	96406	Jayshree karje	AO C̄ 36.	
27.	6/6/22	96412	Sunanda londhe	AO, BMP C̄ 24.	
28.	6/6/22	93168	Jyotsana sonawane	class II. Restorat^{n} C̄ 46 (composite)	
29.	7/6/22	94159	Kanchan kathambiri	Irrigation C̄ 21	
30.	7/6/22	89535	manoj kumar mule	BMP C̄ 45	
31.	7/6/22	84315	kiran kalkumbe.	Work length C̄ 26.	
32.	7/6/22	96406	Jayshree karje	Irrigat^{n} done, Temporary given C̄ ~~46~~ 36.	
33.	7/6/22	87218	Kashish ware	RCO C̄ 12.	
34.	8/6/22	91636 ~~95868~~	Shubhangi khujur	AO, BMP C 46.	
35.	8/6/22	74364	Rahul Patil	RCO C̄ 14.	
36.	9/6/22	87218	kashish ware	BMP, obturat^{n} C̄ 12	
37.	10/6/22	96406	Jayshree karje	BMP C̄ 36	
38.	10/6/22	89535	manoj kumar	obturat^{n} & PDR C̄ 45	

Sr. No	Date	OPD No.	Patient's Name	Work Done	Staff Sign
39	10/6/22	746342	Rahul Patil	BMP, obturat^{n} ₹ 14	
40	11/6/22	84315	Kiran Kalkumbe	BMP & obturat^{n} ₹ 26	
41	11/6/22	94365	Anita Darade	obturat^{n} & POR ₹ 46	
42	11/6/22	96412	Sunanda Londhe	POR ₹ 24	
43	14/6/22	95632	mande Gharsange	Access opening ₹ 37	
44	14/6/22	84392	Sahil Chavan	RCO ₹ 13	
45	17/6/22	96406	Jayshree karje	obturat^{n}, POR ₹ 36	
46	17/6/22	92127	~~Kapti~~ Kapileshwar Pawar	POR ₹ 26	
47	17/6/22	96287	Pravin Kamble	composite Restorat^{n} ₹ 11	
48	17/6/22	82678	Rahul Tapker	obturation ₹ 26	
49	17/6/22	84392	Sahil Chavan	BMP, obturat^{n} ₹ 13	
50	20/6/22	97237	Atharva Bhosale	AO ₹ 46	
51	20/6/22	97241	Shivam Vishwakarma	INL ₹ 37	
52	20/6/22	97477	Sayali Parkhe	Followup	

Sr. No.	Date.	OPD No.	Patient's Name	Work Done	Staff sign
53.	~~20/6~~ 21/6/22	97737	manoj Gurjal	IPC ☐ 27	
54.	21/6/22	93605	Shyam Giri	composite ☐ 36, 46	
55.	21/6/22	97769	Kruti ka Lambe	Follow up.	
56.	27/6/22	97596	Subhas Takle	RCO ☐ 44.	
57.	28/6/22	98258	Priya mukharjee	RCO ☐ 24	
58.	29/6/22	97596	Subhas Takle	BMP, obturat^ ☐ 44	
59.	30/6/22	98258	Priya mucharjee	BMP, obturat^ ☐ 24	

DEPARTMENT OF CONSERVATIVE DENTISTRY
& ENDODONTICS

EXTRACTED TEETH WORK DONE DURING POSTING

Sl.NO	Tooth No	Step Performed	Staff Sign
1.	16	RC opening cleaning & Shaping obturat^{n}	
2.	36	RC opening cleaning & Shaping obturat^{n}	
3.	27.	RC opening cleaning & Shaping obturat^{n}	
4.	46.	RC opening cleaning & Shaping obturat^{n}	
5	26.	RC opening cleaning & shaping obturat^{n}	
6.	47.	RC opening cleaning & Shaping obturat^{n}	
7.	17.	RC opening cleaning & Shaping obturat^{n}	

Record Book Details

Internship

Department of Pedodontics and Preventive Dentistry

D Y PATIL DENTAL SCHOOL

Department of Pediatric Dentistry

This is to certify that **Intern** Roll No ----3---- named Mr/Mrs.---Swaraj Ashte---

has satisfactorily completed the work of this department as per the DCI guidelines.

I hereby give him/her the certification of internship completion from this department

Date:

Signature

Head of the Department

Department of Pediatric Dentistry

PROFESSOR & HEAD
Dept. of Paediatric & Preventive Dentistry
D Y Patil Dental School
D Y Patil Knowledge City
Charoli (Bk), Via Lohegaon, Pune - 412105.

Work done Interns

Sl No	Date	OPD No	Name of Patient	Treatment/Outreach Program	Sign
1	2/8/22	88328	Mahaar Kore	Full mouth scaling	Raheja
2	2/8/22	88357	Sagnath Garma	GIC restoration c̄46	[illegible]
3	2/8/22	101699	Pyush Parkhe	RCT c̄ 25	[illegible]
4	3/8/22	101407	Ariya Pawar	irrigation and temporary given	[illegible]
3	3/8/22	93210	Nitin choudary	obturation c̄46	[illegible]
4	3/8/22	87728	Lalita Kondke	GIC c̄ 85	[illegible]
5	5/8/22	101225	Harshal Gaikwad	composite c̄ 23,24	[illegible]
6	5/8/22	77043	Aansh Pawar	IPC c̄ 36	Raheja
7	6/8/22	100203	Swara Dhawale	irrigation c̄ 46	Raheja
8	6/8/22	87313	Sayyad Maksad	AO c̄ 55	[illegible]
9	8/8/22	102274	Arush Ghaimukite	PFS done	[illegible]
10	8/8/22	102407	Chandani Nat	PFS done	Raheja
11	8/8/22	77562	Sachin mourya	obturation c̄65	[illegible]
12	8/8/22	77548	Ajar Waghmare	POR c̄ 54	[illegible]
13	9/8/22	102306	Rugvedi Jagtap	PFS done	[illegible]
14	10/8/22	71584	Irupti Naigada	GIC c̄ 65	[illegible]
15	11/8/22	99331	Shamtara Parab	AO c̄ 54	Raheja
16	12/8/22	102606	Nidhi Patil	Scaling done	Raheja
17	12/8/22	87358	Anjana Baude	GIC c̄ 75	Raheja
18	13/8/22	100673	Chaitali Bhole	composite c̄46	[illegible]
19	17/8/22	102816	Darshika Joshi	GIC c̄ 54	[illegible]
20	18/8/22	57008	Kaustaub Gade	GIC c̄ 61,62	[illegible]
21	19/8/22	102133	Rita Gupta	composite c̄46	[illegible]

Record Book Details

Internship

Department of Public Health Dentsitry

D Y PATIL DENTAL SCHOOL

Department of Public Health Dentistry

This is to certify that Intern named Mr/Ms Ajmera krishna. ,

Roll No 1 has satisfactorily completed the work of this department as per the DCI guidelines.

I hereby give him/her the certification of internship completion from this department.

Date: 19/12/22

PROFESSOR & HEAD
Dept. of Public Health Dentistry
D Y Patil Dental School
D Y Patil Knowledge City
Charoli (Bk), Via Lohegaon, Pune - 412105

Head of the Department

Department of Public Health Dentistry

ASSIGNED CLINICAL EXERCISES AND OUTREACH PROGRAM DURING INTERNSHIP

1. Organizing Dental Camp	5
2. Participation in Dental Camp	10
3. Satellite Center Charholi PHC	5
4. Rajiv Gandhi Hospital Posting	5
5. Comphrensive Dental Care in Integrated Clinic	10

OUTREACH ACTIVITIES

No of camps organised:

Sr No	Date	Venue
1.	19/11/22.	Sant Tukaram Maharaj Mandir.
2.	23/11/22.	Trinity Sheal Dighi.
3.	24/11/22.	Smart kids primary school.
4.	25/11/22	Akanksha Academy Lohegaon.
5.		
6.		
7.		
8.		
9.		
10.		

No of Camps Attended:

Sr No	Date	Venue
1.	19/11/22.	Sant Tukaram Maharaj Mandir.
2.	23/11/22.	Trinity Sheal Dighi.
3.	24/11/22.	Smart kids primary school.
4.	25/11/22.	Akansha Academy Lohegaon.
5.	30/11/22.	Santulan Bhavan Kharadi.
6.	1/12/22	Fun & fun preschool.
7.	3/12/22.	SS English Medium school.
8.		
9.		
10.		
11.		
12.		
13.		
14.		
15.		

Comphrensive Dental Care in Integrated Clinic

Sl No	Date	OPD No	Name of Patient	Treatment	Sign
1.	3/01/22	80192	Manisha Sonawane	Scaling	
2.	3/01/22	80193	Bapurao Harinwale	Scaling	
3.	5/01/22	80194	Monika Devkar	Extraction	
4.	5/01/22	80195	Adarsh Devkar	Extraction	
5.	5/01/22	80196	Janhavi kholam	Scaling	
6.	10/01/22	80197	Sushmakholam	Extraction	
7.	10/01/22	80198	Prakash Palkar	Oral prophylaxis	
8.	10/01/22	80263	Rutuja Pol	Scaling	
9.	10/01/22	80264	Nitin Jangale	Extraction	
10.	11/01/22	80265	Reshma Ingale	Scaling	
11.	11/01/22	80266	Ashis Dhiwar	Oral prophylaxis	
12.	11/01/22	80267	Sujit kalokhi	Extraction	
13.	13/01/22	80268	Jyoti Varma	Toothbrush demo	
14.	13/01/22	80269	Dinesh Sonar	Scaling	
15.	14/01/22	80270	Nikhil Gomase	Scaling	

D Y PATIL DENTAL SCHOOL

Department of Public Health Dentistry

This is to certify that Intern named Mr/Ms Ajrekar Iftisam.,

Roll No 2 has satisfactorily completed the work of this department as per the DCI guidelines.

I hereby give him/her the certification of internship completion from this department.

Date: 19/12/22

PROFESSOR & HEAD
Dept. of Public Health Dentistry
D Y Patil Dental School
D Y Patil Knowledge City
Charoli (Bk), Via Lohegaon, Pune - 412105

Head of the Department

Department of Public Health Dentistry

ASSIGNED CLINICAL EXERCISES AND OUTREACH PROGRAM DURING INTERNSHIP

1.	Organizing Dental Camp	5
2.	Participation in Dental Camp	10
3.	Satellite Center Charholi PHC	5
4.	Rajiv Gandhi Hospital Posting	5
5.	Comphrensive Dental Care in Integrated Clinic	10

OUTREACH ACTIVITIES

No of camps organised:

Sr No	Date	Venue
1.	25/11/22.	Akansha Academy Lohegaon.
2.	30/11/22	Santulan Bhavan Lakhadi
3.	1/12/22.	Fun & fun Preschool.
4.		
5.		
6.		
7.		
8.		
9.		
10.		

No of Camps Attended:

Sr No	Date	Venue
1.	19/11/22.	Sant Tukaram Maharaj Mandir.
2.	23/11/22.	Trinity school Dighi.
3.	24/11/22.	Smart kids Primary School.
4.	25/11/22.	Akansha Academy Lohegaon.
5.	30/11/22.	Santulan Bhavan Khandi.
6.	5/12/22.	Eyes school.
7.	6/12/22.	PHC Wagholi.
8.	9/12/22.	Trinity School Dighi.
9.		
10.		
11.		
12.		
13.		
14.		
15.		

Satellite Centre Postings

PHC Charholi

Sr No	Date	Signature
1.	2/10/22	
2.	7/10/22	
3.	11/10/22	
4.	16/10/22	
5.	19/10/22	
6.	26/10/22	
7.	1/11/22	
8.	5/11/22	

Late Shri Rajeev Gandhi Hospital, Yerwada

Sr No	Date	Signature
1.	7/11/22.	
2.	12/11/22.	
3.	16/11/22	
4.	21/11/22	
5.	27/11/22	
6.	2/12/22	
7.	5/12/22	
8.	7/12/22	
9.	11/12/22.	

Comphrensive Dental Care in Integrated Clinic

Sl No	Date	OPD No	Name of Patient	Treatment	Sign
1.	11/11/22	80335	Pankaj Kanlar	Scaling	
2.	11/11/22	80336	Malika Detroja	Extraction	
3.	11/11/22	80337	Pradeep Rave	Scaling	
4.	11/11/22	80338	Prachi Sharma	Oral prophylaxis	
5.	11/11/22	80339	Vasant Borat	scaling	
6.	11/11/22	80340	Alakanshi Mehta	Extraction	
7.	11/11/22	80341	Ashish Goswami	Scaling	
8.	12/11/22	80414	Pankaj Kadam	Scaling	
9.	12/11/22	80415	Sanita Deta	Extraction	
10.	12/11/22	80416	Sohan Gaikwad	Scaling	
11.					
12.					
13.					
14.					
15.					

D Y PATIL DENTAL SCHOOL

Department of Public Health Dentistry

This is to certify that Intern named Mr/Ms Agarkar Mrutyuja Vinod,

Roll No 1 has satisfactorily completed the work of this department as per the DCI guidelines.

I hereby give him/her the certification of internship completion from this department.

Date: 09/10/23

PROFESSOR & HEAD
Dept. of Public Health Dentistry
D Y Patil Dental School
D Y Patil Knowledge City
Charoli (Bk), Via Lohegaon, Pune - 412105

Head of the Department

Department of Public Health Dentistry

ASSIGNED CLINICAL EXERCISES AND OUTREACH PROGRAM DURING INTERNSHIP

1. Organizing Dental Camp	5
2. Participation in Dental Camp	10
3. Satellite Center Charholi PHC	5
4. Rajiv Gandhi Hospital Posting	5
5. Comphrensive Dental Care in Integrated Clinic	10

OUTREACH ACTIVITIES

No of camps organised:

Sr No	Date	Venue
1.	28/7/23	Ikids Paradise Preschool
2.	17/8/23	Time kids Dhanori
3.	5/9/23	Shining Star School.
4.		
5.		
6.		
7.		
8.		
9.		
10.		

No of Camps Attended:

Sr No	Date	Venue
1.	28/7/23	Ikids Paradise Preschool
2.	3/8/23	MMIT Lohegaon
3.	4/8/23	Bumble bee preprimary school
4.	7/8/23	~~Imma~~ Immanuel School
5.	17/8/23	Time kids Dhanori
6.	22/8/23	Tapas foundation
7.	24/8/23	Kidzenia Dhanori
8.	31/8/23	DY Patil International School
9.	2/9/23	Little sprout preschool
10.	5/9/23	Shinining star school
11.		
12.		
13.		
14.		
15.		

Satellite Centre Postings

PHC Charholi

Sr No	Date	Signature
1.	30/7/23	
2.	5/8/23	
3.	12/8/23	
4.	21/8/23	
5.	25/8/23	
6.	31/8/23	
7.	4/9/23	
8.	6/9/23	

Late Shri Rajeev Gandhi Hospital, Yerwada

Sr No	Date	Signature
1.	7/9/23	
2.	15/9/23	
3.	18/9/23	
4.	21/9/23	
5.	23/9/23	
6.	25/9/23	
7.	27/9/23	
8.	4/10/23	
9.	6/10/23	

Comphrensive Dental Care in Integrated Clinic

Sl No	Date	OPD No	Name of Patient	Treatment	Sign
1.	25/7/23	113315	Manihar Waseem	Scaling	
2.	28/7/23	131449	Siddhesh Patil	Extraction.	
3.	27/7/23	113321	Sumita Devi	Extraction	
4.	28/7/23	131450	Prajwal Patil	Extraction.	
5.	29/7/23	113268	Sunny Dalvi	Oral Prophylaxis	
6.	31/7/23	131452	Durgesh Sapkal	Scaling	
7.	1/8/23	113271	Omkar Dhotre	Extraction	
8.	2/8/23	131466	Sumedh Lokhande	Scaling	
9.	3/8/23	113273	Akash Sumindre.	Scaling	
10.	4/8/23	131471	Pranay Shinde	Scaling.	
11.	5/8/23	113275	Sachin Jadhav	Extraction	
12.	6/8/23	131415	Tanvi Jadhav	Scaling	
13.	7/8/23	133527	Kiran Devkar	Scaling	
14.	8/8/23	133528	Amruta Pawar	Extraction	
15.	9/8/23	133529	Sanjay Patil	Oral Prophylaxis	

D Y PATIL DENTAL SCHOOL

Department of Public Health Dentistry

This is to certify that Intern named Mr/Ms Aglave Sakshi Suresh,

Roll No 2 has satisfactorily completed the work of this department as per the DCI guidelines.

I hereby give him/her the certification of internship completion from this department.

Date: 9/10/23

PROFESSOR & HEAD
Dept. of Public Health Dentistry
D Y Patil Dental School
D Y Patil Knowledge City
Charoli (Bk), Via Lohegaon, Pune - 412105

Head of the Department

Department of Public Health Dentistry

ASSIGNED CLINICAL EXERCISES AND OUTREACH PROGRAM DURING INTERNSHIP

1.	Organizing Dental Camp	5
2.	Participation in Dental Camp	10
3.	Satellite Center Charholi PHC	5
4.	Rajiv Gandhi Hospital Posting	5
5.	Comphrensive Dental Care in Integrated Clinic	10

OUTREACH ACTIVITIES

No of camps organised:

Sr No	Date	Venue
1.	3/8/23	MMIT
2.	4/8/23	Bumble Bee preprimary School
3.	7/8/23	Immanual school.
4.		
5.		
6.		
7.		
8.		
9.		
10.		

No of Camps Attended:

Sr No	Date	Venue
1.	28/7/23	Ikids Paradise Preschool
2.	3/8/23	MMIT Lohegaon
3.	4/8/23	Bumble Bee preprimary school
4.	7/8/23	Immanual School
5.	17/8/23	Time kids Dhanori
6.	22/8/23	Tapas foundation.
7.	24/8/23	Kidzenia Dhanori
8.	31/8/23	DY Patil International School
9.	2/9/23	Little sprout preschool
10.	5/9/23	Shinning star School.
11.		
12.		
13.		
14.		
15.		

Satellite Centre Postings

PHC Charholi

Sr No	Date	Signature
1.	30/7/23	
2.	5/8/23	
3.	12/8/23	
4.	21/8/23	
5.	25/8/23	
6.	31/8/23	
7.	4/9/23	
8.	6/9/23	

Late Shri Rajeev Gandhi Hospital, Yerwada

Sr No	Date	Signature
1.	7/9/23	
2.	15/9/23	
3.	18/9/23	
4.	21/9/23	
5.	23/9/23	
6.	25/9/23	
7.	27/9/23	
8.	4/10/23	
9.	6/10/23	

Comphrensive Dental Care in Integrated Clinic

Sl No	Date	OPD No	Name of Patient	Treatment	Sign
1.	25/7/23	133530	Chandama Naik	Scaling	
2.	26/7/23	133531	Anuj Kawale	Extraction	
3.	27/7/23	133532	Anjali Shelke	Extraction	
4.	28/7/23	133533	Amar Barwase	Extraction	
5.	29/7/23	133534	Pooja Gawane.	Extraction	
6.	31/7/23	133535	Dhanashree Mane	Scaling	
7.	1/8/23	133536	Reshma Bhagat.	Extraction	
8.	2/8/23	130075	Tejal Kadam	Scaling	
9.	3/8/23	127376	Bharat Shahane.	Scaling	
10.	4/8/23	130085	Dipak rathod	Scaling	
11.	5/8/23	127372	Shivaji Birajdar.	Scaling	
12.	6/8/23	130093	Kavita Patil	Scaling	
13.	7/8/23	127364	Sunil Pawar	Extraction	
14.	8/8/23	130097	Sangita Pawar	Extraction	
15.	9/8/23	127364	Anand Shendge.	Scaling	

Satellite Centre Postings

PHC Charholi

Sr No	Date	Signature
1.	2/10/22	
2.	4/10/22.	
3.	6/10/22	
4.	7/10/22	
5.	8/10/22.	
6.	9/10/22	
7.	12/10/22.	
8.	19/10/22	

Late Shri Rajeev Gandhi Hospital, Yerwada

Sr No	Date	Signature
1.	21/10/22	
2.	24/10/22	
3.	28/10/22.	
4.	29/10/22	
5.	2/11/22	
6.	3/11/22.	
7.	7/11/22.	
8.	9/11/22	
9.	11/11/22	

List of Students Trained

List of Students Trained

Comprehensive/ Integrated Clinic

D Y PATIL DENTAL SCHOOL

D Y Patil Knowledge City, Charholi (Budruk), Lohegaon, Pune – 412105.

Department of Public Health Dentistry

Interns' Schedule

BATCH 2022-23

Dates	Satellite centre, PHC, Charholi	Department OPD/ Camp	Satellite centre, Rajeev Gandhi Hospital, Yerwada
10/10/22-09/11/22	BATCH C	BATCH B	BATCH L
10/11/22-09/12/22	BATCH J	BATCH C,L	BATCH Q
10/12/22-09/01/23	BATCH L	BATCH D,J	BATCH C
10/01/23-09/02/23	BATCH K	BATCH Q,E	BATCH J,D
10/02/23-09/03/23	BATCH D ,Q	BATCH K,	BATCH E
10/09/23-09/10/23	BATCH A	BATCH B,N	BATCH I
10/03/23-09/04/23	BATCH E,F	BATCH O,P	BATCH K
10/04/23-09/05/23	BATCH P	BATCH F,G	BATCH O
10/05/23-09/06/23	BATCH G	BATCH M,O	BATCH F
10/06/23-09/07/23	BATCH M	BATCH P,H	BATCH G
10/07/23-09/08/23	BATCH H,	BATCH M,N	BATCH A
10/08/23-09/09/23	BATCH B	BATCH A,I	BATCH N

ROLL NO OF INTERNS FOR CLINICAL POSTINGS ARE AS FOLLOWS:

BATCH A- ROLL NO 1-2 BATCH B- ROLL NO 3-4 BATCH C- ROLL NO 5-6
BATCH D- ROLL NO 7-8 BATCH E- ROLL NO 9-10 BATCH F- ROLL NO 11-12
BATCH G- ROLL NO 13-14 BATCH H- ROLL NO 15-16 BATCH I- ROLL NO 17-18

D Y PATIL DENTAL SCHOOL

D Y Patil Knowledge City, Charholi (Budruk), Lohegaon, Pune – 412105.

Department of Public Health Dentistry

Interns' Schedule

BATCH 2021-22

Dates	Satellite centre, PHC, Charholi	Department OPD/ Camp	Satellite centre, Rajeev Gandhi Hospital, Yerwada
20/12/21-18/1/22	BATCH C	BATCH B	BATCH L
19/1/22-17/2/22	BATCH J	BATCH C,L	BATCH Q
18/2/22-19/3/22	BATCH L	BATCH D,J	BATCH C
20/3/22-18/4/22	BATCH K	BATCH Q,E	BATCH J
19/4/22-18/5/22	BATCH D ,Q	BATCH K,	BATCH E
19/5/22-17/6/22	BATCH E,F	BATCH O,P	BATCH K
18/6/22-17/7/22	BATCH P	BATCH F,G	BATCH O
18/7/22-16/8/22	BATCH G	BATCH M,O	BATCH F
17/8/22-16/9/22	BATCH M	BATCH P,H	BATCH G
17/9/22-17/10/22	BATCH H,	BATCH M,N	BATCH A
18/10/22-19/11/22	BATCH B	BATCH A,I	BATCH N
20/11/22-19/12/22	BATCH A	BATCH B,N	BATCH I

ROLL NO OF INTERNS FOR CLINICAL POSTINGS ARE AS FOLLOWS

BATCH A-Roll no. 1-4
BATCH B-Roll no. 5-9
BATCH C-Roll no. 10 14
BATCH D-Roll no. 15-18
BATCH E – Roll no. 19-23
BATCH F-Roll no. 24-28
BATCH G-Roll no. 29-33
BATCH H-Roll no. 34-37
BATCH I-Roll no. 38-42
BATCH J-Roll no. 43-47
BATCH K-Roll no. 48-52
BATCH L-Roll no. 53-56
BATCH M-Roll no. 57-60
BATCH N-Roll no. 61-65
BATCH O-Roll no. 66-70
BATCH P-Roll no. 71-75

D Y PATIL DENTAL SCHOOL

D Y Patil Knowledge City, Charholi (Budruk), Lohegaon, Pune – 412105.

Department of Public Health Dentistry

Interns' Schedule

BATCH 2020-21

Dates	Satellite centre, PHC, Charholi	Department OPD/ Camp	Satellite centre, Rajeev Gandhi Hospital, Yerwada
28/12/20-26/1/21	BATCH C	BATCH L	BATCH B
27/1/21-25/2/21	BATCH L	BATCH J	BATCH C
26/2/21-28/3/21	BATCH J	BATCH C, D	BATCH L
29/3/21-27/4/21	BATCH D	BATCH K,E	BATCH J
28/4/21-27/5/21	BATCH E	BATCH D	BATCH K
28/5/21-26/6/21	BATCH K	BATCH F	BATCH E
27/6/21-26/7/21	BATCH G	BATCH G,F	BATCH F
27/7/21-25/8/21	BATCH F	BATCH M	BATCH F
26/8/21-26/9/21	BATCH H	BATCH G	BATCH M
27/9/21-27/10/21	BATCH M	BATCH H,I	BATCH A
28/10/21-27/10/21	BATCH A	BATCH B	BATCH I
28/11/21-27/12/21	BATCH I	BATCH A	BATCH B

ROLL NO OF INTERNS FOR CLINICAL POSTINGS ARE AS FOLLOWS:

BATCH A- ROLL NO 1-5
BATCH B- ROLL NO 6-10 BATCH C- ROLL NO 11-15
BATCH D- ROLL NO 16-20
BATCH E- ROLL NO 21-25 BATCH F- ROLL NO 26-30
BATCH G- ROLL NO 31-35
BATCH H- ROLL NO 36-40 BATCH I- ROLL NO 41-45
BATCH J- ROLL NO 46-50
BATCH K- ROLL NO 51-55 BATCH L- ROLL NO 56-60
BATCH M- ROLL NO 61-64

D Y PATIL DENTAL SCHOOL

D Y Patil Knowledge City, Charholi (Budruk), Lohegaon, Pune – 412105.

Department of Public Health Dentistry

Interns' Schedule

BATCH 2019-20

Dates	Satellite centre, PHC, Charholi	Department OPD/ Camp	Satellite centre, Rajeev Gandhi Hospital, Yerwada
16.09.19-15.10.19	BATCH C	BATCH B	BATCH L
16.10.19-16.11.19	BATCH J	BATCH L	BATCH C
17.11.19-16.12.19	BATCH L	BATCH C/J	BATCH D
17.12.19-15.01.20	BATCH D	BATCH E/K	BATCH J
16.01.20-14.02.20	BATCH E	BATCH D/O	BATCH K
15.02.20-15.03.20	BATCH K	BATCH F/N/O	BATCH E
16.03.20-15.04.20	BATCH N	BATCH G/F	BATCH O
16.04.20-15.05.20	BATCH F	BATCH H/M/N	BATCH G
16.05.20-14.06.20	BATCH G	BATCH M/P	BATCH H
15.06.20-14.07.20	BATCH P	BATCH A/I	BATCH M
15.07.20-13.08.20	BATCH A	BATCH P/B	BATCH I
14.08.20-15.09.20	BATCH B	BATCH I	BATCH A

ROLL NO OF INTERNS FOR CLINICAL POSTINGS ARE AS FOLLOWS:

BATCH A- ROLL NO 1-5 BATCH B- ROLL NO 6-10 BATCH C- ROLL NO 11-15
BATCH D- ROLL NO 16-20 BATCH E- ROLL NO 21-25 BATCH F- ROLL NO 26-30
BATCH G- ROLL NO 31-35 BATCH H- ROLL NO 36-40 BATCH I- ROLL NO 41-45
BATCH J- ROLL NO 46-50 BATCH K- ROLL NO 51-55 BATCH L- ROLL NO 56-60
BATCH M- ROLL NO 61-65 BATCH N- ROLL NO 66-70 BATCH O- ROLL NO 71-75
BATCH P- ROLL NO 76-81 BATCH Q- ROLL NO 82-87

D Y PATIL DENTAL SCHOOL

D Y Patil Knowledge City, Charholi (Budruk), Lohegaon, Pune – 412105.

Department of Public Health Dentistry

Interns' Schedule

BATCH 2018-19

Dates	Satellite centre, PHC, Charholi & Satellite centre, Rajeev Gandhi Hospital, Yerwada	Department OPD/ Camp
01/09/18-30/09/18	MUSKAN	KAJAL
1/10/18-31/10/18	KAJAL	MUSKAN
1/11/18-30/11/18	JAYSHREE,KAJAL	SHRUTIKA,NEHA
1/12/18-31/12/18	SHRUTIKA,NEHA	JAYSHREE,KAJAL
1/1/19-31/1/19	PRIYANKA ,KAJAL	VARUNA,JAYASHREE
1/2/19-28/2/19	MARUTI,VARUNA	VIJAYALAKSMI, PRIYANKA
1/3/19-31/3/19	VISHWA, VIJAYALAKSMI	PRIYA, MARUTI
1/4/19-30/4/19	NEELAM, MARUTI	RUCHIKA ,VISHWA
1/5/19-31/5/19	RUCHIKA ,PURVA	NEELAM,PREETI
1/6/19-30/6/19	DEVYANI, PREETI	JASWINDER, PURVA
1/7/19-31/7/19	JASWINDER	DEVYANI
1/8/19-31/8/19	DEVYANI	JASWINDER

ROLL NO OF INTERNS FOR CLINICAL POSTINGS ARE AS FOLLOWS:

BATCH A- ROLL NO 1-5 BATCH B- ROLL NO 6-10 BATCH C- ROLL NO 11-15
BATCH D- ROLL NO 16-20 BATCH E- ROLL NO 21-25 BATCH F- ROLL NO 26-30
BATCH G- ROLL NO 31-35 BATCH H- ROLL NO 36-40 BATCH I- ROLL NO 41-45
BATCH J- ROLL NO 46-50 BATCH K- ROLL NO 51-55 BATCH L- ROLL NO 56-60
BATCH M- ROLL NO 61-65 BATCH N- ROLL NO 66-70 BATCH O- ROLL NO 71-75
BATCH P- ROLL NO 76-80 BATCH Q- ROLL NO 81-87

List of Students Trained

Implant Clinic

List of Students Trained in Dental Implant Clinic

Sr. No.	Name.	Date of postings.
1.	Neha.	16/9/18 - 30/9/18.
2.	Shrutika	1/9/18 - 15/9/18.
3.	Kajol	16/10/18 - 31/10/18
4.	Jalyashree.	1/10/18 - 15/10/18.
5.	Priyanka	16/11/18 - 30/11/18.
6.	Maniti	16/12/18 - 30/12/18.
7.	Vanna	1/12/18 - 15/12/18.
8.	Vishwa	16/1/19 - 30/1/19.
9.	Vijayalakshmi	1/1/19 - 15/1/19.
10.	Neelam	16/2/19 - 28/2/19.
11.	Priya.	1/2/19 - 15/2/19.
12.	Punia	16/3/19 - 31/3/19.
13.	Ruchika.	1/3/19 - 15/3/19.
14.	Devyani	1/5/19 - 15/5/19.
15.	Devyani	16/4/19 - 30/4/19.
16.	Preeti	1/4/19 - 15/4/19.
17.	Jaswender	16/5/19 - 31/5/19.
18.	Jaswander	1/6/19 - 15/6/19.
19.	Muskan	16/7/19 - 31/7/19.
20.	Kajal.	16/8/19 - 31/8/19.
21.	Kajol.	1/8/19 - 15/8/19.

For Head

Head of Department of Prosthodontics
DY PATIL DENTAL SCHOOL
DY Patil Knowledge City, Charholi
Lohegaon, Pune - 412105

Sr.No.	Name.	Date of Posting.
1.	Abnave Tanishka.	16/9/19 - 30/9/19.
2.	Bhujbal Sanjana.	16/10/19 - 1/11/19.
3.	Bivalkar Ruchi	16/10/19 - 1/11/19.
4.	Baldota Shreya.	1/10/19 - 15/10/19.
5.	Chaudhari Vaishnavi	17/11/19 - 1/12/19.
6.	Kamble Gauri	2/11/19 - 16/11/19.
7.	Chordia Mayuri	17/12/19 - 31/12/19.
8.	Chinchalkar Anuja.	2/12/19 - 16/12/19.
9.	Chavan Akshay	2/12/19 - 16/12/19.
10.	Chaudhary Mehul.	2/12/19 - 16/12/19.
11.	Dhole Shrutika.	31/1/20 - 14/2/20.
12.	Dharmadhikari Shivani	16/1/20 - 30/1/20.
13.	Dalal Nisha	16/1/20 - 30/1/20.
14.	Dabral Utkarsha.	16/1/20 - 30/1/20.
15.	Dabade Dhanashree	1/1/20 - 15/1/20.
16.	Durge Sejal.	15/2/20 - 29/2/20.
17.	Ganje Apurva	31/3/20 - 15/4/20.
18.	Garnate Swapnesha	1/3/20 - 15/3/20.
19.	Gaikwad Anuja	1/3/20 - 15/3/20.
20.	Gandhi Amar.	16/3/20 - 30/3/20.
21.	Gawde Pratiksha	16/4/20 - 30/4/20.
22.	Gatkal Deepti	16/4/20 - 30/4/20.
23.	Garud Juri	16/4/20 - 30/4/20.
24.	Hanye Shrushti	31/5/20 - 14/6/20.
25.	Gundap Gayatri	31/5/20 - 14/6/20.
26.	Gogawle Rasika.	31/5/20 - 14/6/20
27.	Ghulne Divya.	16/5/20 - 30/5/20.
28.	Ghogare Priyanka.	1/5/20 - 15/5/20.
29.	Jadhav Shivani	30/6/20 - 14/7/20.
30.	Jagole Swati	15/6/20 - 29/6/20.

Head of Department of Prosthodontics
DY PATIL DENTAL SCHOOL
DY Patil Knowledge City, Charholi
Lohegaon Pune - 412105.

Sr. No.	Name.	Date of postings.
31.	Kothari Shreya.	30/7/20 - 13/8/20.
32.	Khandare Shraddha.	15/7/20 - 29/7/20.
33.	Mayuri Jagtap.	15/7/20 - 29/7/20.
34.	Khot Vishal.	15/7/20 - 29/7/20.
35.	Mahajan Nimisha.	30/8/20 - 15/9/20.
36.	Lalahi Alisha.	30/8/20 - 15/9/20.
37.	Kumari Rashmi Sunil	14/8/20 - 29/8/20.
38.	Marathe Ankita.	16/9/19 - 30/9/19.
39.	Malve Renuka.	16/9/20 - 30/9/20.
40.	Muley Shubham.	16/10/19 - 1/11/19.
41.	Mhaskar Shruti	16/10/19 - 1/11/19.
42.	Mehta Saumya	1/10/19 - 15/10/19.
43.	Nandkule Rutuja.	31/1/20 - 14/2/20.
44.	Muradi Shivani	16/1/20 - 30/1/20.
45.	Pandey Kritarth.	15/2/20 - 30/2/20.
46.	Nenwani Chanchal	15/2/20 - 30/2/20.
47.	Padri Rohan kumar.	15/2/20 - 30/2/20.
48.	Parakh Himani	16/4/20 - 30/4/20.
49.	Pawar Saroj	16/5/20 - 30/5/20.
50.	Patil Sagar	16/5/20 - 30/5/20.
51	Patra Lipsa	16/5/20 - 30/5/20.
52	Patel Mamta.	1/5/20 - 15/5/20.
53	Pradhan Aneesh	30/6/20 - 14/7/20.
54.	Raut Namrata	30/7/20 - 13/8/20.
55.	Radhika Pol	30/7/20 - 13/8/20.
56.	Preethi Pillai	15/7/20 - 29/7/20.
57.	Shah Manthan.	31/3/20 - 15/4/20.
58.	Sayed Fehmeen	31/3/20 - 15/4/20.
59	Saiawala Khadija	16/3/20 - 30/3/20.
60.	Raut Siddhi	1/3/20 - 15/3/20.

Head of Department of Prosthodontics
DY PATIL DENTAL SCHOOL
DY Patil Knowledge City, Charholi
Lohegaon, Pune - 412105

Sr. No.	Name.	Date of posting.
61.	Aman Shaikh.	31/5/20 - 14/6/20.
62.	Tanay Shah.	16/5/20 - 30/5/20.
63.	Poonam Shinde.	15/6/20 - 29/6/20.
64.	Shraddha Shere.	15/6/20 - 29/6/20.
65.	Faheem Shaikh.	15/6/20 - 29/6/20.
66.	Pooja Singh.	17/12/19 - 31/12/19.
67.	Thamina Chandran	16/1/20 - 30/1/20.
68.	Gayatri Thakare.	16/1/20 - 30/1/20.
69.	Taiwade Aditya.	16/1/20 - 30/1/20.
70.	Swami Jahnavi	1/1/20 - 15/1/20.
71.	Manojkumar Yadav.	17/11/19 - 1/12/19.
72.	Phalguni warate.	2/11/19 - 16/11/19.
73.	Wadkar Shivani.	2/12/19 - 16/12/19.
74.	Snehal Deokar.	2/12/19 - 16/12/19.
75.	Mayuri Yadav.	2/12/19 - 16/12/19.

Head of Department of Prosthodontics
DY PATIL DENTAL SCHOOL
DY Patil Knowledge City, Charholi
Lohegaon, Pune - 412105

Sr. No.	Name	Date of Postings.
1.	Achual Madhura	28/12/20 - 11/1/21.
2.	Bavgal Snehal	27/1/21 - 10/2/21.
3.	Asolkar Namrata.	27/1/21 - 10/2/21.
4.	Aishwarya Krishnan.	27/1/21 - 10/2/21.
5.	Agarwal Soumya.	12/1/21 - 26/1/21.
6.	Bhavsar Ayushi	26/2/21 - 12/3/21.
7.	Barve Pooja.	11/2/21 - 25/2/21.
8.	Bhoyar Shivani.	29/3/21 - 12/4/21.
9.	Bhosale Anjali	13/3/21 - 28/3/21.
10.	Bhde Nikita.	13/3/21 - 28/3/21.
11.	Bhoga Sruti	13/3/21 - 28/3/21.
12.	Das Jyotirmayee.	28/4/21 - 12/5/21.
13.	Dani Rutuja.	28/4/21 - 12/5/21.
14.	Dagade Omkar.	28/4/21 - 12/5/21.
15.	Chavan Shweta.	13/4/21 - 27/4/21.
16.	Deora Chitrangada.	28/5/21 - 11/6/21.
17.	Deochake chinmayee.	13/5/21 - 27/5/21.
18.	Gaikwad Kalyani	27/6/21 - 11/7/21.
19.	Doiphode Siddharth.	12/6/21 - 26/6/21.
20.	Dighe Anisha.	12/6/21 - 26/6/21.
21.	Deshmukh Shivani	12/6/21 - 26/6/21.
22.	Huse Shraddha.	12/7/21 - 26/7/21.
23.	Hiwale Shiva.	12/7/21 - 26/7/21.
24.	Hiswankar Shruti	12/7/21 - 26/7/21.
25.	Gawali Harshada.	12/7/21 - 26/7/21.
26.	Gaikwad Kalyani	27/6/21 - 11/7/21.
27.	Jadhav Megha.	26/8/21 - 11/9/21.
28.	Kadam Mayur	12/9/21 - 26/9/21.
29.	Joshi Vedika.	12/9/21 - 26/9/21.
30.	Jantandhu Simran.	12/9/21 - 26/9/21.

Head of Department of Prosthodontics
DY PATIL DENTAL SCHOOL
DY Patil Knowledge City, Charholi
Lohegaon, Pune - 412105

Sr. No.	Name.	Date of Postings.
31.	Pallavi Karale.	27/9/21 - 11/10/21.
32.	Mhatre Snehal	28/10/21 - 12/11/21.
33.	Mali Sejal.	28/10/21 - 12/11/21.
34.	Kulkarni Pragati	28/10/21 - 12/11/21.
35.	Manali Khale.	12/10/21 - 27/10/21.
36.	Nagaraje Kiran.	28/11/21 - 12/12/21.
37.	Momin Simrah.	13/11/21 - 27/11/21.
38.	Pandey Anamika.	28/12/20 - 11/1/21.
39.	Nikita Gautam.	13/12/21 - 27/12/21.
40.	Nandy Koyena.	13/12/21 - 27/12/21.
41.	Nalawade Shalelka.	13/12/21 - 27/12/21.
42.	Patil Neha.	27/1/21 - 10/2/21.
43.	Patel Ankit	27/1/21 - 10/2/21.
44.	Paraskar Vaidehi	27/1/21 - 10/2/21.
45	Parankar Shweta.	12/1/21 - 26/1/21.
46.	Patil Shraddha.	28/4/21 - 12/5/21.
47.	Sarag samruddhi.	28/5/21 - 11/6/21.
48.	Rokade Abhijeet.	28/5/21 - 11/6/21.
49.	Qureshi Shoaib.	28/5/21 - 11/6/21.
50.	Perke Rachana.	13/5/21 - 27/5/21.
51.	Sardar Neha.	27/7/21 - 10/8/21.
52.	Shaikh Yumna.	26/8/21 - 11/9/21.
53.	Shaikh Sufiyan.	26/8/21 - 11/9/21.
54.	Shaikh Batul.	26/8/21 - 11/9/21.
55	Saxena Gazal.	11/8/21 - 25/8/21.
56.	Sohoni Vishaksha.	28/10/21 - 12/11/21.
57.	Shinde Aishwarya.	12/10/21 - 27/10/21.
58	Thakur Titiksha.	13/11/21 - 27/11/21.
59.	Sunyawanshi Mansi	13/11/21 - 27/11/21.
60.	Sonure Mayuri	13/11/21 - 27/11/21.

Sr No.	Name	Date of Postings.
61.	Wanmal Prachi	27/6/21 - 11/7/21.
62.	Thopate Nikita.	12/6/21 - 26/6/21.
63.	Sachin Mallick.	12/7/21 - 26/7/21.
64.	Purohit Rahul.	12/7/21 - 26/7/21.

Dr [illegible]
Department of Prosthodontics
DY PATIL DENTAL SCHOOL
DY Patil Knowledge City, Charholi
Bohegaon, Pune - 412105

Sr. No.	Name.	Date of Postings.
1.	Swaraj Ashte.	19-1-22 - 2-2-22.
2.	Iftisam Ajrekar.	4/1/22 - 18/1/22.
3.	Ajmera krishna.	20/12/21 - 3/1/21.
4.	Prashant Bhasge	19/1/22 - 2/2/22.
5.	Lakshmi Bandebaache.	19/1/22 - 2/2/22.
6.	Chheda Reet	18/2/22 - 4/3/22.
7.	Bhimani Priyansh.	3/2/22 - 17/2/22.
8.	Despande Akshada.	20/3/22 - 3/4/22.
9.	Deshmukh Shwari	5/3/22 - 19/3/22.
10.	Deole Nishika.	5/3/22 - 19/3/22.
11	Deglurkar Nidhi	5/3/22 - 19/3/22.
12.	Edlawar Apoorva.	19/4/22 - 3/5/22.
13.	Dole Ruta.	19/4/22 - 3/5/22.
14.	Dhaybar Shreya.	19/4/22 - 3/5/22.
15.	Sheral Dhaigude.	4/4/22 - 18/4/22.
16.	Anush Gupta.	19/5/22 - 25/6/22.
17.	Sneha Funde.	4/5/22 - 18/5/22
18	Pallavi Kachave.	3/6/22 - 17/7/22.
19.	Komal Jagtap	18/6/22 - 2/7/22.
20.	Anuja Jagtap.	18/6/22 - 2/7/22.
21.	Varsha Gutte.	3/6/22 - 17/6 -22.
22.	Gaurav Dipti.	3/6/22 - 17/6/22.
23.	Shivani Kadam.	18/7/22 - 1/8/22.
24.	Pooja Kadam.	18/7/22 - 1/8/22.
25.	Gauthami Kadam.	18/7/22 - 1/8/22.
26.	Priyanka Kedar.	17/8/22 - 1/9/22.
27.	Rachana Kachase.	2/8/22 - 16/8/22.
28.	Rita Khadke.	2/9/22 - 16/9/22.
29.	Rahul Kshirsagar	2/9/22 - 16/9/22.
30.	Shital Khade.	2/9/22 - 16/9/22.

Head of Department of Prosthodontics
DY PATIL DENTAL SCHOOL
DY Patil Knowledge City, Charholi
Lohegaon, Pune - 412105

Sr. No.	Name.	Date of Postings.
31.	Shivani Kolhe.	17/9/22 - 1/10/22.
32.	Neha Londhe.	18/10/22 - 4/11/22.
33.	Lohita. Vishakha.	18/10/22 - 4/11/22.
34.	Kumbhar Tanvi	18/10/22 - 4/11
35.	Shruti Kulkami	2/10/22 - 17/10/22.
36.	Mahirchandani Divya.	20/11/22 - 4/12/22.
37.	Piyush Mahajan.	5/11/22 - 19/11/22.
38.	Anurag Maurya.	5/12/22 - 19/12/22.
39.	Unnati Mathurvaishya.	5/12/22 - 19/12/22.
40.	Rutuja Mathapati	5/12/22 - 19/12/22.
41.	Maurya Monika.	20/12/21 - 3/1/22.
42.	Ankita Mudsinge.	19/1/22 - 2/2/22.
43.	Mishra Adarsh.	19/1/22 - 2/2/22.
44.	Menghani Nikhil.	19/1/22 - 2/2/22.
45.	Mehra Kshitija.	4/1/22 - 18/1/22
46.	Maduna Nadange.	19/4/22 - 3/5/22.
47.	Komal Padsalgi	19/5/22 - 2/6/22.
48.	Ostwal Bhavana.	19/5/22 - 2/6/22.
49.	Nikam Pratiksha.	19/5/22 - 2/6/22.
50	Naik Divya.	4/5/22 - 18/5/22.
51.	Shriyash Panchal	18/7/22 - 1/8/22.
52.	Patil Krutika.	17/8/22 - 1/9/22.
53.	Komal Patil	17/8/22 - 1/9/22.
54.	Divya Patil	17/8/22 - 1/9/22.
55.	Panade Sachin	2/8/22 - 16/8/22.
56.	Patil Poornima.	18/10/22 - 4/11/22.
57.	Leena Patil	2/10/22 - 17/10/22.
58.	Patil Krutika.	17/8/22 - 1/9/22.
59.	Patil Rupal.	5/11/22 - 19/11/22.
60	Patil Pranav.	5/11/22 - 19/11/22.

for HOD

Head of Department of Prosthodontics
DY PATIL DENTAL SCHOOL
DY Patil Knowledge City, Charholi
Lohegaon, Pune - 412105

Sr. No.	Name	Date of Posting
61.	Tanya Roy.	3/6/22 - 17/7/22.
62.	Uzair Raut	3/6/22 - 17/7/22.
63.	Monika Raut	3/6/22 - 17/7/22.
64.	Roshni Rankawat	18/6/22 - 2/7/22.
65.	Anshika Rajagopal	3/6/22 - 17/6/22.
66.	Varsha sawant	18/2/22 - 4/3/22
67	Gashish Saraswat	3/2/22 - 17/2/22
68.	Prachi Sharma.	5/3/22 - 19/3/22
69.	Deep Shah.	5/3/22 - 19/3/22
70.	Muskaan Saxena	5/3/22 - 19/3/22.
71.	Shubham Shinde.	17/8/22 - 1/9/22
72.	Mukta Shelke.	2/8/22 - 16/8/22
73.	Niranjansingh Thakur	2/9/22 - 16/9/22
74.	Neha Tambe.	2/9/22 - 16/9/22
75.	Shruti Surakshya.	2/9/22 - 16/9/22
76.	Vaishnavi Tripathi	20/3/22 - 3/4/22
77.	Ashwin Zote.	19/4/22 - 3/5/22.
78.	Harshali Jhawar.	19/4/22 - 3/5/22.
79.	Shivani Waghmode.	19/4/22 - 3/5/22.
80.	Manjiri Vidhate.	4/4/22 - 18/4/22.
81.	Aditya Paul	20/3/22 - 3/5/22.
82.	Anjali Lingoji	19/4/22 - 3/5/22.
83.	Ali Tandel.	4/4/22 - 18/4/22.
84.	Naitish Tash.	18/10/22 - 4/11/22
85.	Mahesh Sose.	18/10/22 - 4/11/22.
86.	Zain Patel.	2/10/22 - 17/10/22.

Head of Department of Prosthodontics
DY PATIL DENTAL SCHOOL
DY Patil Knowledge City, Charholi
Lohegaon, Pune - 412105

Sr. No.	Name.	Date of Postings.
1.	Sakshi Aglawe.	25/10/22 - 9/11/22.
2.	Hrutuja Agarkar	10/10/22 - 24/10/22.
3.	Shivani Bhoir.	25/11/22 - 9/12/22.
4.	Rutuja Bardeskar.	10/11/22 - 24/11/22.
5.	Sneha Bansode.	10/11/22 - 24/11/22.
6.	Harshal Autade.	10/11/22 - 24/11/22
7.	Nandini Borade.	25/12/22 - 9/1/23.
8.	Amaan Bhura.	25/12/22 - 9/1/23.
9.	Harshada Bhujbal.	25/12/22 - 9/1/23.
10.	Shraddha Bholyar.	10/12/22 - 24/12/23.
11.	Anuraddha Chavan.	25/1/23 - 9/2/23.
12.	Ketan Chaudhari	10/1/23 - 24/1/23.
13.	Ishan Dodal.	25/2/23 - 9/3/23.
14.	Rutika Deshmukh.	10/2/23 - 24/2/23.
15.	Aditi Daberao.	10/2/23 - 24/2/23.
16.	Vaishnavi Chaudhary	10/2/23 - 24/2/23.
17.	Prasad Gaikwad.	25/3/23 - 9/4/23.
18.	Akshata Gaikwad	25/3/23 - 9/4/23.
19.	Manali Gaikar.	25/3/23 - 9/4/23.
20.	Pooja Dudhe.	10/3/23 - 24/3/23
21.	Kirti Garje.	25/4/23 - 9/5/23.
22.	Shivani Gaikwad	10/4/23 - 24/4/23.
23.	Sharvari Hankar.	25/5/23 - 9/6/23.
24.	Isha Gune.	10/5/23 - 24/5/23.
25.	Poonam Gire.	10/5/23 - 24/5/23.
26.	Gargi Gosalkar	10/5/23 - 24/5/23.
27.	Rohini Jadhav.	10/6/23 - 24/6/23.
28.	Pratik Jagtap	25/6/23 - 9/7/23.
29.	Ritika Jaiswal.	25/6/23 - 9/7/23.
30.	Tanmay Jadhav.	

Head of Department of Prosthodontics
DY PATIL DENTAL SCHOOL
DY Patil Knowledge City, Charholi
Lohegaon, Pune - 412105

Sr. No.	Name.	Date of Postings.
31.	Kritika Jha.	25/7/23 - 9/8/23.
32.	Gauri Jaju.	10/7/23 - 24/7/23.
33.	Ashwini Kanthe.	25/8/23 - 9/9/23.
34.	Aboli Kamthe.	10/8/23 - 24/8/23.
35.	Rutuja Kairamkonda.	10/8/23 - 24/8/23.
36.	Isha Joshi.	10/8/23 - 24/8/23.
37.	Shantanu Khude.	25/9/23 - 9/10/23.
38.	Tejas Kharat.	25/9/23 - 9/10/23.
39.	Rushikesh Khandekar.	25/9/23 - 9/10/23.
40.	Rutuja Kendre	10/9/23 - 24/9/23.
41.	Shivani Kshirsagar.	25/10/22 - 9/11/22.
42.	Keshar Krishna	10/10/22 - 24/10/22.
43.	Vidisha Lingait.	10/11/22 - 24/11/22
44.	Mansi Latpate.	10/11/22 - 24/11/22
45.	Mrunal kulkarni	10/11/22 - 24/11/22.
46.	Maria Noor.	25/2/23 - 9/3/23.
47.	Anisha Manwani	10/2/23 - 24/2/23.
48.	Sampada Muttepwar	10/3/23 - 24/3/23.
49.	Vidhya Munjal	10/3/23 - 24/3/23.
50.	Sampada Muley	10/3/23 - 24/3/23.
51.	Pallavi Naikwade	25/5/23 - 9/6/23.
52.	Shruti Nagdekar.	10/5/23 - 24/5/23.
53.	Shraddha Nikam.	10/6/23 - 24/6/23.
54.	Samila Nigam	10/6/23 - 24/6/23.
55.	Ankita Nalawade.	10/6/23 - 24/6/23.
56.	Vaishnavi Pachange.	25/7/23 - 9/8/23.
57.	Ummay Pakawala.	25/8/23 - 9/9/23.
58.	Aayushi Pagnis.	25/8/23 - 9/9/23.
59.	Nishigandha Padile.	25/8/23 - 9/9/23.
60.	Sarika Padghan.	10/8/23 - 24/8/23.

Head of Department of Prosthodontics
DY PATIL DENTAL SCHOOL
DY Patil Knowledge City, Charholi
Lohegaon, Pune - 412105.

Sr. No.	Name.	Date of Postings.
61	Apoorva Panaskar.	25/3/23 - 9/4/23.
62.	Yashi Parmar.	10/4/23 - 24/4/23.
63.	Akash Payghan.	25/4/23 - 9/5/23.
64.	Tejaswini Patil.	25/4/23 - 9/5/23.
65.	Aishwarya Pasunoori.	25/4/23 - 9/5/23.
66.	Neha Pitak.	25/11/22 - 9/12/22.
67.	Vaishnavi Ravangave	25/12/22 - 9/1/23.
68.	Riya Ramgade.	25/12/22 - 9/12/23.
69.	Bakul Patode.	25/12/22 - 9/1/23.
70	Nikitha Poojari.	10/12/22 - 24/12/22.
71.	Shubhangi Jagat.	10/6/23 - 24/6/23.
72	Alisha Rokde.	25/5/23 - 9/6/23.
73.	Suraj Sonawane.	25/6/23 - 9/7/23.
74.	Pratiksha Sontakke.	25/6/23 - 9/7/23.
75.	Purva Shah.	25/6/23 - 9/7/23.
76.	Abhishek Tamore	25/1/23 - 9/2/23.
77	Swaranjali Surve.	10/1/23 - 24/1/23.
78.	Sumant Tiwari	10/2/23 - 24/2/23.
79.	Abhishek Tarde	10/2/23 - 24/2/23.
80.	Tanvi Tandale.	10/2/23 - 24/2/23.
81.	Ankita Vidhate.	25/7/23 - 9/8/23.
82.	Medha Vaidya.	10/7/23 - 24/7/23.
83.	Prince Singh.	10/8/23 - 24/8/23.
84.	Namrata Kholave.	10/8/23 - 24/8/23.
85.	Dimple Salunke.	10/8/23 - 24/8/23.
86.	Vaibhav Chote	10/8/23 - 24/8/23.
87.	Amol Wakure.	10/8/23 - 24/8/23.

for HOD

Head of Department of Prosthodontics
DY PATIL DENTAL SCHOOL
DY Patil Knowledge City, Charholi
Lohegaon, Pune - 412105

List of Students Trained

Geriatric Clinic

D.Y. PATIL DENTAL SCHOOL

DEPARTMENT OF

PROSTHODONTICS

GERIATRIC POSTING

REGISTER

Sr No.	Name	Date of Postings
1.	Shrutika	1/9/18 — 15/9/18
2.	Neha	16/9/18 — 30/9/18
3.	Jayashree	1/10/18 — 15/10/18
4.	Kajal	16/10/18 — 31/10/18
5.	Priyanka.	16/11/18 — 30/11/18
6.	Varuna.	1/12/18 — 15/12/18
7.	Mandi	16/12/18 — 30/12/18
8.	Vijayalakshmi	1/1/19 — 15/1/19
9.	Vishwa	16/1/19 — 30/1/19
10.	Priya	1/2/19 — 15/2/19
11.	Neelam	16/2/19 — 28/2/19
12.	Ruchika	1/3/19 — 15/3/19
13.	Purva	16/3/19 — 31/3/19
14.	Preeti	1/4/19 — 15/4/19
15.	Devyani	16/4/19 — 30/4/19
16.	Devyani	1/5/19 — 15/5/19
17.	Jaswender	16/5/19 — 31/5/19
18.	Jaswender	1/6/19 — 15/6/19.
19.	Muskan.	16/7/19 — 31/7/19
20.	Kajal	1/8/19 — 15/8/19
21.	Kajal	16/8/19 — 31/8/19.

Head of Department of Prosthodontics
DY PATIL DENTAL SCHOOL

Sr No.	Name	Date of Posting
1.	Abnave Tanishka	16/9/19 – 30/9/19
2.	Baldota Shreya	1/10/19 – 15/10/19
3.	Bhujbal Sanjana.	16/10/19 – 1/11/19
4.	Bivalkar Ruchi	16/10/19 – 1/11/19.
5.	Kamble Gauri	2/11/19 – 16/11/19
6.	Chaudhari Vaishnavi	17/11/19 – 1/12/19
7.	Chaudhary Mehul	2/12/19 – 16/12/19
8.	Chavan Akshay	2/12/19 – 15/12/19.
9.	Chincholkar Anuja.	2/12/19 – 16/12/19.
10.	Chordia Mayuri.	17/12/19 – 31/12/19
11.	Dabade Dhanashree.	1/1/20 – 15/1/20
12.	Dabral Utkarsha.	16/1/20 – 30/1/20
13.	Dalal Nisha.	16/1/20 – 30/1/20
14.	Dharmadhikari Shivani	16/1/20 – 30/1/20
15.	Phole Shrutika.	31/1/20 – 14/2/20
16.	Durge Sejal.	15/2/20 – 29/2/20
17.	Gaikwad Anuja.	1/3/20 – 15/3/20
18.	Gamare Swapnesha.	1/3/20 – 15/3/20
19.	Gandhi Aman.	16/3/20 – 30/3/20
20.	Garje Apurva.	31/3/20 – 15/4/20
21.	Garud Jui	16/4/20 – 30/4/20
22.	Gatkal Deepti	16/4/20 – 30/4/20
23.	Gawde Pratiksha.	16/4/20 – 30/4/20
24.	Ghogare Priyanka.	1/5/20 – 15/5/20
25.	Ghune Divya.	16/5/20 – 30/5/20
26.	Gogawle Rasika.	31/5/20 – 14/6/20
27.	Gundop Gayatri	31/5/20 – 14/6/20
28.	Harye Khushti.	31/5/20 – 16/6/20
29.	Ingole Swati	15/6/20 – 29/6/20
30.	Jadhav Shivani	30/6/20 – 14/7/20

Head of Department of Prosthodontics
DY PATIL DENTAL SCHOOL
DY Patil Knowledge City, Charholi
Lohegaon, Pune - 412105

Sr No.	Name	Date of Posting
31.	Mayuri Jagtap	15/7/20 - 29/7/20
32.	Khandare Shraddha.	15/7/20 - 29/7/20
33.	Khot Vishal.	15/7/20 - 29/7/20
34.	Kothari Shreya.	30/7/20 - 13/8/20
35	Kumari Rashmi Sunil.	14/8/20 - 29/8/20
36	Lalani Alisha.	30/8/20 - 15/9/20
37.	Mahajan Nimisha.	30/8/20 - 15/9/20
38.	Malve Renuka.	16/9/20 - 30/9/20
39.	Marathe Ankita	16/9/19 - 30/9/19
40.	Mehta Saumya.	1/10/19 - 15/10/19
41.	Mhaskar Shruti.	16/10/19 - 1/11/19.
42.	Muley Shubham.	16/10/19 - 1/11/19
43.	Muradi Shivani	16/1/20 - 30/1/20
44.	Nandkule Ruthya.	31/1/20 - 14/2/20
45.	Nenwani Chanchal.	15/2/20 - 30/2/20
46.	Padri Rohan Kumar	15/2/20 - 30/2/20
47.	Pandey Kritarth.	15/2/20 - 30/2/20
48.	Parakh Himani	16/4/20 - 30/4/20
49.	Patel Mamta.	1/5/20 - 15/5/20
50.	Patil Sagar	16/5/20 - 30/5/20
51.	Patra Lipsa.	16/5/20 - 30/5/20
52.	Pawar Saroj	16/5/20 - 30/5/20
53.	Pradhan Aneesh	30/6/20 - 14/7/20
54.	Preethi Pillai	15/7/20 - 29/7/20
55.	Radhika Pol	30/7/20 - 13/8/20
56.	Raut Namrata.	30/7/20 - 13/8/20
57.	Raut Siddhi.	1/3/20 - 15/3/20
58.	Sailawala Khadija.	16/3/20 - 30/3/20
59.	Sayed Fehmeen.	31/3/20 - 15/4/20
60.	Shah Manthan.	31/3/20 - 15/4/20

Head of Department of Prosthodontics
DY PATIL DENTAL SCHOOL
DY Patil Knowledge City, Charholi
Lohegaon, Pune - 412105

Sr. No.	Name	Date of Posting
61.	Tanay Shah	16/5/20 - 30/5/20
62.	Anam Shaikh.	31/5/20 - 14/6/20
63.	Faheem Shaikh.	15/6/20 - 29/6/20
64.	Shraddha Shere	15/6/20 - 29/6/20
65.	Poonam Shinde	15/6/20 - 29/6/20
66.	Pooja Singh.	17/12/19 - 31/12/19
67.	Swami Janhavi	1/1/20 - 15/1/20
68.	Taiwade Aditya.	16/1/20 - 30/1/20
69.	Gayatri Thakare	16/1/20 - 30/1/20
70.	Thanima Chandran.	16/1/20 - 30/1/20
71.	Phalguni warate	2/11/19 - 16/11/19.
72.	Manojkumar Yadav	17/11/19 - 1/12/19
73.	Mayuri Yadav	2/12/19 - 16/12/19
74.	Snehal Deokar.	2/12/19 - 16/12/19
75.	Wadkar Shivani	2/12/19 - 16/12/19.

Head of Department of Prosthodontics
DY PATIL DENTAL SCHOOL
DY Patil Knowledge City, Charholi
Lohegaon, Pune - 412105

Sr No.	Name	Date of Posting
1.	Achwal Madhura	28/12/20 – 11/1/21
2.	Agrawal Sourya	12/1/21 – 26/1/21
3.	Aishwarya Krishnan	27/1/21 – 10/2/21
4.	Asolkar Namrata.	27/1/21 – 10/2/21
5.	Bargal Snehal	27/1/21 – 10/2/21
6.	Barve Pooja.	11/2/21 – 25/2/21
7.	Bhavsar Ayushi	26/2/21 – 12/3/21
8.	Bhoga Shruti	13/3/21 – 28/3/21
9.	Bhole Nikita.	13/3/21 – 28/3/21
10.	Bhosale Anjali	13/3/21 – 28/3/21
11.	Bhoyar Shivani	29/3/21 – 12/4/21
12.	Chauhan Shweta	13/4/21 – 27/4/21
13.	Dagade Omkar	28/4/21 – 12/5/21
14.	Dani Rutuja	28/4/21 – 12/5/21
15.	Das Jyotirmayee	28/4/21 – 12/5/21
16.	Deochake chinmayee	13/5/21 – 27/5/21
17.	Deora Chitrangada	28/5/21 – 11/6/21
18.	Deshmukh Shivani	12/6/21 – 26/6/21
19.	Dighe Anisha	12/6/21 – 26/6/21
20.	Doiphode Siddharth.	12/6/21 – 26/6/21
21.	Gaikwad Kalyani	27/6/21 – 11/7/21
22.	Gawali Harshada.	12/7/21 – 26/7/21
23	Hiswankar Shruti	12/7/21 – 26/7/21
24.	Hiwale Shiva.	12/7/21 – 26/7/21
25.	Huse Shraddha.	12/7/21 – 26/7/21
26.	Jadhav Aditya	11/8/21 – 25/8/21
27.	Jadhav Megha.	26/8/21 – 11/9/21
28.	Janbandhu Simran	12/9/21 – 26/9/21
29.	Joshi Vedika	12/9/21 – 26/9/21
30.	Kadam Mayuri	12/9/21 – 26/9/21

Head of Department of Prosthodontics
DY PATIL DENTAL SCHOOL
DY Patil Knowledge City, Charholi
Lohegaon Pune

Sr No	Name	Date of Posting
31.	Pallavi Karale	27/9/21 – 11/10/21
32.	Manali Khale	12/10/21 – 27/10/21
33.	Kulkarni Prajakta	28/10/21 – 12/11/21
34.	Mali Sejal	28/10/21 – 12/11/21
35.	Mhatre Snehal	28/10/21 – 12/11/21
36.	Momin Simrah	13/11/21 – 27/11/21
37.	Nagargoje Kiran	28/11/21 – 12/12/21
38.	Nalawade Shaleka.	13/12/21 – 27/12/21
39.	Nandy Koyena	13/12/21 – 27/12/21
40.	Nikita Gautam	13/12/21 – 27/12/21
41.	Pandey Anamika	28/12/20 – 11/1/21
42.	Parankar Shweta.	12/1/21 – 26/1/21
43.	Paraskar Vaidehi	27/1/21 – 10/2/21
44.	Patel Ankit	27/1/21 – 10/2/21
45.	Patil Neha.	27/1/21 – 10/2/21
46.	Patil Shraddha.	28/4/21 – 12/5/21
47.	Perke Rachana.	13/5/21 – 27/5/21
48.	Qureshi Shoaib	28/5/21 – 11/6/21
49.	Rokade Abhijeet	28/5/21 – 11/6/21
50.	Sarag Samruddhi	28/5/21 – 11/6/21
51.	Sardar Neha.	27/7/21 – 10/8/21
52.	Saxena Gazal	11/8/21 – 25/8/21
53.	Shaikh Batul.	26/8/21 – 11/9/21
54.	Shaikh Sufiyan	26/8/21 – 11/9/21
55.	Shaikh Yumna.	26/8/21 – 11/9/21
56.	Shinde Aishwarya.	12/10/21 – 27/10/21
57.	Sohoni Vishakha.	28/10/21 – 12/11/21
58.	Sonune Mayuri	13/11/21 – 27/11/21
59.	Suryawanshi Mansi	13/11/21 – 27/11/21
60.	Thakur Tikisha.	13/11/21 – 27/11/21

Head of Department of Prosthodontics
DY PATIL DENTAL SCHOOL
DY Patil Knowledge City, Charholi,
Lohegaon, Pune

Sr. No.	Name	Date of Posting
61	Thopate Nikita	12/6/21 – 26/6/21
62.	Warmali Prachi	27/6/21 – 11/7/21
63.	Purohit Rahul.	12/7/21 – 26/7/21
64.	Satin Mollick	12/7/21 – 26/7/21

Head of Department of Prosthodontics
DY PATIL DENTAL SCHOOL
DY Patil Knowledge City, Charholi
Lohegaon, Pune - 412105

Sr. No.	Name	Date of Posting
1.	Ajmera Krishna.	20/12-21 — 3-1-22
2.	Ithisam Ajrekar	4-1-22 — 18-1-22
3.	Swaraj Ashte	19-1-21 — 2-2-22
4.	Lakshmi Bandebuche	19/1-22 — 2-2-22
5.	Prashant Bhasge	19-1-22 — 2-2-22
6.	Bhirzani Priyansh.	3-2-22 — 17-2-22
7.	Chheda Reet	18-2-22 — 4-3-22
8.	Deglurkar Nidhi	5-3-22 — 19-3-22
9.	Deole Nishika.	5-3-22 — 19-3-22
10.	Deshmukh Ishwari	5-3-22 — 19-3-22
11.	Deshpande Akshada.	20-3-22 — 3-4-22
12.	Dhenal Dhaigude	4-4-22 — 18-4-22
13.	Dhaybar Shreya.	19-4-22 — 3-5-22
14.	Dole Ruta	19-4-22 — 3-5-22
15.	Edlawar Apoorva	19-4-22 — 3-5-22
16.	Sneha Funde	4-5-22 — 18-5-22
17.	Anush Gupta.	19-5-22 — 25-6-22
18.	Gurav Dipti	3-6-22 — 17-6-22
19.	Varsha Gutte	3-6-22 — 17-6-22
20.	Anuja Hange	3-6-22 — 17-6-22
21	Komal Jagtap	18-6-22 — 2-7-22
22.	Pallavi Kachave	3-6-22 — 17-7-22
23	Gautami Kadam.	18-7-22 — 1-8-22
24.	Pooja Kadam	18-7-22 — 1-8-22
25.	Shivani Kadam.	18-7-22 — 1-8-22
26.	Rachana Kachase	2-8-22 — 16-8-22
27.	Priyanka Kedar	17-8-22 — 1-9-22
28.	Shital Khade	2-9-22 — 16-9-22
29.	Rahul Kshirsagar	2-9-22 — 16-9-22
30	Rita Khodke	2-9-22 — 16-9-22

Head of Department of Prosthodontics
DY PATIL DENTAL SCHOOL
DY Patil Knowledge City, Charholi
Lohegaon, Pune - 412105

No.	Name	Date of Posting
31.	Shevani Kolhe	17-9-22 — 1-10-22
32.	Shruti kulkarni	2-10-22 — 17-10-22
33.	Kumbhar Tanvi	18-10-22 — 4-11-22
34.	Lohtia Vishakha	18-10-22 — 4-11-22
35.	Neha Londhe	18-10-22 — 4-11-22
36.	Piyush Mahajan	5-11-22 — 19-11-22
37.	Mahirchandani Divya	20-11-22 — 4-12-22
38.	Rutuja Mathapati	5-12-22 — 19-12-22
39.	Unnati Mathurvaishya	5-12-22 — 19-1222
40.	Anurag maurya	5-12-22 — 19-12-22
41.	maurya monika	20-12-21 — 3-1-22
42.	mehre kshitija	4-1-22 — 18-1-22
43.	Menghani Nikhil	19-1-22 — 2-2-22
44.	Mishra Adarsh	19-1-22 — 2-2-22
45.	Ankita Mudsinge	19-1-22 — 2-2-22
46.	Madura Nadarge	19/4/22 — 3/5/22
47.	Naik Divya	4/5/22 — 18/5/22
48.	Nikam Pratiksha	19/5/22 — 2/6/22
49.	Ostwal Bhavana	19/5/22 — 2/6/22
50.	komal Padsalgi	19/5/22 — 2/6/22
51.	Shriyash Panchal	18/7/22 — 1/8/22
52.	Panade Sakshi	2/8/22 — 16/8/22
53.	Divya Patil	17/8/22 — 1/9/22
54.	komal Patil	17/8/22 — 1/9/22
55.	Patil [illegible]ika	17/8/22 — 1/9/22
56.	Leena Patil	2/10/22 — 17/10/22
57.	Patil Poornima	18/10/22 — 4/11/22
58.	Patil Pranav	5/11/22 — 19/11/22
59.	Patil Rupal	5/11/22 — 19/11/22
60.	Patil sanika	5/11/22 — 19/11/22

Head of Department of Prosthodontics
DY PATIL DENTAL SCHOOL
DY Patil Knowledge City Charholi
Lohegaon, Pune 412105

Sr. No	Name	
61.	Anshika Rajagopal	3/6/22 - 17/6/22
62.	Roshni Rankawat	18/6/22 - 2/7/22
63.	Monika Raut	3/6/22 - 17/7/22
64.	Uzair Raut	3/6/22 - 17/7/22
65.	Tanya Roy	3/6/22 - 17/7/22
66.	Rashish Sarawat	3/2/22 - 17/2/22
67.	Varsha Sawant	18/2/22 - 4/3/22
68.	Muskaan Saxena.	5/3/22 - 19/3/22
69.	Deep Shah.	5/3/22 - 19/3/22
70.	Prachi Sharma.	5/3/22 - 19/3/22
71.	Mukta Shelke	2/8/22 - 16/8/22
72.	Shubham Shinde	17/8/22 - 1/9/22
73.	Shruti Surakshya.	2/9/22 - 16/9/22
74.	Neha Tambe.	2/9/22 - 16/9/22
75.	Niranjan Singh Thakur.	2/9/22 - 16/9/22
76.	Vaishnavi Tripathi	20/3/22 - 3/4/22
77.	Manjiri Vidhate	4/4/22 - 18/4/22
78.	Shivani Waghmode.	19/4/22 - 3/5/22
79.	Harshali Thawar	19/4/22 - 3/5/22
80.	Ashwin zote	19/4/22 - 3/5/22
81.	Aditya Paul	20/3/22 - 3/5/22
82.	Ali Tandel.	4/4/22 - 18/4/22
83.	Anjali Lingaji	19/4/22 - 3/5/22
84.	Ruhija Waghmode.	17/9/22 - 1/10/22
85.	Zain Patel	2/10/22 - 17/10/22
86.	Mahesh sose	18/10/22 - 4/11/22
87.	Nailesh Tosh.	18/10/22 - 4/11/22

Head of Department of Prosthodontics
DY PATIL DENTAL SCHOOL
DY Patil Knowl... Charholi
Lohe...

2022-23

Sr.No	Name	Date of Posting
1.	Hrutuja Agarkar	10/10/22 — 24/10/22
2.	Sakshi Aglave	25/10/22 — 9/11/22
3.	Harshal Autade	10/11/22 — 24/11/22
4.	Sneha Barsode	10/11/22 — 24/11/22
5.	Rutuja Bardeskar	10/11/22 — 24/11/22
6.	Shivani Bhoir	25/11/22 — 9/12/22
7.	Shraddha Bhagat	10/12/22 — 24/12/22
8.	Harshada Bhujbal	25/12/22 — 9/1/23
9.	Amaan Bhura.	25/12/22 — 9/1/23
10.	Nandini Borade	25/12/22 — 9/1/23
11.	Ketan Chaudhari	10/1/23 — 24/1/23
12.	Anuradha Chavan.	25/1/23 — 9/2/23
13.	Vaishnavi Chaudhary	10/2/23 — 24/2/23
14.	Aditi Daberao	10/2/23 — 24/2/23
15.	Rutika Deshmukh.	10/2/23 — 24/2/23
16.	Ishan Dodal.	25/2/23 — 9/3/23
17.	Pooja Duthe	10/3/23 — 24/3/23
18.	Manali Gaikar	25/3/23 — 9/4/23
19.	Akshata Gaikwad.	25/3/23 — 9/4/23
20.	Prasad Gaikwad.	25/3/23 — 9/4/23
21.	Shivani Gaikwad.	10/4/23 — 24/4/23
22.	Kirti Garje	25/4/23 — 9/5/23
23.	Gargi Ghosalkar	10/5/23 — 24/5/23
24.	Poonam Gire	10/5/23 — 24/5/23
25.	Isha Gune	10/5/23 — 24/5/23
26.	Sharvari Ifankar	25/5/23 — 9/6/23
27.	Rohini Jadhav	10/6/23 — 24/6/23
28.	Tanmay Jadhav	25/6/23 — 9/7/23
29.	Pratik Jagtap	25/6/23 — 9/7/23
30.	Ritika Jaiswal	25/6/23 — 9/7/23

Head of Department of Prosthodontics
DY PATIL DENTAL SCHOOL
DY Patil Knowledge City, Charholi
Lohegaon P

Dr No.	Name	
		10/7/23 — 24/7/23
31.	Gauri Taju	25/7/23 — 9/8/23
32.	Kritika Jha.	10/8/23 — 24/8/23
33.	Isha Joshi	10/8/23 — 24/8/23
34.	Rutuja Kairamkonda.	10/8/23 — 24/8/23
35.	Aboli Kamthe	25/8/23 — 9/9/23
36.	Ashwini Kamthe	10/9/23 — 24/9/23
37.	Rutuja Kendre	25/9/23 — 9/10/23
38.	Rushikesh Khandekar	25/9/23 — 9/10/23
39.	Tejas Kharat	25/9/23 — 9/10/23
40.	Shantanu Khude	10/10/22 — 24/10/22
41.	Keshar Krishna.	25/10/22 — 9/11/22
42.	Shivani Kshirsagar.	10/4/22 — 24/11/22
43.	Mrunal Kulkarni	10/11/22 — 24/11/22
44.	Mansi Latpate	10/11/22 — 24/11/22
45.	Vidisha Lingait	10/2/23 — 24/2/23
46.	Anisha Marwari	25/2/23 — 9/3/23
47.	Maria Noor	10/3/23 — 24/3/23
48.	Sampada Muley	10/3/23 — 24/3/23
49.	Vidhya Munjal	10/3/23 — 24/3/23
50.	Sampada Muttepwar	10/5/23 — 24/5/23
51.	Shruti Nagdekar	25/5/23 — 9/6/23
52.	Pallavi Waikwade	10/6/23 — 24/6/23
53.	Ankita Nalawade	10/6/23 — 24/6/23
54.	Samila Nigam	10/6/23 — 24/6/23
55.	Shraddha Nikam	25/7/23 — 9/8/23
56.	Vaishnavi Pachange	10/8/23 — 24/8/23
57.	Sanika Padghan.	25/8/23 — 9/9/25
58.	Nishigandha Padile	25/8/23 — 9/9/23
59.	Aayushi Pagnis.	25/8/23 — 9/9/23
60.	Ummay Pakawala.	

Head of Department of Prosthodontics
DY PATIL DENTAL SCHOOL
DY Patil Knowledge City, Charholi

Name	Date of Posting
Apoorva Parashkar	25/3/23 - 9/4/23
Yashi Parmar	10/4/23 - 24/4/23
Aishwarya Pasunoori	25/4/23 - 9/5/23
Tejaswini Patil	25/4/23 - 9/5/23
Akash Payghan.	25/4/23 - 9/5/23
Neha Pitale	25/11/22 - 9/12/22
Nikitha Poojari	10/12/22 - 24/12/22
Rahul Patode	25/12/22 - 9/1/23
Riya Ramgade	25/12/22 - 9/12/23
Vaishnavi Ravangave	25/12/22 - 9/1/23
Alisha Rokde	25/5/23 - 9/6/23
Shubhangi Sagar	10/6/23 - 24/6/23
Purva Shah.	25/6/23 - 9/7/23
Pratiksha Sontakke.	25/6/23 - 9/7/23
Suraj Sonvane.	25/6/23 - 9/7/23
Swaranjali Surve	10/1/23 - 24/1/23
Abhishek Tamore	25/1/23 - 9/2/23
Tanvi Tandale	10/2/23 - 24/2/23
Abhishek Tarde	10/2/23 - 24/2/23
Sumant Tiwari	10/2/23 - 24/2/23
Medha Vaidya.	10/7/23 - 24/7/23
Ankita Vidhate.	25/7/23 - 9/8/23
Amol Wakure	10/8/23 - 24/8/23
Vaibhav Chole	10/8/23 - 24/8/23
Dimple Salunkhe	10/8/23 - 24/8/23
Namrata Gholave	10/8/23 - 24/8/23
Prince Singh.	10/8/23 - 24/8/23

Head of Department of Prosthodontics
DY PATIL DENTAL SCHOOL
DY Patil Knowledge City, Charholi
Lohegaon, Pune - 412105

List of Students Trained

Special Health Care Need Clinic

DY PATIL DENTAL SCHOOL

DEPARTMENT OF PEDODONTICS

POSTING REGISTER

SPECIAL HEALTH CARE NEED CLINIC

Sr No	Name	Posting Dates
1.	Vishwas Lodaliya	01/08/2019 - 31/08/2019.
2.	Priya Markad	01/08/2019 - 31/08/2019.
3.	Asiya Attar	02/09/2019 - 01/10/2019.
4.	Abhishek kamble	17/09/2019 - 01/10/2019.
5.	Mrinalini B	02/09/2019 - 01/10/2019.
6.	Stanley B.	02/10/2019 - 03/11/2019.
7.	Shivani Wadkar	16/09/2019 - 15/10/2019.
8.	Phalguni Warate	16/09/2019 - 15/10/2019.
9.	kritharth Pandey	16/09/2019 - 15/10/2019
10.	Rohankumar Padri	16/09/2019 - 15/10/2019.
11.	Sejal Durge	16/10/2019 - 15/11/2019.
12.	Swapnesha Gamake	16/10/2019 - 15/11/2019.
13.	Jui Garud	02/11/2019 - 01/12/2019.
14.	Saroj Pawar	18/11/2019 - 16/12/2019.
15.	Radhika Pol.	02/12/2019 - 17/12/2019
16.	Anush Pradhan	02/12/2019 - 17/12/2019.

for PROFESSOR & HEAD
Dept. of Paediatric & Preventive Dentistry
D Y Patil Dental School
D Y Patil Knowledge City
Charholi (Bk), Via Lohegaon, Pune - 412105

17.	Rahat Thekedar	04/12/2019 - 02/01/2020
18.	Srushti Hange	17/12/2019 - 15/01/2020
19.	Tanay. Shah	15/01/2020 - 14/02/2020
20.	Faheem Shaikh	15/01/2020 - 14/02/2020.
21.	Vishal khot	31/01/2020 - 29/02/2020
22.	Shivani Jadhav	31/01/2020 - 29/02/2020
23.	Vijayalakshmi	27/09/2021 - 02/10/2021
24.	Vijayalakshmi	11/10/2021 - 16/10/2021
25.	Bhagyshree	18/10/2021 - 23/10/2021
26.	Vijayalakshmi	08/11/2021 - 13/11/2021
27.	Bhagyshree	22/11/2021 - 27/11/2021
28.	Bhagyashree	29/11/2021 - 03/12/2021
29.	Vijayalakshmi	06/12/2021 - 11/12/2021
30.	Bhagyashree	27/12/2021 - 02/01/2022
31.	Bhagyashree	17/01/2022 - 23/01/2022
32.	Mayuri	31/01/2022 - 6/02/2022
33.	Ahilya.	31/01/2022 - 06/02/2022
34.	Mayuri	14/02/2022 - 20/02/2022

PROFESSOR & HEAD
Dept. of Paediatric & Preventive Dentistry
D Y Patil Dental School
D.Y. Patil Knowledge City
Charoli (Bk), Via Lohegaon, Pune - 412105.

35.	Vijayalakshmi	21/02/2022 - 27/02/2022
36	Vijayalakshmi	28/02/2022 - 05/03/2022
37	Bhagyashree	21/03/2022 - 27/03/2022
38	Mayuri	11/04/2022 - 17/04/2022
39	Ahilya.	18/04/2022 - 23/04/2022
40	Ahilya.	25/04/2022 - 1/05/22
41	Mayuri	04/05/2022 - 10/05/2022
42	Ahilya.	18/05/2022 - 24/05/2022
43	Bhagyashree	30/05/2022 - 05/06/2022
44	Vijayalakshmi	20/06/2022 - 26/06/2022
45	Ahilya	04/07/2022 - 10/07/2022
46	Mayri	18/07/2022 - 24/07/2022
47	Bhagyashree	25/07/22 - 31/07/22
48	Mayuri	01/08/2022 - 07/08/2022

PROFESSOR & HEAD
Dept. of Paediatric & Preventive Dentistry
D Y Patil Dental School
D Y Patil Knowledge City
Charoli (Bk), Via Lohegaon, Pune - 412105.

List of Students Trained

Tobacco Cessation Centre Clinic

LIST OF STUDENT'S TRAINED

FOR TCC

LIST OF STUDENTS TRAINED FOR TCC
(INTERN BATCH – YEAR 2018- 2019)

SR. NO.	STUDENT NAME	NAME OF DEPARTMENT	BATCH	YEAR
1.	Bhanushali Mrunalini Ajit	OMR	INTERN	2018-2019
2.	Bhavsar Aayushi Govind	OMR	INTERN	2018-2019
3.	Ghogare Saurabh Subhash	OMR	INTERN	2018-2019
4.	Gupta Shikha Gulabchand	OMR	INTERN	2018-2019
5.	Kachave Kalyansingh Vishwanath	OMR	INTERN	2018-2019
6.	Masal Maruti Shravan	OMR	INTERN	2018-2019
7.	Mehta Shreya Jitendra	OMR	INTERN	2018-2019
8.	Mhaskar Shivani Dnaneswar	OMR	INTERN	2018-2019
9.	Padri Rohankumar Chintamani	OMR	INTERN	2018-2019
10.	Sadique Neelam Mohammad	OMR	INTERN	2018-2019
11.	Salunkhe Jayashree Shrirang	OMR	INTERN	2018-2019
12.	Saste Kajal Rajkumar	OMR	INTERN	2018-2019
13.	Sharma Shrutika Krishnakumar	OMR	INTERN	2018-2019
14.	Shelake Neha Arun	OMR	INTERN	2018-2019
15.	Shirsat Sonal Bhushan	OMR	INTERN	2018-2019
16.	Attar Asiya Mubarak	OMR	INTERN	2018-2019
17.	Barode Subhangi Subhash	OMR	INTERN	2018-2019
18.	Deokar Snehal Dilip	OMR	INTERN	2018-2019
19.	Deshmane Sweta Mahadev	OMR	INTERN	2018-2019
20.	Digwa Jasvinder Kaur Amrik Singh	OMR	INTERN	2018-2019
21.	Ghanekar Purva Kamlakar	OMR	INTERN	2018-2019
22.	Jagtap Mayuri Vikas	OMR	INTERN	2018-2019
23.	Kamble Abhishek Vijayprakash	OMR	INTERN	2018-2019

PROFESSOR & HEAD
Dept. Of [illegible]
D Y Patil Dental School
D Y Patil Knowledge City
Charoli (Bk), Via Lohegaon, Pune - 412105

24.	Kumbhar Ruchika Vijay	OMR	INTERN	2018-2019
25.	Lodaliya Viswa Mukesh	OMR	INTERN	2018-2019
26.	Markad Priya Bhagat	OMR	INTERN	2018-2019
27.	Mohite Vijaylaxmi Rajendra	OMR	INTERN	2018-2019
28.	Patil Priyanka Arun	OMR	INTERN	2018-2019
29.	Pokharkar Shreya Manohar	OMR	INTERN	2018-2019
30.	Prasad Neha Brijbhushan	OMR	INTERN	2018-2019
31.	Sachwani Sweety Bhishamkumar	OMR	INTERN	2018-2019
32.	Saini Simran Harmindar	OMR	INTERN	2018-2019
33.	Singh Muskan Arvindkumar	OMR	INTERN	2018-2019
34.	Singh Prince Ramparbal	OMR	INTERN	2018-2019
35.	Tekwani Sweta Laxmandas	OMR	INTERN	2018-2019
36.	Pillay Aruna Raja	OMR	INTERN	2018-2019
37.	Alhat Devyani Prakash	OMR	INTERN	2018-2019
38.	Kharmale Neelam Dattatray	OMR	INTERN	2018-2019
39.	Rathod Chetana Dhupchand	OMR	INTERN	2018-2019
40.	Thekedar Rahat Naimuddin	OMR	INTERN	2018-2019
41.	Tilekar Kajal Sangram	OMR	INTERN	2018-2019
42.	Wakade Virakshi Ramchandra	OMR	INTERN	2018-2019
43.	Kadam Priti Karbhari	OMR	INTERN	2018-2019
44.	Pawar Rutuja Vijaysingh	OMR	INTERN	2018-2019
45.	Josifus Berachah Stanley	OMR	INTERN	2018-2019
46.	Gurav Shrutika Vilas	OMR	INTERN	2018-2019
47.	Wadkar Shivani Sanjay	OMR	INTERN	2018-2019

PROFESSOR & HEAD
Dept. Of Oral Medicine & Radiology
D Y Patil Dental School
D Y Patil Knowledge City
Charoli (Bk), Via Lohegaon, Pune - 412105.

LIST OF STUDENTS TRAINED FOR TCC
(INTERN BATCH – YEAR 2019- 2020)

Roll No	Name	NAME OF DEPARTMENT	BATCH	YEAR
1.	Abnave Tanishka	OMR	INTERN	2019-2020
2.	Baldota Shreya	OMR	INTERN	2019-2020
3.	Bhujbal Sanjana	OMR	INTERN	2019-2020
4.	Bivalkar Ruchi	OMR	INTERN	2019-2020
5.	Kamble Gauri	OMR	INTERN	2019-2020
6.	Chaudhari Vaishnavi	OMR	INTERN	2019-2020
7.	Chavan Akshay	OMR	INTERN	2019-2020
8.	Chavan Shradha	OMR	INTERN	2019-2020
9.	Chincholkar Anuja	OMR	INTERN	2019-2020
10.	Chordia Mayuri	OMR	INTERN	2019-2020
11.	Chaudhory Mehul	OMR	INTERN	2019-2020
12.	Dabade Dhanshree	OMR	INTERN	2019-2020
13.	Dabral Utkarsha	OMR	INTERN	2019-2020
14.	Dalal Nisha	OMR	INTERN	2019-2020
15.	Demanna Sumanth	OMR	INTERN	2019-2020
16.	Deora Chitrangada	OMR	INTERN	2019-2020
17.	Deshmukh Samrudhi	OMR	INTERN	2019-2020
18.	Dharmadhikari Shivani	OMR	INTERN	2019-2020
19.	Dhole Shrutika	OMR	INTERN	2019-2020
20.	Durge Sejal	OMR	INTERN	2019-2020
21.	Gaikwad Ankita	OMR	INTERN	2019-2020
22.	Gaikwad Anuja	OMR	INTERN	2019-2020
23.	Gaikwad Shraddha	OMR	INTERN	2019-2020
24.	Gamare Swapnesha	OMR	INTERN	2019-2020
25.	Gandhi Aman	OMR	INTERN	2019-2020
26.	Garje Apurva	OMR	INTERN	2019-2020
27.	Garud Jui	OMR	INTERN	2019-2020
28.	Gatkal Deepti	OMR	INTERN	2019-2020
29.	Gawde Pratiksha	OMR	INTERN	2019-2020
30.	Ghogare Priyanka	OMR	INTERN	2019-2020
31.	Gholave Namarata	OMR	INTERN	2019-2020
32.	Ghune Divya	OMR	INTERN	2019-2020
33.	Gogawle Rasika	OMR	INTERN	2019-2020
34.	Gundap Gayatri	OMR	INTERN	2019-2020
35.	Gupta Shivani	OMR	INTERN	2019-2020
36.	Hange Srushti	OMR	INTERN	2019-2020
37.	Ingole Swati	OMR	INTERN	2019-2020
38.	Jadhav Shivani	OMR	INTERN	2019-2020
39.	Jadhav Snehal	OMR	INTERN	2019-2020
40.	Khandare Jay	OMR	INTERN	2019-2020
41.	Khandare Shraddha	OMR	INTERN	2019-2020
42.	Khot Vishal	OMR	INTERN	2019-2020
43.	Kothari Shreya	OMR	INTERN	2019-2020
44.	Kshirsagar Vyankat	OMR	INTERN	2019-2020
45.	Kumara Rashmi Sunil	OMR	INTERN	2019-2020
46.	Lakhe Sushmita	OMR	INTERN	2019-2020
47.	Lalani Alisha	OMR	INTERN	2019-2020

PROFESSOR & HEAD
Dept. Of Oral Medicine & Radiology
D Y Patil Dental School
D Y Patil Knowledge City
Charoli (Bk), Via Lonegaon, Pune - 41203

48.	Lall Tanya	OMR	INTERN	2019-2020
49.	Mahajan Nimisha	OMR	INTERN	2019-2020
50.	Malve Renuka	OMR	INTERN	2019-2020
51.	Mansata Monika	OMR	INTERN	2019-2020
52.	Marathe Ankita	OMR	INTERN	2019-2020
53.	Mehta Saumya	OMR	INTERN	2019-2020
54.	Mhaskar Shruti	OMR	INTERN	2019-2020
55.	Mollick Sahin	OMR	INTERN	2019-2020
56.	More Ratna	OMR	INTERN	2019-2020
57.	Muley Shubham	OMR	INTERN	2019-2020
58.	Muradi Shivani	OMR	INTERN	2019-2020
59.	Naitam Toshkumar	OMR	INTERN	2019-2020
60.	Nandkule Rutuja	OMR	INTERN	2019-2020
61.	Nenwani Chanchal	OMR	INTERN	2019-2020
62.	Pande Kritharth	OMR	INTERN	2019-2020
63.	Panja Suman	OMR	INTERN	2019-2020
64.	Parakh Himani	OMR	INTERN	2019-2020
65.	Patel Mamta	OMR	INTERN	2019-2020
66.	Patil Mansi	OMR	INTERN	2019-2020
67.	Patil Sagar	OMR	INTERN	2019-2020
68.	Patra Lipsa	OMR	INTERN	2019-2020
69.	Paul Aditya	OMR	INTERN	2019-2020
70.	Pawar Prajakta	OMR	INTERN	2019-2020
71.	Pawar Saroj	OMR	INTERN	2019-2020
72.	Pillai Preethi	OMR	INTERN	2019-2020
73.	Radhika Pol	OMR	INTERN	2019-2020
74.	Pradhan Aneesh	OMR	INTERN	2019-2020
75.	Purohit Rahul	OMR	INTERN	2019-2020
76.	Puthanangady Angela	OMR	INTERN	2019-2020
77.	Raut Namrata	OMR	INTERN	2019-2020
78.	Raut Siddhi	OMR	INTERN	2019-2020
79.	Ray Sweta	OMR	INTERN	2019-2020
80.	Sailawala Khadija	OMR	INTERN	2019-2020
81.	Sayed Fahmeen	OMR	INTERN	2019-2020
82.	Shah Manthan	OMR	INTERN	2019-2020
83.	Shah Tanay	OMR	INTERN	2019-2020
84.	Shaikh Anam	OMR	INTERN	2019-2020
85.	Sheikh Fahem Gulam	OMR	INTERN	2019-2020
86.	Shere Shraddha	OMR	INTERN	2019-2020
87.	ABSENT	OMR	INTERN	2019-2020
88.	Shinde Poonam	OMR	INTERN	2019-2020
89.	Singh Pooja	OMR	INTERN	2019-2020
90.	Pradnyesh V. Surwade	OMR	INTERN	2019-2020
91.	Swami Janhavi	OMR	INTERN	2019-2020
92.	Taiwade Aditya	OMR	INTERN	2019-2020
93.	Tandel Ali	OMR	INTERN	2019-2020
94.	Thakaray Gayatri	OMR	INTERN	2019-2020
95.	Thanima Chandran	OMR	INTERN	2019-2020
96.	Waghmode Rutuja	OMR	INTERN	2019-2020

PROFESSOR & HEAD
Dept. Of Oral Medicine & Radiology
D.Y Patil Dental School
D.Y Patil Knowledge City
Charoli (B.K. Via Lohegaon, Pune - 412105

97.	Warate Phalguni	OMR	INTERN	2019-2020
98.	Yadav Manojkumar	OMR	INTERN	2019-2020
99.	Yadav Mayuri	OMR	INTERN	2019-2020
100.	Zanje Sonali	OMR	INTERN	2019-2020

PROFESSOR & HEAD
Dept. Of Oral Medicine & Radiology
D Y Patil Dental School
D Y Patil Knowledge City
Charoli (Bk), Via Lohegaon, Pune - 412105.

LIST OF STUDENTS TRAINED FOR TCC
(INTERN BATCH – YEAR 2020- 2021)

Roll No.	Name of Student	NAME OF THE DEPARTMENT	BATCH	YEAR
1	ACHWAL MADHURA	OMR	INTERN	2020-2021
2	AGRAWAL SOUMYA	OMR	INTERN	2020-2021
3	AISHWARYA KRISHNAN	OMR	INTERN	2020-2021
4	ASOLKAR NAMRATA	OMR	INTERN	2020-2021
5	BARGAL SNEHAL	OMR	INTERN	2020-2021
6	BARVE POORVA	OMR	INTERN	2020-2021
7	BHOGA SHRUTI	OMR	INTERN	2020-2021
8	BHOLE NIKITA	OMR	INTERN	2020-2021
9	BHOSALE ANJALI	OMR	INTERN	2020-2021
10	BHOYAR SHIVANI	OMR	INTERN	2020-2021
11	CHAUHAN SHWETA	OMR	INTERN	2020-2021
12	DAGADE OMKAR	OMR	INTERN	2020-2021
13	DANI RUTUJA	OMR	INTERN	2020-2021
14	DAS JYOTIRMAYEE	OMR	INTERN	2020-2021
15	DEOCHAKE CHINMAYEE	OMR	INTERN	2020-2021
16	DESHMUKH SHIWANI	OMR	INTERN	2020-2021
17	DIGHE ANISHA	OMR	INTERN	2020-2021
18	DOIPHODE SIDDHARTH	OMR	INTERN	2020-2021
19	GAIKWAD KALYANI	OMR	INTERN	2020-2021
20	GAWALI HARSHADA	OMR	INTERN	2020-2021
21	HISWANKAR SHRUTI	OMR	INTERN	2020-2021
22	HIWALE SHIVA	OMR	INTERN	2020-2021
23	HUSE SHRADDHA	OMR	INTERN	2020-2021
24	JADHAV ADITYA	OMR	INTERN	2020-2021
25	JADHAV MEGHA	OMR	INTERN	2020-2021
26	JANBANDHU SIMRAN	OMR	INTERN	2020-2021
27	JOSHI VEDIKA	OMR	INTERN	2020-2021
28	KADAM MAYURI	OMR	INTERN	2020-2021
29	KARALE PALLAVI	OMR	INTERN	2020-2021
30	KHOLE MANALI	OMR	INTERN	2020-2021
31	KULKARNI PRAGATI	OMR	INTERN	2020-2021
32	MAHALE PARAG	OMR	INTERN	2020-2021
33	MALI SEJAL	OMR	INTERN	2020-2021
34	MHATRE SNEHAL	OMR	INTERN	2020-2021
35	MOMIN SHIMRAH	OMR	INTERN	2020-2021
36	NAGARGOJE	OMR	INTERN	2020-2021

PROFESSOR & HEAD
Dept. Of Oral Medicine & Radiology
D Y Patil Dental School
D Y Patil Knowledge City
Charoli (Bk), Via Lohegaon, Pune - 412105

	KIRAN			
37	NALAWADE SHALAKA	OMR	INTERN	2020-2021
38	NANDY KOYENA	OMR	INTERN	2020-2021
39	NIKITA GAUTAM	OMR	INTERN	2020-2021
40	PANDEY ANAMIKA	OMR	INTERN	2020-2021
41	PARANKAR SHWETA	OMR	INTERN	2020-2021
42	PARASKAR VAIDEHI	OMR	INTERN	2020-2021
43	PATEL ANKIT	OMR	INTERN	2020-2021
44	PATIL NEHA	OMR	INTERN	2020-2021
45	PATIL SHRADDHA	OMR	INTERN	2020-2021
46	PERKE APURVA	OMR	INTERN	2020-2021
47	PERKE RACHANA	OMR	INTERN	2020-2021
48	QURESHI SHOAIB	OMR	INTERN	2020-2021
49	ROKADE ABHIJEET	OMR	INTERN	2020-2021
50	SARAG SAMRUDDHI	OMR	INTERN	2020-2021
51	SARDAR NEHA	OMR	INTERN	2020-2021
52	SAXENA GAZAL	OMR	INTERN	2020-2021
53	SHAIKH BATUL	OMR	INTERN	2020-2021
54	SHAIKH SUFIYAN	OMR	INTERN	2020-2021
55	SHAIKH YUMNA	OMR	INTERN	2020-2021
56	SHINDE AISHWARYA	OMR	INTERN	2020-2021
57	SHINDE VAIBHAV	OMR	INTERN	2020-2021
58	SOHONI VISHAKHA	OMR	INTERN	2020-2021
59	SONUNE MAYURI	OMR	INTERN	2020-2021
60	SURYAWANSHI MANSI	OMR	INTERN	2020-2021
61	THAKUR TITIKSHA	OMR	INTERN	2020-2021
62	THOPATE NIKITA	OMR	INTERN	2020-2021
63	WAGHMARE VAIBHAV	OMR	INTERN	2020-2021
64	WANMALI PRACHI	OMR	INTERN	2020-2021
65	NAITAM TOSH KUMAR	OMR	INTERN	2020-2021
66	PUROHIT RAHUL	OMR	INTERN	2020-2021
67	MHASKAR SHIVANI	OMR	INTERN	2020-2021
68	DEORA CHITRANGADA	OMR	INTERN	2020-2021
		OMR	INTERN	2020-2021
69	WAGHMODE RUTUJA	OMR	INTERN	2020-2021
70	SUSHMITA LAKHE	OMR	INTERN	2020-2021
71	Deshmukh Samruddhi	OMR	INTERN	2020-2021

PROFESSOR & HEAD
Dept. Of Oral Medicine & Radiology
D Y Patil Dental School
D Y Patil Knowledge City
Charoli (Bk), Via Lohegaon, Pune - 412105.

LIST OF STUDENTS TRAINED FOR TCC

(INTERN BATCH – YEAR 2021- 2022)

oll No	Name	NAME OF THE DEPARTMENT	BATCH	YEAR
1	Ajmera Krishna	OMR	INTERN	2021-2022
2	Ajrekar Iftisam	OMR	INTERN	2021-2022
3	Ashte Swaraj	OMR	INTERN	2021-2022
4	Awhale Ankita	OMR	INTERN	2021-2022
5	B Lakshmi	OMR	INTERN	2021-2022
6	Bhasge Prashant	OMR	INTERN	2021-2022
7	Bhimani Priyansh	OMR	INTERN	2021-2022
8	Chheda Reet	OMR	INTERN	2021-2022
9	Deglurkar Nidhi	OMR	INTERN	2021-2022
10	Deole Nishika	OMR	INTERN	2021-2022
11	Deshmukh Ishwari	OMR	INTERN	2021-2022
12	Deshpande Akshada	OMR	INTERN	2021-2022
13	Dhaigude Snehal	OMR	INTERN	2021-2022
14	Dhaybar Shreya	OMR	INTERN	2021-2022
15	Dole Ruta	OMR	INTERN	2021-2022
16	Edlawar Apoorva	OMR	INTERN	2021-2022
17	Funde Sneha	OMR	INTERN	2021-2022
18	Gaikwad Parinaya	OMR	INTERN	2021-2022
19	Gupta Arush	OMR	INTERN	2021-2022
20	Gurav Dipti	OMR	INTERN	2021-2022
21	Gutte Varsha	OMR	INTERN	2021-2022
22	Hange Anuja	OMR	INTERN	2021-2022
23	Jagtap Komal	OMR	INTERN	2021-2022
24	Kachave Pallavi	OMR	INTERN	2021-2022
25	Kadam Gautami	OMR	INTERN	2021-2022
26	Kadam Pooja	OMR	INTERN	2021-2022
27	Kadam Shivani	OMR	INTERN	2021-2022
28	Kanase Rachana	OMR	INTERN	2021-2022
29	Karadkhele Aditi	OMR	INTERN	2021-2022
30	Kedar Priyanka	OMR	INTERN	2021-2022
31	Khade Pushpak	OMR	INTERN	2021-2022
32	Khade Shital	OMR	INTERN	2021-2022
33	K Rahul	OMR	INTERN	2021-2022
34	Khodke Rita	OMR	INTERN	2021-2022

PROFESSOR & HEAD
Dept. Of Oral Medicine & Radiology
D Y Patil Dental School
D Y Patil Knowledge City
Charoli (Bk), Via Lohegaon, Pune - 412105.

35	Kokate Akshay	OMR	INTERN	2021-2022
36	Kolhe Shivani	OMR	INTERN	2021-2022
37	Kulkarni Shruti	OMR	INTERN	2021-2022
38	Kumbhar Tanvi	OMR	INTERN	2021-2022
39	Lohtia Vishakha	OMR	INTERN	2021-2022
40	Londhe Neha	OMR	INTERN	2021-2022
41	Mahajan Piyush	OMR	INTERN	2021-2022
42	M. Divya	OMR	INTERN	2021-2022
43	M.Rutuja	OMR	INTERN	2021-2022
44	M. Unnati	OMR	INTERN	2021-2022
45	Maurya Anurag	OMR	INTERN	2021-2022
46	Maurya Monika	OMR	INTERN	2021-2022
47	Mehre Kshitija	OMR	INTERN	2021-2022
48	Menghani Nikhil	OMR	INTERN	2021-2022
49	Mishra Adarsh	OMR	INTERN	2021-2022
50	Mudsinge Ankita	OMR	INTERN	2021-2022
51	Nadarge Madura	OMR	INTERN	2021-2022
52	Naik Divya	OMR	INTERN	2021-2022
53	Narawade Hemangi	OMR	INTERN	2021-2022
54	Nikam Pratiksha	OMR	INTERN	2021-2022
55	Ostwal Bhavna	OMR	INTERN	2021-2022
56	Padsalgi Komal	OMR	INTERN	2021-2022
57	Panchal Shriyash	OMR	INTERN	2021-2022
58	Panade Sachin	OMR	INTERN	2021-2022
59	Patil Divya	OMR	INTERN	2021-2022
60	Patil Komal	OMR	INTERN	2021-2022
61	Patil Krutika	OMR	INTERN	2021-2022
62	Patil Leena Sanjay	OMR	INTERN	2021-2022
63	Patil Pornima	OMR	INTERN	2021-2022
64	Patil Pranav	OMR	INTERN	2021-2022
65	Patil Rupal	OMR	INTERN	2021-2022
66	Patil Sanika	OMR	INTERN	2021-2022
67	Rajagopal Anshika	OMR	INTERN	2021-2022
68	Rankawat Roshni	OMR	INTERN	2021-2022
69	Raut Monika	OMR	INTERN	2021-2022
70	Raut Uzair	OMR	INTERN	2021-2022
71	Roy Tanya	OMR	INTERN	2021-2022
72	Sarswat Qashish	OMR	INTERN	2021-2022
73	Sawant Varsha	OMR	INTERN	2021-2022
74	Saxena Muskaan	OMR	INTERN	2021-2022
75	Shah Deep	OMR	INTERN	2021-2022

PROFESSOR & HEAD
Dept. Of Oral Medicine & Radiology
D.Y Patil Dental School
D.Y Patil Knowledge City
Charoli (Bk), Via Lohegaon, Pune - 412

76	Sharma Prachi	OMR	INTERN	2021-2022
77	Shelke Mukta	OMR	INTERN	2021-2022
78	Shinde Shubham	OMR	INTERN	2021-2022
79	Shinde Shradhda	OMR	INTERN	2021-2022
80	Surakshya Shruti	OMR	INTERN	2021-2022
81	Tambe Neha	OMR	INTERN	2021-2022
82	Thakur Niranjan	OMR	INTERN	2021-2022
83	Tripathi Vaishnavi	OMR	INTERN	2021-2022
84	Vidhate Manjiri	OMR	INTERN	2021-2022
85	W Shivani	OMR	INTERN	2021-2022
86	Zavar Harshali	OMR	INTERN	2021-2022
87	Zote Ashwin	OMR	INTERN	2021-2022
88	Ankita Vargude	OMR	INTERN	2021-2022

PROFESSOR & HEAD
Dept. Of Oral Medicine & Radiology
D Y Patil Dental School
D Y Patil Knowledge City
Charoli (Bk), Via Lohegaon, Pune - 412105.

LIST OF STUDENT'S TRAINED FOR TCC (INTERN BATCH – YEAR 2022-2023)N				
Roll no.	**Name**	**OMR**	**BATCH**	**YEAR**
1.	AMBATKAR SAKSHI SADANAND	OMR	INTERN	2022-2023
2.	BAILE SHIVKRISHNA KRANTIKAR	OMR	INTERN	2022-2023
3.	BALGUDE TRUPTI SANJAY	OMR	INTERN	2022- 2023
4.	BARI MRUNALI GOPAL	OMR	INTERN	2022- 2023
5.	BHANSALI PRINCE SUSHIL	OMR	INTERN	2022- 2023
6.	BHATTI HARDIK RAHUL	OMR	INTERN	2022- 2023
7.	BHISE ROHINI BALU	OMR	INTERN	2022- 2023
8.	BHUTKAR ARYA ANIL	OMR	INTERN	2022- 2023
9.	CHANDORKAR ISHAN ASHISH	OMR	INTERN	2022- 2023
10	CHANGMAYUM ESHITA	OMR	INTERN	2022- 2023
11	CHAVAN SHRADDHA ASHOKRAO	OMR	INTERN	2022- 2023
12	CHIDDARWAR JANHAVI ATUL	OMR	INTERN	2022- 2023
13	DARADE AMIT SUMANT	OMR	INTERN	2022- 2023
14	DESHMANE ADITI ARUN	OMR	INTERN	2022- 2023
15	DESHMUKH SAKSHEE SURYAKANT	OMR	INTERN	2022- 2023
16	DODIA RUCHI BIPIN	OMR	INTERN	2022- 2023
17	DUGANI SNEHAL MURGENDRA	OMR	INTERN	2022- 2023
18	GAIKWAD ABHAY SHAHAJI	OMR	INTERN	2022- 2023
19	GAIKWAD ANKITA DATTATRAY	OMR	INTERN	2022- 2023
20	GARG KASHISH SANJAY	OMR	INTERN	2022- 2023
21	GOWAIKAR RUCHA SANJAY	OMR	INTERN	2022- 2023
22	GUDADHE TRUPTI JAYANT	OMR	INTERN	2022- 2023
23	HALAGERI PARVATI BASAVRAJ	OMR	INTERN	2022- 2023
24	JAMNA SANIYA ILIYAS	OMR	INTERN	2022- 2023
25	JHAWAR AKSHATA RAMKISHOR	OMR	INTERN	2022- 2023
26	KAMBLE MRUNAL VIJAY	OMR	INTERN	2022- 2023
27	KANPILE SAKSHI CHETAN	OMR	INTERN	2022- 2023
28	KEKARE NIRMITI DASHRATH	OMR	INTERN	2022- 2023
29	KHAKAR SWAROOP ARUN	OMR	INTERN	2022- 2023
30	KULKARNI HARSH MILIND	OMR	INTERN	2022- 2023
31	LOKHANDE PRATIKSHA	OMR	INTERN	2022- 2023

PROFESSOR & HEAD
Dept. Of Oral Medicine & Radiology

	NARHARI			
32	LOLAGE VAISHANVI	OMR	INTERN	2022- 2023
33	LONDHE SIDDHESH ANIL	OMR	INTERN	2022- 2023
34	LONDHE VINIT MAHADEO	OMR	INTERN	2022- 2023
35	LONKAR SAKSHI SANDIP	OMR	INTERN	2022- 2023
36	MAGAR SHREYAS ASHOK	OMR	INTERN	2022- 2023
37	MAHAJAN JUI SHASHANK	OMR	INTERN	2022- 2023
38	MALI PRERNA RAJESH	OMR	INTERN	2022- 2023
39	MANE ONKAR VINAYAK	OMR	INTERN	2022- 2023
40	MANEK SRUSHTI RAJESH	OMR	INTERN	2022- 2023
41	MAURYA KHUSABU	OMR	INTERN	2022- 2023
42	MISHRA SHUBHAM SANJAY	OMR	INTERN	2022- 2023
43	MOHITE AISHWARYA ULHAS	OMR	INTERN	2022- 2023
44	MOMIN RUSHNA ISHTIYAQUE AHMED	OMR	INTERN	2022- 2023
45	MORE AMRUTA BALDEO	OMR	INTERN	2022- 2023
46	MULIK SIDDHI SAMBHAJI	OMR	INTERN	2022- 2023
47	MUNIFA NAZ MOHAMMAD RAFIQUE	OMR	INTERN	2022- 2023
48	NARKHEDE SAKSHI SHRIKANT	OMR	INTERN	2022- 2023
49	NARSULE DIVYA ARVIND	OMR	INTERN	2022- 2023
50	NARWADE SHYAM VIJAY	OMR	INTERN	2022- 2023
51	PATEL RIDDHI HARESH	OMR	INTERN	2022- 2023
52	PATIL DEVYANI NANDKISHOR	OMR	INTERN	2022- 2023
53	PATIL HARSHADA ULHASRAO	OMR	INTERN	2022- 2023
54	PATIL JAGRUTI SATISH	OMR	INTERN	2022- 2023
55	PATIL PAWAN SATISH	OMR	INTERN	2022- 2023
56	PAWAR RUTUJA RAMNATH	OMR	INTERN	2022- 2023
57	PHALKE MRUNAL UMESH	OMR	INTERN	2022- 2023
58	PHARATE SHWETA EKNATH	OMR	INTERN	2022- 2023
59	RAUT AISHWARYA SHIVLING	OMR	INTERN	2022- 2023
60	SALIYAN SHRUTI SURESH	OMR	INTERN	2022- 2023
61	SAWANT ROHINI BHARAT	OMR	INTERN	2022- 2023
62	SHAIKH RUHMA ARIF	OMR	INTERN	2022- 2023
63	SHEKAPURE AISHWARYA BALAJI	OMR	INTERN	2022- 2023
64	SHELKE OMKAR NANASAHEB	OMR	INTERN	2022- 2023
65	SHETE VRUSHALI SANJAY	OMR	INTERN	2022- 2023
66	SHINDE PRAJAKTA SADASHIV	OMR	INTERN	2022- 2023

PROFESSOR & HEAD
Dept. Of Oral Medicine & Radiology
D Y Patil Dental School
D Y Patil Knowledge City
Charoli (BK), Via Lohegaon, Pune - 412105.

67	SHINGADE ADITYA RAGHU	OMR	INTERN	2022- 2023
68	SONAR BHUVANESHWARI PANKAJ	OMR	INTERN	2022- 2023
69	SONAWANE KANCHAN RAVINDRA	OMR	INTERN	2022- 2023
70	SONAWANE SANGRAM SANJAY	OMR	INTERN	2022- 2023
71	SPRIHA SINGH	OMR	INTERN	2022- 2023
72	SURYAWAD RUTUJA RAOSAHEB	OMR	INTERN	2022- 2023
73	SURYAWANSHI VIJAYALAXMI MAHENDRA	OMR	INTERN	2022- 2023
74	TAMBE SAMRUDDHI SARASRAM	OMR	INTERN	2022- 2023
75	UGRAN SHRADDHA VIJAYKUMAR	OMR	INTERN	2022- 2023
76	WARAL CHETAN SUNIL	OMR	INTERN	2022- 2023
77	PUSHPAK KHADE	OMR	INTERN	2022- 2023

PROFESSOR & HEAD
Dept. Of Oral Medicine & Radiology
D Y Patil Dental School
D Y Patil Knowledge City
Charoli (Bk), Via Lohegaon, Pune - 412105.

List of Students Trained

Aesthetic Clinic

DY PATIL DENTAL SCHOOL, LOHEGAON, PUNE

DEPARTMENT OF CONSERVATIVE DENTISTRY AND ENDODONTICS

LIST OF STUDENTS TRAINED IN ESTHETIC CLINIC

SR NO.	NAME	MONTH
1.	EDLAWAR APOORVA SANJAY	AUGUST 2022
2.	KEDAR PRIYANKA JALINDAR	AUGUST 2022
3.	PANADE SACHIN BHIMRAO	SEPTEMBER 2022
4.	ZOTE ASWINI ANAND	OCTOBER 2022
5.	ZAVAR HARSHALI PRAVIN	OCTOBER 2022
6.	CHOUDHARY VAISHNAVI VINOD	NOVEMBER 2022
7.	GAIKWAD PRASAD JALINDAR	NOVEMBER 2022
8.	JADHAV ROHINI BHARAT	DECEMBER 2022
9.	NIKAM SHRADDHA ARJUN	DECEMBER 2022
10.	ROKDE ALISHA SHIVRAM	JANUARY 2023
11.	TARDE ABHISHEK VIKAS	FEBRUARY 2023
12.	POOJARY NIKITA PRABHAKAR	MARCH 2023
13.	PATIL TEJASWINI MAHENDRA	APRIL 2023
14.	KHARAT TEJAS SITARAM	JULY 2023
15.	— RAJE MANJIRI	AUGUST 2023
16.	LOKHANDE VISHWAJEET	AUGUST 2023
17.	PADWAL SHRADDHA	AUGUST 2023

PROFESSOR & HEAD
Dept. of Conservative Dentistry
& Endodontics
D Y Patil Dental School
D Y Patil Knowledge City
Charoli (Bk), Via Lohegaon, Pune - 412105

CASE HISTORY

CASE HISTORY

Department of Oral Medicine & Radiology



D Y PATIL DENTAL SCHOOL

Dr. D. Y. Patil Knowledge City, Charholi (BK) Via- Lohegaon, Pune- 412105

JOURNAL OF
ORAL MEDICINE AND RADIOLOGY

NAME : Mr. Shivkrishna Ishankar Bagle

ROLL NO.: 02 **BATCH :** A

YEAR: 2022 - 2023 Summer new B.D.S

MUHS Seat No.: 49549

D Y PATIL GROUP

D Y PATIL DENTAL SCHOOL

Dr. D. Y. Patil Knowledge City, Charholi (BK) Via- Lohegaon, Pune- 412105

JORNAL OF

Oral MEDICINE AND RADIOLOGY

CERTIFICATE

This is certify that Mr. /Ms. : Shivkrishna K. Baile

Roll No. 02 (49549) *has Attended and Completed all*

the Practicals Recorded in this lournal.

Date : _____

Signature of The Head

PROFESSOR & HEAD
Dept. Of Oral Medicine & Radiology
D Y Patil Dental School
D Y Patil Knowledge City
Charoli (Bk), Via Lohegaon, Pune - 412105.

Signature of The Staff

INDEX FOR OPDs

SR.NO	DATE	PATIENT'S NAME	CASE NO.	AGE	GENDER	STAFF'S SIGNATURE
01	24/11	Seema Sankpal	81358	31	F	
02	24/11	Anand Kumar	39807	35	m	
03	23/11	Udhav Mehetre	81156	52	m	
04	25/11	Nitinkumar Pal	81457	40	m	
05	20/11	Sandeep Kumar	81456	47	m	
06	29/11	Vishal Bhosale	62215	25	m	
07	29/11	Veena Thakare	62314	29	f	
08	8/3	Suchita Gabhale	80371	24	f	
09	8/3	Gautam Gaikwad	80372	44	m	
10	9/3	Sapna Dave	80373	34	F	
11	10/3	Nanda Gaikwad	80379	56	F	
12	10/3	Rupita Mohite	80342	32	f	
13	11/3	Ankur Singhal	31445	32	m	
14	11/3	Sandesh Karmale	89936	29	m	
15	11/3	Nakhi Gunjal	8944	22	m	
16	15/3	Suvarna Jadhav	8061	23	f	

INDEX FOR OPDs

SR.NO	DATE	PATIENT'S NAME	CASE NO.	AGE	GENDER	STAFF'S SIGNATURE
17	15/3	Pankaj Borade	89739	27	m	
18	15/3	Kaushalya Rokade	89744	55	f	
19	16/3	Kamal Bansode	89897	60	f	
20	17/3	Dynashwar Badguiar	89940	37	m	
21	6/10	Kala Kotwal	107300	28	f	
22	7/10	Sarika Bandave	10735	36	f	
23	7/10	Arati Mahajan	107308	48	f	
24	7/10	Chanda devi	107311	48	f	
25	8/10	Kunal gungal	107416	31	m	
26	8/10	Rohit Pawar	107417	26	m	
27	8/10	Sheetal adav	107428	24	f	
28	10/10	Supriya iyer	107516	32	f	
29	10/10	Nagesh Telange	107519	23	m	
30	10/10	Akash malve	107523	23	m	
31	10/10	mukesh meena	107521	21	f	
32	12/10	Vaibhav Bhapkar	107742	21	m	
33	12/10	Santosh Zaptkar	107745	35	m	
34	14/10	Sangeta Gaikwad	107948	31	f	
35	14/10	Nisha chandane	107948	30	f	
36	14/10	Aman agarwal	107949	28	m	
37	14/10	Amar more	107950	33	m	
38	14/10	monali Jadhav	109951	25	f	
39	14/10	Laxmibay vlamulay	107952	73	f	
40	15/10	Jitendra gupta.	107953	28	m	
41	15/10	Pushpa. Jhashi	107954	63	f	
42	15/10	Gayatri Budhke	107955	21	f	
43	15/10	Dattaray mahe	107956	26	m	
44	15/10	mari Borekar	107957	30	f	
45	15/10	Gopal giri.	107958	30	m	
46	15/10	Jahanvi more	107959	36	f	
47	15/10	Pushpa Garad	107960	11	f	
48	13/10	Sangeeta Tikar	107961	48	f	

INDEX FOR OPDs

SR.NO	DATE	PATIENT'S NAME	CASE NO.	AGE	GENDER	STAFF'S SIGNATURE
49	15/10	manohar kaur	107963	38	f	
50	15/10	pancham kumari	107964	35	f	
51	18/10	Ranjeet patil	107965	21	m	
52	20/10	Shravan idewar	107966	21	m	
53	20/10	Babynanda Lanjewar	107967	85	f	
54	20/10	Raju waghmare	107968	20	m	
55	20/10	madhuri Nagot	107969	28	f	
56	20/10	Adidya Gaikwad	108 [illegible]	20	m	
57	20/10	pratik Paul	108 382	21	m	
58	21/10	Samir shaikh	1 64 [illegible]	37	m	
59	22/10	Govind Sawant	108678	45	m	
60	22/10	pratik Paul	108 [illegible]	21	m	
61	22/10	Deepak sonawane	108994	34	m	
62	22/10	Abeet Kaloke	120294	33	m	
63	22/10	Haryman sonone	120297	66	m	
64	22/10	Girish Jadhav	120388	38	m	
65	22/10	Nisar shaikh	120390	58	m	
66	27/12	sapna patil	120392	23	f	
67	27/12	Lokesh Gaikwad	120391	53	m	
68	27/12	Urmilla agarwal	120393	52	f	
69	27/12	Ravi Rao	120394	26	m	
70	27/12	Dhumush Chungani	82867	43	m	
71	27/12	Angali Chungani	80378	43	f	
72	27/12	santosh Nagawale	120395	24	m	
73	28/12	Pradip sonawane	123396	60	m	
74	28/12	Sureksha sonawane	120397	50	f	
75	28/12	Ganesh Nanwade	120398	18	m	
76	28/12	manulaxmi gallape	120399	25	f	
77	28/12	Pooja Pandey	120400	21	f	
78	28/12	Deepali Bhoi	120393	31	f	
79	01/13	Asavi salunke	120495	10	m	
80	01/13	Yogesh salunke	120494	39	m	

INDEX FOR OPDs

SR.NO	DATE	PATIENT'S NAME	CASE NO.	AGE	GENDER	STAFF'S SIGNATURE
81	01/3	Bhimrao Chire	120496	32	m	
82	01/3	Priyanka Sonwane	120497	26	f	
83	01/3	Jagannath Sonawane	120498	50	t	
84	01/3	Surekha Kardong	12093	56	f	
85	01/3	Nikhil Rathod	114900	67	f	
86	1/3	Vikas Pedurkar	126499	23	m	
87	2/3	Faisal Khan	125500	54	m	
88	2/3	Deepak Balchandra	125501	43	m	
89	2/3	Jayeshree Bhoir	117450	32	t	
90	2/3	Deepak verma	120503	25	m	
91	2/3	Murlidhar Vyas	120504	44	m	
92	2/3	Monini Pathak	120504	32	t	
93	2/3	Priya Yettkar	120505	36	f	
94	3/3	Shevani vare	120693	24	t	
95	3/3	Pushpa Wanka	120694	62	m	
96	3/3	Ayush Gawande	120696	5	m	
97	3/3	Amol Vithusone	120698	38	m	
98	3/3	Rekha Gaikar	120506	23	t	
99	3/3	Kavita Bansode	120699	38	t	
100	3/3	Pradeep mandkar	120822	62	m	
101	3/3	Vijaya dhavale	12009	40	t	
102	3/3	Rajesh Phurate	120811	7	m	
103	3/3	Subeda Khan	120815	60	m	
104	3/3	Smruti Phondge	120821	44	f	
105	3/3	Fauji Aiman	120822	32	m	
106	4/3	Mundungiri Thorave	120824	31	m	
107	4/3	Ramesh Gaikwad	120835	36	m	
108	4/3	Akash Sonawani	33601	30	m	
109	4/3	Mukesh Bandekar	45142	38	m	
110	4/3	Surekha munde	14209	21	f	
111	4/3	Shyam andre	64397	34	m	
112	4/3	Dhanashri Inamdar	120821	20	f	

INDEX FOR OPDs

SR.NO	DATE	PATIENT'S NAME	CASE NO.	AGE	GENDER	STAFF'S SIGNATURE
113	4/3	Sneha Bankar	120923	33	F	
114	4/3	Shivam Bankar	120927	40	m	
115	4/3	Shivani sutar	120880	20	f	
116	4/3	musamil anand	120943	28	m	
117	4/3	Vivek Pipkar	97754	32	m	
118	4/3	Jayashree Gaikwad	121026	60	f	
119	6/3	Ganesh Sonawane	121048	42	f	
120	6/3	sakaar. Kshitriya	121030	23	m	
121	8/3	Balasaheb Khadke	21027	61	m	
122	8/3	Neelem Dhotre	121042	28	f	
123	8/3	Rekha Tashriwal	121041	30	f	
124	9/3	Kaus sayed	121036	50	m	
125	9/3	Akshay Dagwkes	121043	26	m	
126	9/3	vishal wankhade	121044	26	m	
127	9/3	Sopan Narawale	12146	33	f	
128	10/3	Ramesh washi	1247	68	m	
129	10/3	Baliram Loi	42537	50	m	
130	10/3	Ganesh Kotwal	4367	40	m	
131	10/3	saugandha khan	121153	10	m	
132	10/3	Shivam pandey	121155	24	m	
133	11/3	Sneha Kurde	121247	54	m	
134	11/3	Sampda Gawali	121248	50	f	
135	11/3	Yash Pathare	121231	16	m	
136	11/3	Aishya Pakole	81542	25	m	
137	11/3	Seema Thugal	1215036	47	f	
138	11/3	manisha Deshmukh	1250	30	m	
139	11/3	Laxmi Kshirsagar	121260	41	f	
140	11/3	mandev mankar	121262	05	m	
141	11/3	omkar Pawar	9857	23	m	
142	11/3	Sidhu Kanade	121263	29	m	
143	11/3	Sachin Kumar	121369	35	m	
144	11/3	Khushi Pawar	121372	07	f	
145	11/3	akansha Kakade	121373	24	m	
146	11/3	sukhiram Thapa	121390	47	m	
147	11/3	akshay sawant	121309	27	m	
148	11/3	shruti mahajan	121393	09	f	
149	11/3	Tritesh Bhansali	121394	10	m	
150	11/3	Amit Gaikwad	121395	17	m	
151	11/3					

INDEX FOR CASE HISTORIES

SR.NO	DATE	PATIENT'S NAME	CASE NO.	AGE GENDER	GRADE	STAFF'S SIGNATURE
01	7/10	Kajal Kotural	107300	28 F		
02	14/10	Sangeta Gaikwad	107990	30 f		
03	17/10	Sujata Chavan	107993	40 f	B+	
04	19/10	Sukiram Thapa	107998	48 m	B	
05	28/3	Ajeet Deshpande	179095	36 m	B+	
06	8/3	Balasheeb Khandu	121080	61 m	4/1	
07	20/10	Prathibha Dongre	16364	32 F	4/2	
08	17/3	Santosh Gaikwad	80938	48 m		
09	7/10	Vijay Jagdale	170993	54 m	B	
10	05/06	Ram Kumar Yadav	128520	24 m		

INDEX FOR RADIOGRAPHIC TECHNIQUES

SR. NO.	DATE	PATIENT'S NAME	CASE NO.	AGE GENDER	X-RAY REGION	GRADE	STAFF'S SIGNATURE
01	24/11	Shryash Shigare	49149	12 m	5	A	
02	24/11	Shryas hingare	49149	12 m	6		
03	25/11	Sangeta chowdri	81433	47 f	8	A	
04	23/11	asha Khumbhar	81446	35 F	7	A	
05	25/11	asha Khumbhar	81446	35 F	6	A	
06	25/11	Niti Kumar Pal	25113	40 m	1	B	
07	26/11	Sandeep Kadam	81545	43 m	3		
08	30/11	AS Bhalle	81872	48 m	6	A	An
09	7/3	Sharukh	5634	26 m	78	A	
10	7/3	sharukh	5634	26 m	876		
11	7/3	Amruta gaikwad	57784	26 f	5	A	
12	8/3	harshita agarwal	53092	7 f	74 75	B	
13	10/3	rupta monite	89342	32 f	5	A	
14	11/3	rekha Phadtare	53294	39 f	4		
15	11/3	Shanta Chitare	89424	49 F	7	B+	
16	14/3	Suwarna Jadhav	53251	23 F	7	B+	
17	14/3	arun Kodre	5361	58 m	8		
18	15/3	Kirti singh	5341	17 f	5	A	
19	16/3	Komal Bansode	89817	60 F	87	B+	
20	8/10	santosh Barde	107399	46 F	56		
21	8/10	sonam shah	62083	9 f	74	A	
22	8/10	urunda Jhoshi	62728	30 F	5		
23	11/10	urunda Jhoshi	62728	30 f	6		
24	11/10	sonam shah	107623	8 f	75		
25	11/10	sonam shah	107023	8 f	14		
26	11/10	pradeep Jadav	107028	40 m	7	A	As
27	12/10	ayan gaikwad	107624	4 m	74 75		
28	15/10	Vaibhav bapkar	107742	21 m	7		
29	15/10	ganesh gupta	10743	6 m	ED		
30	15/10	pallavi sarsavnshi	10745	31 f	5		As
31	15/10	gayatri Buchk	10746	21 f	6		
32	15/10	aryadna makar	61777	6 f	64		

INDEX FOR RADIOGRAPHIC TECHNIQUES

SR. NO.	DATE	PATIENT'S NAME	CASE NO.	AGE GENDER	X-RAY REGION	GRADE	STAFF'S SIGNATURE
33	18/10	Chaya Khilari	108073	32 f	7		
34	20/10	Rangeet Pati	08262	21 m	6		
35	20/10	Surbhan Merkar	108474	60 f	6		
36	20/10	Joyti Jadhav	108476	29 f	8		
37	21/10	Prathiba Dongre	108577	32 f	65	B+	
38	22/10	Sammer Shaikh	108582	37 m	6	B+	
39		Arisha Shaikh	108677	4 f	65	B+	
40		Depali Bhoir	114900	34 f	7		
41		Mrulidhar Vyas	120443	67 m	4		
42		Mrulidhar Vyas	120491	23 m	8		
43		Mrulidhar Vyas	120493	47 m	6		
44		Seren Kardong	120500	39 m	5		
45		Nokat Rathod	120499	23 m	7	A	
46		Prakash Yittkar	120596	25 m	6		
47		Shivam Chowdary	120604	40 m	6		
48		Nagma Tyagi	120606	29 f	6		
49		Somnath Ghokle	120607	40 m	6		
50		Paramgeet Kaur	120609	29 f	5	A	
51		Swara Pati	126702	4 f	6		
52		Rasa Kohli	120704	28 m	4		
53		Shruti Salve	120706	23 F	75		
54		Gyanav Sharma	11667	9 m	85		
55		Godavri Surjavshi	11990	74 F	6		
56		Tanway Jawale	1120817	6 m	7		
57		Chaya Jawale	120819	30 F	64,65		
58		Mangala Patil	12083	64 f	8	A	
59		Balashab Jagde	120902	61 m	75		
60		Ridhi Sapkal	120918	33 F	8		
61		Sapnali Panchal	105157	29 m	2		
62		Prathamesh Tant	120919	19 m	7		
63		Dhanashri Jhoshi	120922	50 F	6		
64		Papu Chowdri	119203	40 m	7		

INDEX FOR RADIOGRAPHIC TECHNIQUES

SR. NO.	DATE	PATIENT'S NAME	CASE NO.	AGE GENDER	X-RAY REGION	GRADE	STAFF'S SIGNATURE
65		Shuman Bankar	120025	25 F	5		
66		Shitia Badjkar	11988	26 f	1		
67		Shitia Baikar	11988	26 f	6		
68		Shivani Suttar	120927	26 f	6		
69		Balasheb Khandre	121030	61 m 48 F	36,37		
70		Sushila Bhushe	120081	48 F 61 m	27		
71		Jagana Jhadra	121032	59 m	2	A	
72		Jangana Jhaav	121032	59 m	5		
73		Shoba Kharade	121247	59 m			
74		Shoba Kharde	121247	59 m	3		
75		Shoba Kharde.	121247	59 m	5		
76		Jeevan Batung	121250	16 m	7		
77		Yash Patole	121251	26 m	6		
78		Lata Ahale	121246	46 F	6		
79		Gopal Mall	121368	46 m	4		
80		Ashok Das	117680	75 m	6		
81		Rahul Kadar	120181	27 m			
82		Sandeep Salve	121378	47 m	7		
83		Sandeep Salve	121378	23 F	7		
84		Jalekha Patel	101067	43 F	6		
85		Jalekha Patel	94549	27 m	6		
86		Vaishnavi Paste	94591	30 F	7	B++	
87		Akshay Savant	121390	9 m	7		
88		Supriya Kamble	121394	30 F	7		
89		Angand Khundge	121388	9 m	5		
90		Sushjala Jagtap	121340	29 f	6		
91		Ridhi Sapkal	120918	33 f	7		
92		Dhanshree Jhushi	120922	50 f	6		
93		Papu Chowdry	119203	40 m	1		
94		Shimon Bnkr	120925	25 f	8	A	An

INDEX FOR RADIOGRAPHIC INTERPRETATIONS

SR. NO.	DATE	PATIENT'S NAME	CASE NO.	AGE GENDER	X-RAY REGION	GRADE	STAFF'S SIGNATURE
01	29/11	Vishal Bhosale	62215	25 m	T6	B+	
02	8/3	Sumit Shaikh	63948	32 m	T6	B+	
03	8/3	Dhanashree Bedke	39990	28 F	T6	B+	
04	15/3	Suvarna Jadhav	8061	32 f	T7		
05	8/10	Rohit Pawar	107911	18 m	T6		
06	20/10	Rajeev Waghmare	107968	20m	T6		
07	27/2	Sapna Patil	120392	23 f	T6		
08	27/2	Urmila Agarwal	120393	52 F	T6		
09	27/2	Angali Chungui	80373	43 F	T4		
10	27/2	Santosh Nawarde	120395	24 m	T3		
11	28/2	Surekha Sonawane	120393	50 F	T6		
12	28/2	Mahalaxmi Gaikwad	120390	25 F	T6		
13	01/3	Bhimrao Ghire	120496	32 m	T7		
14	02/3	Deepak Verma	120503	25 m	T5	B++	
15	4/3	Surekha Munde	142509	24 f	T5	A	

01 CASE HISTROY : 01

Date: 7/10/22

Pt. Name: Kajal Kotwal — Reg No 107300

Age: 28 yrs — female

married — pune

Housewife — matrge

⇒ Chief complaint: Pt. c/o of fractured teeth and Pain in lower Right Back Region of Jaw, since 5days.

⇒ HOPI: Pt. was apperently alright 5 days back. Began experig Pain which started suddenly was dull in character and was on stimulus. Pt gave H/o Discomfort on Biting and Pain was dull in character.

⇒ History: No Relevant finding

A. Past Dental History: RC Treated 2 + 6

B. Past medical History: No Relevant finding.

C. Family History: No Relevant History

D. Personal History

1. maintainre of oral Hygiene

a. method: Brush and Paste; Horizontally

b. frequency: 1/day.

2. Dietary habits

→ mixed diet

3. Tissue Abuse History

→ Alcohol NRF yrs NRF times/day

→ Bidi NRF yrs NRF times/day

→ others NRF yrs NRF times/day.

⇒ Examination

A. Genereal examination

1. Built: Ectomorphic

2. Gait: No abnormality detected

3. Skin : Normal

4 vital sigin

→ Temperature: afebril → Respiratory rate: 16 cycle/m

→ Pulse rate: 73 beats/min → B/P :- -

→ examination of Sigins: No Relevant findyng.

B. Extra oral examination

1. facial symetrey : grossly symetrical and profile straight profile.

2. eyes: NAD 3. ears: NAD 4. Nose: NAD

5. Lips: Competent

6. TMJ: Normal, movement: Normal

7. Lymph Node: Non-Tender and Non Palpable.

8. muscle of mastication: NAD

9. Salivary gland NAD

C. Intra-oral examination

A. Soft tissue examination

1. Labial mucosa: NRF

2. Buccal mucosa: NRF

3. Tounge: NRf

4. Lips: NRf

5. soft palate: NRF

6. Hard Palate: NRf

7. floor of mouth

- whartons : NAD

- Lingual vari casity : absent

8. Gingival examination

- color: Pink to Brown, - B.O.P: tve.

- Presence of stippling, - consistency: from

- size: Normal.

9. Periodontal examination : Ab

10. edentulous ridge : ab

11. Tonsillar and Aharyngeal: NAD areas

b. Hard tissue examination

1. Teeth

1. Teeth present : 48 47 46 45 44 43 42 41 | 31 32 33 34 35 ...

2. missing Teeth : 36

3. carious teeth : 46, 36, 37

4. Filled : 26 (RC Treated)

5. calculus and stain : ++

6. occlusion

- angles class I

⇒ Detailed examination of area of Chief complaint

A. teeth in the area of CC : 46

B. Swelling : No Relevant finding

→ on palpation : No Relevant finding

→ Spaces involved : No Relevant finding

⇒ Provisional Diagnosis

1. area of C.C : apical periodontitis $\bar{c}$ $\frac{+}{+}$

other diagnosis : Chronic pulpitis $\frac{\bar{c}}{+}$

gingivitis, acute pulpitis 36, 37

⇒ Investigation : IOPA $\frac{\bar{c}}{46}$

1. IOPA region : mandibular Left Back Region of Jaw.

2. Teeth completely seen 46 47 48

3. Partially seen : -

4. Anatomical Land marks

	Radiopaque	Radiolucent
a. Dental	enamel, Dentin	Pulp
b. osseous	mandibular canal, Lower Border of mandible	PDL space

5. most pathologic Tooth : 46

→ crown : irregular, illdefined radiolucency seen in Distoccusal surface of tooth involving enamel, dentin and pulp

→ Roots : 2 Roots with Patent root canalas.

→ PDL space : widening in middle and apical 1/3rd.

→ Lamina Dura : continious in cervical, discontinious in middle and apical 1/3rd.

→ Periapical area : a ~~well defined~~ diffuse radiolucency seen

→ interdental bone : No abnormality.

→ Any other finding : -

6. other compltley seen teeth $\bar{c}$ $\overline{7|}$

→ crown : an well defined irregular radiolucency seen involving enamel, Dentin pulp.

→ Roots : 2 roots with patent canalas.

→ PDL space : No widining

→ Periapical area : No abnormality

→ interdental bone : No abnormality

⇒ Radiographic Diagnos : ,

1. Periapical abscess $\bar{c}$ $\overline{6|}$

⇒ Radiographic Differential Diagnos : ,

1. periapical cyst.

⇒ Radiographic faults.

1. clip mark
2. Dark radiograph
3. fixer stain

⇒ final Diagnosis

1. Periapical abscess $\bar{c}$ $\overline{6|}$
2. chronic irreversible pulptis $\bar{c}$ $\overline{7|}$
3. chronic generealized marginal gingivitis.
4. Reversible pulptis $\bar{c}$ 36, 37

⇒ Treatment Plan

1. Preliminary
   - Mefanic acid 400 mg bid 3day
   - Actiomenophen 500mg bid 3day

2. non-surgical
   - supragingival scaling

3. Restorative.
   - RCT $\bar{c}_{16}$
   - composite $\bar{c}$ 36,37

4. maintaince
   - Recall atte

for 1st yr – every 3mounth's merin

CASE HISTORY 02

Date: 14/10/22

Name: Sangeeta Gaikwad. Reg No: 107940

31, female, married, Pune, Housewife.

⇒ Chief complaint: C/o pain in Left Back Region of Jaw and pain radiates of head and ear; unilaterally.

⇒ HOPI:

pt was apperentley alright onsent was gradual duration min progress to Back of head and ear. aggrevates on mastication and pressure and relieves on medication and seep pain is dull and aching.

⇒ History

1. Past Dental History

C/o 1. H/O Root piece impaction {faulty extraction}

2. extraction $\bar{c}$ — $\bar{3}$

2. Past medical History: No Releavant History

3. family History: No Relevant History.

4. personal History

maintainle of oral Hygiene

a. method: Tooth Brush, paste, Horizontally

b. frequency: once/day.

1. Dietary habits: mixed diet

2. Tissue abuse History: NRF

⇒ Examination

A. Genereal Examination

1. Built: Ectomorphic

2. Gait: NAD

3. Skin: NAD

4. Vital sign:

→ Temp: afberil → Respiratory rate: 16 cycles/min

→ Heart rate: 68 beats/min → BP: -

5. examination of sigin : NRF

B. extra oral examination

- facial symetrey: grossly symetrical
- Eyes: NAD, - Ears: NAD, - Nose: NAD
- Lips: competent - TMJ: Normal
- Lymph node: non-tender and non-palpable
- muscles of mastication: NAD.
- salivary gland: NAD.

C. Intra oral examination

a. soft tissue examination

1. Labial mucosa: NAD
2. Buccal mucosa: NAD
3. Toungue: NAD
4. Lips: NAD
5. soft palate: NAD
6. Hard palate: NAD
7. floor of mouth: NAD
8. gingival examination

- color: pink, - BOP: +ve, - Presensce of stippling
- consistency: firm, - size: Normal

9. Periodontal examination: NAD

10. Edentulous ridge examination: NRF

11. Tonsillar and pharyngeal areas: NAD

b. Hard Tissue examination

1. Teeth present

18 17 16 15 14 13 12 11 21 22 23 24 25 26 27 28
48 47 46 45 44 43 42 41 31 32 33 34 35 36 37

- Carious teeth $\bar{c}$ 8 7 | 6 8 / 8

- Top +ve, - contact points: Normal
- Calculus and stain: Calculus +, stain: ++
- occlusion: angles class I

⇒ Detailed examination of area of chief complaint $\bar{c}$ — | 7

B. swelling: Not applicable.

Palpation: Not applicable.

any other findings: -

⇒ Provisional Diagnosis

→ related to CC : Apical periodontitis c̄ $\frac{+}{7}$

→ other diagnosis: 1. multiple dental caries

2. Acute marginal gingivitis.

3. Chronic pulpitis c̄ $\frac{+}{6}$

⇒ investigation

IOPA c̄ $\frac{+}{7}$

⇒ Radiographic Diagnosis with differential diagnosis

1. IOPA region : mandibular Left Back

2. Teeth completely seen : 36 , 37

3. Teeth Partially seen : 35

4. Anatomical landmarks

	Radiopaque	Radiolucent
a. Dental	enamel, dentin	pulp
b. osseous	mylohyoid bone	mandibular canal.
	Lamina Dura.	
	cancellous Bone	
	alveolar crest Bone	

5. most Pathological Tooth

→ Crown : intact crown with radiopaque dentin, enamel radiolucency noted m-P and D-P

→ Root : 2 roots with 2 Patent canal

→ PDL Space : No widening

→ Lamina Dura : continuous.

→ Periapical area : a radiolucency seen on Distal root end.

→ Interdental Bone : NAD

→ Any other findings: -

(6) other completely seen teeth: 36

→ Crown: NAD

→ Root: 2 Roots with patent root canal

→ PDL space: No widening

→ Lamina Dura: continious

→ Periapical area: Normal

→ Interdental Bone: NAD

(7) Radiographic Diagnosis

→ Periapical cyst c̄ 36

(8) Differential Diagnosis

→ Periapical granuloma c̄ 36

(9) Radiographic fault

1. Clip mark

2. Overfixed.

⇒ final Diagnosis.

→ Periapical cyst c̄ 36

→ Chronic irreversible pulpitis c̄ $\frac{}{6|}$

→ Reversible pulpitis c̄ $\frac{87|68}{8|}$

→ Chronic generealized marginal gingivitis

⇒ Treatment plan

1. Preliminary Phase { metanic acid 400mg bid 3day
   Actominophen 500mg bid 3day

2. non-surgical – scaling

3. Restorative

{ RCT c̄ $\frac{}{6|6}$
{ composite c̄ $\frac{87|68}{8|}$

4. maintaince

for 1st yr every 3 mounths ... merin.

CASE HISTORY 03

Date: 17/10/22

Reg No: 107943

→ Pt. Name: Sujata Chavan

41, female, married, Housewife, Lohaegoan.

⇒ Chief Complaint: Pt c/o Pain in mandibular left Back Region of Jaw since 5 days and uncleaned teeth.

⇒ HOPI: Patient was apperenHey alright 5days the Pain was gradual Lasted for min and aggrevates on mastication in Lower Left Back Region of Jaw the Pain was of Dull aching type of Pain.

⇒ History

1. Past Dental History : NRf
2. past medical History: Pt is Hypertensive and is on medication for the same.
3. family History: NRf
4. personal History:
   1. maintainie of oral Hygiene.
      a. method: Horizontal
      b. frequency: 1/day with Tooth brush and paste.
   2. Dietary habids: mixed
   3. Tissue Abuse History: NRF

⇒ Examination

A. General Examination

1. Built: Ectomorphic
2. Gait: NAD
3. Skin: NAD
4. Vital Sigan

→ Temp: afebril. → Respiratory rate: 16cycles/min

→ Heart rate: 70beats/min → BP: -

5. Examination of Sigan: NAD

B. Extra oral examination

1. facial symetery: grossly symetrical

→ Eyes: - , → Ears: - , → Nose: -

→ Lips: competent → TMJ: Normal

- lymph Node: Non Tender and non-Palpable

- muscles of mastication: - - Salivary gland: -

C. Intra oral examination

a. soft tissue examination

- Labial mucosa: NAD

- Buccal mucosa: NAD

- Tounge: NAD

- Lips: NAD

- Soft palate: NAD

- Hard Palate: NAD

- floor of mouth: NAD

- gingival examination

→ color: Physiologic pigmentation → BOP: +ve.

→ Presence of stippling - consistency: oedematous

→ Size: Reduced.

- Periodontal examination: NAD

- Tonsilar and pharyngeal area: NRF

b. Hard tissue examination

1. Teeth

- Teeth present ☹ 17 16 15 14 13 12 11 21 22 23 24 25 26 27 / 47 46 45 44 43 42 41 31 32 33 34 35 36 37

- carious teeth ☹ class I ☹ $\frac{76|7}{6|6}$

- TOP +ve: ☹ $\frac{+}{6}$

- contact point: Tight

- calculus: +, Plaque: ++

⇒ Occlusion:

- angles class I

⇒ Detailed examination of area of chief complaint

A. Teeth $\bar{1}$ $\dagger_6$

Top tve $\bar{2}$ $\dagger_6$ and Tooth surrounded by calculus.

B. swelling : NAD

C. on palpation : NAD

⇒ Provisional Diagnosis.

- to clc : apical periodontitis $\bar{2}$ $\dagger_6$
- other diagnosis : 1. dental caries $\bar{2}$ $\frac{26}{6}$ $\frac{7}{6}$
  2. Localized periodontitis $\bar{1}$ $\dagger_{43}$

⇒ investigation:

IOPA $\bar{1}$ $\dagger_6$

⇒ other investigation — BSL FBG-PPBS [fasting, P.P

⇒ Radiographic Diagnosis

① IOPA region : mandibular left Back Region

② Teeth completely seen 35 36 37

③ Teeth partially seen 36 34

④ Anatomical Landmarks

	Radiopaque	Radiolucent
a. Dental	Enamel, Dentin	Pulp space
b. osseous	Lamina Dura	marrow space.
	cancellous Bone	mandibular canal
	Alveolar crest Bone	

⑤ most pathologic Tooth: 36

⇒ crown: an ill defined, irregular diffuse Radiolucency seen involving enamel, dentin

⇒ Roots: 2 roots with patent canals.

⇒ PDL space PDL widening seen on middle and apical 1/3rd

⇒ Lamina Dura: continious

⇒ Periapical area: an well defined round to oval radiolucency seen.

→ interdental Bone: an Horizontal radiolucency suggestive of Horizontal Bone loss.

6 (7) For other completley seen Teeth 37, 35

→ Crown: NAD

→ Root : NAD

→ PDL space: No wideing

→ Lamina Dura : NAD

→ Periapical space: NAD

→ interdental Bone: an Horizontal radiolucency suggestive of Horizontal Bone loss

7 (8) Radiographic Diagnosis

1. Periapical granuloma $\bar{c}$ 36

2. modereate periodontis

(8) Radiographic Differential

1. Periapical cyst $\bar{c}$ 36

(9) Radiographic fault

1. Clip mark.

⇒ Final Diagnosis

1. periapical granuloma $\bar{c}$ 36

2. modereate periodontis

3. Chronic generealized diffuse ginguitis with Localized periodont's $\bar{c}$ $\overline{21|13}$

⇒ Treatment Plan

1. Preliminary { metanic acid 400mg bid 3 day / Acitominophen 500mg bid 3 day

2. Non-surgical: scaling

3. Restorative { RCT $\bar{c}$ 36 / root planing and root cove reage $\bar{c}$ $\overline{21|13}$

4. maintaince

for 1st yr .... every 1 mounth .... merin

CASE HISTORY 04

Date: 19/10/22

⇒ Name: Sukram Thapa Reg no: 10794848

48, male, married, Sathe vasti Lohaegaon, street vendor, 20,000/month.

⇒ C/C: Pt c/o of pain in upper Right Back Region of Jaw and unclean Teeth. since 6 days.

⇒ HOPI:

Patient was apperently alright 6days back but began experiencing pain in upper right Back Region of Jaw the onset was gradual pain lasts for mins and aggravates on mastication. Relieves on medication 6soms DOLO pain was dull and gnawing type.

⇒ History

1. Past Dental: NRH
2. Past medical: NRH
3. Family History: NRH
4. Personal History
   1. maintaince of oral Hygiene
      a. method: Horizontal
      b. frequency: 1/day with Tooth Brush and Paste
   → Dietary habit: mixed
   → Tissue abuse History
   - Alcohol 10 yrs 2-3 times/week
   - Tobacco 8 yrs 2 times/day

⇒ Genereal examination

- Built: Endomorphic
- Gait: Slouching

Skin: NAD

Vital Sign

→ Temp: afebrile → Respiratory rate: 18 cycles/min

→ Heart rate: 82 beats/min → BP: -

5. examination of skin: NAD

B. Extra oral examination

- facial symetery: grossly symetrical

→ eyes: - , → ears: - , → Nose: - → Lips: competent

→ TMJ: NAD

→ Lymph node: Non tender and non palpable

→ muscles of mastication: NAD

→ salevary gland: NAD

C. Intra-oral examination

a. Soft tissue examination

1. Labial mucosa: NAD

2. Buccal mucosa: NAD

3. Lips: NAD, 4. Soft palate. NAD

5. Hard palate: NAD.

6. floor of mouth: NAD

7. gingival examination

Color: Physiologic Pigmentation, BOP: +ve

Absence of stippling, - consistency: oedematous

size - Normal

8. Periodontal examination: NAD

9. Tonsillar and pharyngeal area: -

b. Hard Tissue examination

1. Teeth present 18 17 16 15 14 13 12 11 21 22 23 24 25 26 27 28

48 47 46 45 44 43 42 41 31 32 33 34 35 36 37 38

- generelized attrition

- TOP +ve ⊼ 14

- occlusal facet ⊼ 1/6

- Contact point tight

- calculus: +, Plaque: ++, stain +

- occlusion

- angle class I

⇒ Detailed examination of area of chief complaint.

A. Teeth in the area of C/C : 14

B. Swelling NRF

on palpation: NRF

any other findings: -

⇒ provisional Diagnosis

1. chronic pulpitis : 14

2. occlusal caries : 16

3. chronic gingivitis

⇒ investigation : IOPA : 14

⇒ Radiographic Diagnosis

① IOPA region: maxillary Right Back Region

② Teeth completely seen: 13, 14, 15, 16

③ Teeth partially seen: 17

④ Anatomical Landmarks

	Radiopaque	Radiolucent
a. Dental	enamel, Dentin	Pulp space
b. osseous	Lamina Dura, Cancellous Bone alveolar crest Bone	max. sinus ~~mandibular~~ nasal space.

⑤ most Pathologic Tooth: 14

⇒ crown: Loss of enamel, Dentin suggestive of gross loss of crown destruction.

⇒ Roots: 1 root with no canal.

⇒ PDL space: widening in apical 1/3rd.

⇒ Lamina Dura: discontinuous

⇒ Periapical area: an diffuse irregular Radiolucency seen.

⇒ Interdental Bone: Horizontal Bone Loss

⇒ Other completely seen teeth 13, 15, 16

⇒ Crown: NAD

⇒ Roots: NAD

→ PDL space: No widing

→ Lamina Dura: discontinuous

→ Periapical area: NAD

→ Interdental bone: NAD

⇒ Radiographic diagnosis:

1. Periapical abscess c/o $\frac{4}{4}$

⇒ Radiographic differential diagnosis:

1. Periapical granuloma c/o $\frac{4}{4}$

⇒ Radiographic fault

1. Clip mark
2. Light radiograph

⇒ final Diagnosis

1. Periapical abscess c/o $\frac{4}{4}$
2. occlusal facet c/o $\frac{6}{6}$
3. Chronic generealized marginal gingivitis.

⇒ Treatment Plan

1. Preliminary Phase { metanic acid 400mg bid 3day / DOLO 625 mg bid 3day
2. Non surgical — scaling
3. Restorative
   - RCT c/o $\frac{4}{4}$
   - composite c/o $\frac{6}{6}$
4. Maintaince

for 1st yr .. every 3month .... mean

CASE HISTORY 05

Date: 28/3/23

Aseet Deshpande

Reg No: 179045

male, married, Lohaegaon, Painter, 15k, 36

C/C: Pt c/o of pain and food lodgment in lower Right Back Region of Jaw since 5 days

HOPI: Pt. c/o of pain lower left Back Region was asymptomatic 5 days Back, onsent was gradual pain on stimulus aggrevates on mastication pain is of Dull type and Relieves on cleaning to tooth.

⇒ History

1. Past Dental: NRH
2. Past medical: NRH
3. Past family: NRH
4. Personal History
   1. maintaince of oral Hygiene.
      a. method: Horizontal
      b. frequency 1/day with toothPaste.
   → Dietary habits
   → Tissue abuse History
      - alcohol since 8 yrs / 3-4 times/week.

⇒ Examination

1. Built: mesomorphic
2. Gait: NAD → Skin: NAD

→ vital sign

→ Temp: afebrail → Respiratory rate: 18 cycles/min

→ Heart rate: 73 beats/min → BP: —

→ examination of signs: NRF

3. examination of extra oral
   1. facial symetrey: Grossly Symetrical
   - eyes: - , - ear - , Nose: -
   - Lips: competent , TMJ: NAD

→ lymph node : Nontender and Non-Palpable

→ muscles of mastication:-

→ salivary gland NAD

c. intraoral examination

- Labial : NAD
- Buccal : NAD
- Lips : NAD
- Soft Palate : NAD
- Hard Palate : NAD
- Floor of mouth : NAD
- gingival examination

→ color: physiologic pigmentation → BOP: +ve

→ absence of stippling → consistency: oedematous

→ size: normal

- periodontal examination: compound pocket $\overline{C}\,\overline{6|}$

b. Hard tissue examination

1. Teeth

- Teeth Present 7 16 15 19 13 12 11 21 22 23 24 25 26 27 / 47 46 45 44 43 42 41 31 32 33 34 35 36 37
- Carious Teeth class II $\overline{C}\,\overline{45|}$, I $\overline{C}\,\overline{76|6}$ / $\overline{765|}$
- contact Point: tight
- plaque: +++, calculus: +, stain: +
- occlusion: angles Class I

⇒ Detailed examination of area of Chief compaint

A. Teeth in the area of chief complaint

a compound pocket with presence of subginval calculus and surrounding tissue is inflamed

B. swelling : NAD

4. Palpation : NAD

⇒ Provisional Diagnosis

of area of c/c : 1. localized periodontitis

$\overline{C}\,\overline{6|}$

other diagnosis:

1. Dental caries ? 76/85 | 6

⇒ investigation

IOPA ? 64

⇒ Radiographic Diagnosis

① IOPA region : mand right Back Region

② completley seen Teeth 45, 46, 47

③ Partially seen Teeth 44

④ Anatomical Landmarks

	Radiopaque	Radiolucent
a. Dental	enamel, Dentin	Pulp space
b. osseous	Lamina Dura	marrow space
	cancellous Bone	submandibular
	alveolar crest Bone	fossa

⑤ most Pathologic Tooth ? 46

→ crown: an illdefined irregular radiolucency on mesial aspect involving enamel, Dentin and encraching pulp.

→ roots : 2 roots with Patent canal

→ Lamina Dura: not continious

→ indental bone : angular defect of Bone.

→ Periapical area: small round radiolucency on Distal root on Distal aspect of 1/3rd aspect.

→ any other: –

⑥ other completley seen Teeth

⇒ 47

→ crown: an illdefined irregular radiolucency involving enamel, Dentin and pulp

→ root : 2 roots with patent canal

→ PDL space: no wideings seen

→ interdental bone: NAD

→ Peri apical area : NAD

→ Lamina dura : continuous

→ 45

→ Crown : an ill defined irregular radiolucency involving enamel + Dentin

→ root : root wit canal

→ PDL space : ND widing

→ interdental bone : NAD

→ Periapical area : NAD

→ Lamina dura : continious

(3) Radiographic Diagnosis

1. Periapical granuloma $\bar{c}\,\overline{65}$

2. Dental caries $\bar{c}\,\overline{75}$

(5) Radiographic Differential

1. Apical periodontis

(4) fault

1. clip mark

2 - fixer stain

3. Dark Radiograph

→ final Diagnosis

1. Chronic Generealized Diffuse gingivitis with localized periodontis $\bar{c}\,\overline{6}$

2 - Periapical granuloma $\bar{c}\,\overline{65}$

→ Treatment Plan.

1. Preliminary

- metanidacid
  400 mg bid 3days
- Actinaopren
  500 mg bid 3days

2. Non - surgical

- Scaling, Root planning

3. Restorative

- Pocket reduction

4. maintenance

for 1st year

every 1 month ..... mean

CASE HISTORY 06

Date : 8/3/23

Balasheb gattu khandue Reg No: 121030

male, 61, farmer, married, 10K/mounth, Lohaegoan

⇒ C/C : C/O of Pain and decayed Tooth in Lower Left Back Region of Jaw since 15days

⇒ HOPI :

while the pt was eating his tooth Broke off and was not in pain at that time, after 15days Began experincing pain which was also nocturnal pain is constant, throbbing and aching in nature also aggrevates on sweet food, cold mastication and gave no H/O of relieving factor there is NO Radiation of pain and no swelling is evident

⇒ History

1. Past Dental: NRH
2. Past medical: NRH
3. family History: NRH
4. Personal History.
   1. maintaince of oral Hygine.
      - method Tooth Brush and Paste; Horizontal
      - frequency: once a day
   2. Dietary habit : mixed
   3. Tissue abuse History.
      → Tobacco 30 yrs 5-6 times/day

⇒ Examination

1. Genereal examination

Built : mesomorphic

Gait : slouching

Skin, Hair, Nails : type III up pecea areta

→ vital sigin

→ Temp: afebril → Respiratory: 16 cycles/min

→ pulse: 88 beats/min = BP.NA

→ examination of sigins: ab

B. Extra oral examination

1. facial symetery: grossly symetrical

→ eyes:- → Ears:- → Nose:- → Lips: competent

→ TMJ: NAD → Lymph Node: Non-tender and Non-Palpable.

→ muscles of mastication:- → salivary gland:-

C. Intra-oral examination

a. soft tissue examination

- Labial NAD
- Buccal NAD
- Toungue NAD
- Lips Competent
- Soft Palate NAD
- Hard palate NAD
- floor of mouth: NAD
- gingival examination
- color: Pink - contor: Diffuse - consistcy: oedematous
- size: reduced - surface Texture: Stippling
- gingival reccesion c̄ 76 | 67 / 76 5 4 3 | 2 3 4 5 6 7
- Periodontal examination: Attachement cuss: tre

formation involvement c̄ 6 | 6

b. Hard tissue examination

1. Teeth present: 5 4 3 2 1 | 1 2 3 4 5 6 7 / 76 5 4 3 2 1 | 1 2 3 4 5 6 7

missin c̄ 1 | 1 2

grade III moblit's c̄ | 6

Top-tue: 36, 37

contact: anterior spacing contact

Stain: ++, calculus: ++

→ occlusion : angle class I

⇒ Detailed examination of area c/c

a. teeth in area of c/c : 36, 37

b. swelling : NAD

c. palpation : NAD

⇒ Provisional Diagnosis

to c/c : 1. chronic pulpitis $\bar{c}$ $\frac{}{6}$

2. apical perodtis $\bar{c}$ $\frac{}{7}$

other diagnosis :

1. false anodontia $\bar{c}$ $\frac{}{12}$

2. furcation $\bar{c}$ $\frac{6}{6}$

3. gingivitis

⇒ Investigation

IOPA $\bar{c}$ 36, 37

⇒ Radiographic Diagnosis

① IOPA region : mandibular Left Back Region

② Teeth complitely : 36, 37

③ partially seen : 35, 38

④ anatomical landmarks.

	Radioopaque	radiolucent
a. Dental	enamel, dentin	pulp space
b. osseous	cancellous bone.	
	inf. oblique ridge	sub mandib
	external oblique ridge.	fossa

⑤ most pathologic Tooth : 36

→ crown : ill detailed radiolucency enamel, dentin pulp

→ Roots : 2 roots with patent root canal

→ PDL space : complet loss of PDL st...

→ Lamina dura : Discontinuous

→ periapical area : a well defined radiolucency

① Diagnosis:

1. periapical abscess (36, 37

2. severe periodontitis (36, 37

3. furcation involvement : (37

② Differential Diagnosis

1. periapical cyst (36, 37

③ fault : 1. Clip mark.

⇒ final Diagnosis

1. periapical abscess (36, 37

2. severe periodontitis (36, 37

3. chronic generalized marginal gingivitis.

⇒ Treatment plan.

1. Preliminary { metonic acid 400mg bid 3 day
Actiominuphen 500mg bid 3 days

2. Non-surgical – scaling, root planing

3. ~~gingiv~~ Restorative : multiple root coverage.

4. maintainance

for 1st yr ... every 1 month.

CASE HISTORY 07

Date: 20/10/22

Prathiba Dongre Reg No: 1636 d

32, female, married, Pune, Housewife, graduate

⇒ C/C: C/o of food lodgment and pain in the upper Right Back region of Jaw since 2 months

⇒ HOPI

P.: Gave H/o of food lodgment, and subsequent pain the pain was localized and was on stimulus it was Dull in character and vanished after minishe gave no complain of intraoral swelling and there was no aggravating factor.

⇒ History

1. Past medical: NRH
2. Past Dental RCT ⊏ 6/6

H/o Periodontal abscess ⊏ +6

3. Family History: NRH

⇒ Examination

Built: Ectomorphic

Skin: NRH

Gait: NRH

Vital sign

→ Temp: afebrile Respiratory rate 16 cycles/min

→ Pulse rate: 68 beats/min

⇒ examination of sign NRH

→ Extra oral examination

1. Symetry: grossly Symetrical

- eyes:-, ears:-, nose-, Tmj: NAD

- Lips: Competent.

- Cyph node: non tender and non palpable

- muscle of mastication:-

c. Intra oral examination.

a. soft tissue examination

1. Labial mucosa : NRH

2. buccal mucosa : NRH

3. Tongue : NRV

4. Lips : competent

5. soft palate NRH

6. Hard palate NRH

7. Floor of mouth NRH

8. periodontal examination : NRH

b. Hard tissue examination

1. Teeth

→ Teeth Present $\bar{c}$ 7 6 9 3 2 1 | 1 2 3 4 5 6 7 8
7 5 4 3 2 1 | 1 2 3 4 5 6 7 8

- carious teeth $\bar{c}$ 7 (mesioproximal)

- can $\bar{c}$ 6, Top +ve : $\bar{c}$ 6

- contact point : Normal. calculus : ++

- ortho : angles class I

⇒ Detailed examination in area of chief complaint.

a. Teeth in area of chief complaint $\bar{c}$ 7 6 5

C/C : swelling in Rt. Buccal mucosa seen anterior to facial pillars.

b. swelling

1. Brief description.

→ on inspection.

1. Location : ant. to facial pillars, Left Buccal mucosa.

2. Number : single

3. size : 2×2 cm

4. shape : diffuse

5. skin over swelling : pinkish

6. extent : post ant to facial pillars

ant. near 15, superior and ant Borders are different.

7. color : Pink in color

8. movement on deglutation : Ab

4. movement on Tounque Depression : Ab

→ on Palpation

→ Temp: afebrile, → consitency : soft → Tendenes: in...

→ compressible.

→ space involved : Buccal space

5. any other findings.

⇒ Provisional Diagnosis

1. area of c/c : 1. Buccal space infection

2. apical periodontis c̄ 6 Top +ve

→ other diagnosis

1. Dental caries c̄ 7

2. acute marginal gingivitis

⇒ investigation

IOPA c 765

⇒ Radiographic Diagnosis

① IOPA region : maxilliary Right Back Region of Jaw

② Teeth complety seen : 1 4, 15, 16, 17

③ Teeth Partially seen : -

④ Anatomical Landmark

	Radiopaque	Radiolucent
a. dental	enamel, Dentin	Pulp
b. osseous	maxi-uberosity, alveolar Bone cancellous Bone.	floor of maxilliary sinus

⑤ most Pathological Tooth c̄ 6

→ crown : a metal prosthesis full crown

→ Root: 2 roots with patent root canal

→ PDL space: widening of PDL seen.

→ Lamina Dura: Discontinuous

→ Periapical area: floor of maxillary sinus has pneumatization

→ Interdental area: Angular Bone Loss

→ other complexes seen 14, 15, 17

→ Crown: NAD

→ root: Roots visible with patent canal.

→ PDL space: NO widening is noted.

→ Lamina dura: Continious

→ Periapical area: NO Periapical pathology.

→ Interdental: Normal Bone.

⇒ Diagnosis final

1. localized Periodontitis $\bar{c}$ 6|

⇒ Differential

⇒ Treatment plan.

1. preliminary { metonic acid 400 mg bid 3day 1—x—1
Acitominophen 500 mg bid 3day 1—x—1

2. Non-surgical
L scaling

3. Restorative
L Bone graft $\bar{c}$ 6|

4. maintaince
for 1st yr .. every 3 months .. mean

CASE HISTORY 08

Date: 17/3/22

Reg No: 89938

Santosh gaikwad

48, male, married, pune, 7972377693

⇒ C/C: Pt c/o of pain in Lower right and left Back region of Jaw since 2 to 3 days.

⇒ HOPI: Pt was apperently alright 3 days Back, Then he exprenced pain since 2 to 3 days is throbing type of pain radiating in lower left region of Jaw. Pain was continious since 2 to 3 days No aggrevating or relieving factor pain was not relieved after taking medication.

⇒ History: 1. Dental

1. Class I amalgam $\bar{c}$ —+

2. extraction $\bar{c}$ —| $\frac{6}{8}$

2. Past medical: NRH

3. family History: NRH

4. Personal History.

1. maintaince: once/day, Horizontal.

2. frequency: 1/day

b. Dietary habit

a. mixed died.

b. less spicy food.

→ Tissue abuse History: NRH

⇒ Examination

A general examination

Built NAD

Gait: NAD

Skin: NAD

Vital sign

→ Temp: afebril → Respiratory rate: Normal

→ Heart rate: 72 bpm → BP: -

→ examination of following signs: NRF

B. Extra oral examination

1. facial symetery: grossly symetrical.

→ Pyes: - , → ears: - , → Nose: - , → Lips: competent.

→ TMJ: NAD

→ Lymph Node: Submandibular lymph node is palpable.

→ muscle of mastication - Normal.

→ Salivary gland: NAD

C. Intra oral examination

a. soft tissue examination.

- Labial NAD
- Buccal NAD
- Tongue NAD
- Lips NAD
- soft palate NAD
- Hard palate NAD
- floor of mouth NAD
- gingival examination.

Color: Redish pink, BOP: +ve, stippling: Ab

consistency: odematous size - enlarged.

b. Hard tissue examination

Teeth present 7 5 4 3 2 1 | 1 2 3 4 5 7
7 5 4 3 2 1 | 1 2 3 4 5 6 7

Teeth missing: 6

Carious tooth: 6 | 8
6 | 7

filled: 7

Calculus: ++, Plaque: +

Non healing extraction socket: 8

⇒ Detailed examination of area of chief complaint:

A. Teeth in area of complaint: 8

B. swelling : NAD

On inspection

ant border: corner of mouth

post border : angle of mandible

inf border : lower border of mand

Sup border : Ala tragus line

Shape+size - oval, 1.5 inch in diameter.

On palpation - is soft and fluctuant.

lymph node: submandibular lymph node is palpable.

=> Provisional Diagnosis

1. apical perodontis c̄ 6

2. mutiple caries c̄ 8 7

3. pulptis c̄ 6

4. gingivitis

5. localized gingival enlargement c̄ 7 6 5

=> investigation IOPA c̄ 8

① Region : mandibular Left Back Region

② Teeth completely seen : 7 8

③ Partially seen c̄ 6

④ Anatomical Landmarks

	Radiopaque	Radiolucent
a. dental	enamel, dentin	pulp space
b. osseous	lamina Dura	mandibular cana
	cancellous Bone	
	inf border of canal.	

(5) most pathologic Tooth

→ Crown : gross destruction loss of enamel and dentin.

→ Roots : one root with patent canal.

→ PDL space : widing on middle and apical third

→ Lamina Dura : at Discontinous at apical 1/3rd.

→ Periapical area : seen at apex of root.

(6) Other compltley seen Teeth

→ Crown : NAD

→ Roots : 2 roots with patent canal.

→ PDL space : No widing seen

→ Lamina Dura : continious

→ periapical area : NAD

→ interdental Bone : NAD

⇒ Radiographic Diagnosis and final

Root stump ≈ +8 (chronic irreversible pupils

⇒ fault : — clip mark
— Darkening of Radiograph

⇒ Treatment Plan

1. Preliminary { metanic acid 400mg Bid 3days
{ ~~actominophen 500mg bid 3days~~

2. Non surgical — Scaling

3. Resterative : extraction ≈ +8

4. maintelince :

for 1st yr

every 3 months merin

CASE HISTORY 09.

Date : 7/10/22

Reg NO : 170342

Vijay Jagdale

54, male, married, Lohaegoan. 40k/mountn.

=> C/C : pt. c/o pain in upper and lower left Back Region of Jaw occasionally

=> HOPI : pt. was asymptomatic 15 days prior then he experienced pain in upper right Back Region of Jaw due to dislodged Restoration to lower right Back region due to food lodgment pain aggrevates on mastication and relieves on it's own pain is spontaneous and dull type of pain No H/o of Nocturnal pain

=> History

1. Past Dental History : NRH
2. Past medical History : NRH
3. family History : NRH
4. Personal History :

1. maintaince of oral Hygiene.

a. method : Tooth brush and Poyle, Horizontal

b. frequency : 1/day

2. Dietary habit

- mixed

=> Tissue abuse History

alcohol — 2/3/months.

cigarete 2-3/month

=> examination

1. General examination :

- Built : NAD
- Gait : NAD
- Skin : NAD
- Vital sigeri

→ Temp: afebrile. → Respiratory rate: 12 cycles/min

→ Heart rate: 72 beats/min → BP: →

→ Examination of signs: NAD.

B. Extra oral examination

∴ facial profile + symetry: normal.

→ eyes: - → ears: - → Nose: - → Lips: competent.

→ TMJ: NAD

→ Lymph node: non tender and non-palpable.

→ muscles of mastication: NAD → salivary gland: NAD

C. Intra oral examination

a. soft tissue examination

- Labial: NAD - Buccal: NAD

- Tongue: NAD, - Tongue: NAD

- Lips: competent, - Soft palate: NAD

- Hard palate: NAD, - floor of mouth: NAD

→ gingival examination.

Color - Pink. Recession 3 | 3 / 1 5 4 2 1 | 1 2 6

Consitency: firm, size: Reduced.

b. Hard tissue examination

∴ Teeth

7 6 5 4 3 2 1 | 1 2 3 4 5 6 7

∴ Teeth present 7 6 5 4 3 2 1 | 1 2 3 4 5 6 7

Carious teeth c̄ 7

generealized attrition.

filled c̄ 5 6

Tooth mobility II c̄ 2 | 2 6 III c̄ 1 2

Top tur c̄ 6

calculus: + plaque: ++

occlusion: angles class II malocclusion.

3. Area of chief complain:

A. Teeth in area of chief complain 5 / 8

B. swelling : NR 4

=> Provisional Diagnosis

1. Chronic generalized severe periodontitis

2. Dislodge & Restoration c̄ +36

3. gingivitis

=> Investigation c̄ +6

1. Region : mandibular left Back Region.

2. Teeth complitely c̄ +56

3. partially seen c̄ +47

4. anatomical landmarks.

	Radiopaque	radiolucent
a. Dental.	enamel, Dentin	Pulp space
b. osseous.	Lamina Dura Cancellous Bone alveolar crest Bone	PDL space

5. most pathologic tooth c̄ +6

-> Crown : Loss of enamel suggstive of attrit.

-> Root : 2 root with patent root canal

-> PDL space : No wideing

-> Periapical area : Radiolucents of root

-> Interdental : Horizontal bwn 34.35, 36.37

Horizontal Bone loss

-> Lamina Dura : not continious

6. Radiographic and final Diagnosis :

1. Periapical abscess

7. Differential 1. Periapical cyst

8. Fault { clip mark
Dark Radiograph.

final Diagnus:

1. Periapical abscess, c $+_6$

=) Treatmens plans.

1. Preliminary Phase

- Brushing Technique → Charter.

2. Non-surgical

- Scaling

3. Surgical / Restorative

1. extraction c $+_6$
2. Root coverage
3. Restoration c $+_{56}$

4. maintaince

for 1st yr ... every 3 months

... merin

An

CASE HISTORY NO 10.

Date : 05/06/23

Reg no : 128520

Ram Kumar Yadav

29, male, unmarried, Lohagaon, 15K/month

⇒ C/C: Pt c/o of pain in Lower front Region of Jaw since 2 days

⇒ HOPI: Pt was apperently alright 8 days back but began to experience pain in mandibular front Region of Jaw. Pain was Dull in character and lasts for min to hours the pain radiates to angle of mandible and at times to temple of head. Pain does not agravate but relieves on taking medication which was Paracetemol 500mg taken 2 tab since yesterday.

⇒ History

1. Past Dental: NRH
2. Past medical: NRH
3. family History: NRH
4. Personal History:

a. method: once a day with tobacco powder

b. frequency: once a day and uses finger to brush

5. Dietary Habits: mixed

6. Tissue abuse History

→ Alcohol 10 yrs 1-2/week, Tobacco 10 yrs 10-15/day.

→ Pan masala 10 yrs 15-20 times/day.

→ HIO: Anexity, nervousness.

⇒ Examination

A. General examination

→ Built: NAD. → Gait: NAD. → Skin: NAD.

→ vital sign:

→ Temperature: afebrile, → Pulse: 72 beats/min.

→ B:P: NAD, → Respiratory Rate: 18 cycles/min

→ examination of signs: NAD

B. Extra oral examination

1. facial symetery: Grossly symetrical face.

→ Eyes: NAD, → Ears: NAD, → Nose: NAD, → TMJ: NAD
→ Lymph Node: Non-Tender and non-palpable.
→ Lips: Competent, → Salivary Gland: NAD.
→ muscles of mastication: NAD.

c. Intra-oral examination.

a. Soft tissue examination
→ Labial: NAD, → Buccal: NAD, → Tounge: NAD.
→ gingiva → color: physiologic pigmentation
consistency: soft and oedematous.
→ Periodontal: recession class ε 41, 42
→ floor of mouth: NAD, → edentulous ridge: NAD
→ Pharyngeal and tonsilar region: NAD

b. Hard Tissue examination
→ Teeth present: 17 16 15 14 13 12 11 21 22 23 24 25 26 27 / 47 46 45 44 43 42 41 31 32 33 34 35 36 37
→ carious lession: – → Tooth wear: 1. abrasion ε 33, 34, 35
2. attrition ε 41/42, 31/32
→ TOP: +ve (vertical) ε 33.
occlusal facet ε 45, 46, 47, 36, 37
→ Traumatic occlusion: 16, 17, 26, 27, 25, 24
→ Calculus: +, Plaque: ++, Stain: ++
→ angles class I maloclusion
→ Teeth Not on contact During mastication.

→ Area of chief complaint ε 33 severe abrasion noticed on facial side with surrounding pulp tissue involved.
→ swelling: Absent.
→ Provisional Diagnosis
1. Apical periodontis ε 33, 2. primary Trauma from occlusion, 3. Localized periodontis ε 43, 44
4. gingivitis
→ Investigation: IOPA ε 33
→ Radiographic Diagnosis
IOPA: region: mandibular front left region

→ Teeth completely seen: 32, 33, 34, 35. Partially seen: 36,37

→ Anatomical landmarks:

	Radiopaque	Radiolucent
1. Dental	enamel, Dentin	Pulp space
	Lamina Dura	
2. Osseous	alveolar crest Bone	Marrow space

→ most Pathologic Tooth: 33
an well defined, Regular radiolucency with sharp margin

Crown: Seen involving enamel, dentin, PULP

Root: 1 root c patent canal

PDL space: widening on mesial aspect

Lamina Dura: continious

Interdental Bone: NAD.
an oval to round diffuse radiolucency

Periapical are: with Blending Borders on apex

→ other completely seen Teeth: 34
an well-defined Regular radiolucency seen involving

Crown: enamel and dentin

Root: 1 root c patent canal.

PDL space: widening evident on all aspects.

Lamina Dura: continious, → periapical area: NAD

→ any other findings: -

⇒ Radiographic Diagnosis

1. Periapical granuloma c 33, ? apical Periodontitis c 34

⇒ Radiographic Differential: Periapical cyst c 33

⇒ final Diagnosis

1. Periapical granuloma c 33.

2. Asymptomatic Apical Periodontitis c 34.

3. Primary trauma from occlusion

4. Chronic Generalized Diffuse gingivitis with localized Periodontitis c 43, 44.

⇒ Treatment plan.

1. Preliminary Phase:
   - mefanic acid 500 mg bid 3 day 1-x-1
   - Paracetemol 500 mg bid 3 day 1-x-1
   - Advice
     - sensodyne Tooth paste.
     - Charters Brushing Technique.

2. Non-surgical
   - supra-gingival scaling
   - Advice TCC
   - occlusal splint therapy.

3. Restorative
   - RCT $\bar{c}$ 33
   - GIC Restoration $\bar{c}$ 34, 35
   - Root coverage $\bar{c}$ 45, 44.

4. maintaince.

for 1st yr. after every 3 months

... merin

Radiographic interpretation ①

1. ① IOPA region: mandibular Left Back Region

2. Completely seen teeth 35 36 37

3. Partially seen teeth 34 38

4. Anatomical Landmarks

	Radiopaque	Radiolucent
a. Dental	Enamel Dentin	Pulp space nutrient canal
b. osseous	Lamina dura cancellious Bone alveolar crest Bone	submandibular fossa

5. most Pathologic Tooth 36
→ an ill defined radiolucency on mesial aspect on enamel crown dentin and approaching pulp.

→ root: 2 roots with 2 Patent canal

→ PDL space: widening seen on apical 1/3rd of mesial root

→ Lamina Dura: Discontinious

→ interdental Bone: Horizontal bone loss

→ Periapical area: a well defined circular radiolucency with corticated border on mesial aspect

→ any other finding -

6. other complitey seen teeth : 35, 37

→ crown : NAD

→ root : NAD

→ PDL space : widing on mesial root of 37

→ Lamina Dura : continious

→ interdental Bone : Horizontal bone loss

→ Periapical area : NAD

→ any other finding : -

7. Radiographic Diagnosis :
   1. Periapical Granuloma 2 + 6
   2. mild Periodontis 2 + 6

8. Radiographic differential Diagnosis :
   1. Periapical cyst 2 + 6

9. Radiographic faults
   1. Cap mark

Radiographic interpretation (2)

1. Region : mandibular Left Back

2. completely seen teeth 35 36 37

3. Partially seen teeth 34

4. Anatomical landmarks

	Radiopaque	Radiolucent
a. dental	Enamel dentin	Pulp space
b. osseous	external oblique inferior oblique	Submandibular fossa

5. most Pathologic Tooth 36
an ill-defined irregular radiolucency involving
→ crown enamel, dentin and pulp

→ root : 2 roots with Patent root canal

→ PDL space : No widening

→ Lamina Dura : Discontinuous on mesial aspect of cervical 1/3rd

→ Periapical area : NAD

→ interdental bone : NAD

→ any other finding -

6. other completey seen teeth. 35, 37

→ crown : NAD

→ ROOT : NAD

→ PDL space : NAD

→ Lamina dura : continious

→ Periapical area : NAD

→ interdental bone : an Horizontal radiolucency suggestive of Horizontal Bone loss

→ any other finding. -

7. Radiographic Diagnosis :

1. Periapical abscess c tb

8. Radiographic Differential Diagnosis :

1. periapical cyst c tb

2. ellis class III Tooth fracture.

9. Radiographic fault.

1. clip mark

2 - Ligh radiograph - over fixation

3. fixer stain

Radiographic interpretation (3)

1. region maxillary Left Back

2. completely seen teeth 27 26 25 24

3. Partially seen teeth 28

4. Anatomical Land marks

	radiopaque	radiolucent
a. Dental	Enamel	Pulp space
	Dentin	
b. osseous	Lamina Dura	marrow space
	cancellous Bone	
	alveolar Bone	

5. most Pathologic tooth: 26

→ Crown: an ill defined irregular radiolucecy involving Enamel, Dentin

→ root: 2 roots with 2 canals filled with obturating material

→ PDL space: No widening

→ Lamina Dura: Discontinious on mesiobuccal root

→ periapical area: an well defined radiolucecy which is round to oval and approx 1-5 seen on mesial

→ interdental bone: angular Bone Loss

→ any other finding: an infective foci on distal root has occured.

6. other complitley seen teeth 27 25 24

→ crown : NAD

→ root : NAD

→ PDL space : No wideing

→ Lamina dura : continious

→ periapical area NAD

→ interdental bone NAD

→ any other finding : -

7. Radiographic Diagnus: 1

1. Periapical granuloma ε 26

8. Radiographic differential

1. Periapical cyst ε 26

9. Radiographic fault

1. Clip mark.

2- fixer stain

3. finger mark — improper handling

Ans

Radiographic interpretation (04)

1. region : mandibular right Back

2. compitley seen teeth : 46, 47, 48

3. other Particaly seen teeth : -

4. Anatomical Land mark :

	Radiopaque	Radiolucent
a. Dental	enamel	Pulp space
	Dentin	
b. osseous	Lamina Dura	marrow space
	cancellous Bone	mandibular canal
	alveolar crest	mandibular tuber

5. most Pathologic Tooth 47

→ crown : an ill defined, irregular seen in enamel and cont.

→ Root : 2 roots with Patent canal and obturating mat.

→ PDL space : widening evident on apical 1/3rd of Distal root.

→ Lamina Dura : discontinious on apical 1/3rd of root

→ periapical area : well defined small round to oval radiolucency with hyperostotic borders

→ interdental bone : Horizontal Bone loss

→ any other finding -

6. other completely seen teeth 46, 48

→ crown: NAD

→ Root: NAD

→ PDL Space: NAD

→ Lamina Dura: continuous

→ periapical area NAD

→ interdental bone: NAD

→ any other finding -

7. Radiographic Diagnosis

1. periapical granuloma ē 46

8. Radiographic Differential Diagnosis:

1. periapical cyst ē 46

9. Radiographic fault:

1. clip mark

2. Light radiograph — insufficient Developer immersion.

3. over fixed.



Radiographic interpretation (05)

1. region: mandibular Right Back

2. Completely seen teeth 45, 46, 47

3. Partially seen teeth 44

4. Anatomical Landmarks

	Radiopaque	Radiolucent
a. Dental	Enamel	Pulp space
	Dentin	
b. osseous	Lamina Dura	marrow space
	Cancellous Bone	
	Alveolar crest Bone	

5. most Pathologic Tooth: 46

→ Crown: an ill-defined, irregular radiolucency in mesial aspect of crown suggestive of fluoride bomb

→ Root: 2 roots with 1 patent root canal

→ PDL space: WNL dining evident

→ Lamina Dura: Discontinious

→ Periapical area: ill-defined irregular Diffuse radiolucency on mesial root of 46

→ interdental bone: Horizontal Bone Loss

→ any other finding -

6. other completely seen teeth. 45, 47

→ crown : NAD

→ Root : NAD

→ PDL space : NAD

→ Lamina dura : continious

→ periapical area : NAD

→ interdental bone : NAD

→ any other finding : -

7. Radiographic Diagnosis

1. periapical abscess ~ 46

8. Radiographic Differential

1. apical periodontitis ~ 46
2. ~~Periapical cyst~~ ~ 46
3. perio lession ~ 46

9. Radiographic fault :

1. Cl. P mark
2. Dark Radiograph
   - Use developer imers^n
   - Use Dev conc^n
   - use fixe soloon^n conc^n
   - Imers^n time.

Ab

Radiographic Interpretation (06)

1. region: mandibular left Back

2. completley seen teeth: 36, 37, 35

3. Particully seen teeth. 34

4. Anatomical Landmarks

	Radiopaque	Radiolucent
a. Dental	Enamel	Pulp Space
	Dentin	
b. osseous	Lamina Dura	marrow Space
	cancellous Bone	
	alveolar Bone	

5. most Pathologic Tooth 36
an well defined radiolucecy seen involving
→ crown: enamel, dentin and encroaching pulp

→ Root: 2 roots with 2 Patent canal

→ PDL space: widing on mesial root apex

→ Lamina Dura: Discontinuous

→ Periapical area: an light radiopacity on the mesial root suggestive of an inflamtory reaction of Bo

→ interdental bone: Horizontal Bone Loss

→ any other finding

6. other compilies seen teeth 37 35

→ crown : NAD

→ Root : NAD

→ PDL space : No widening seen

→ Lamina Dura : continious

→ Periapical area : NAD

→ interdental bone : Horizontal Bone loss

→ any other finding : -

7. Radiographic Diagnosis

.. condensing osteitis ε 36

8. Radiographic Differential Diagnosis :

1. Inflamatory lession
2. endo - perio lession
3. Resolved apical periodontitis

9. Radiographic fault

1. clip mark

Radiographic interpretation (07)

1. region : mandibular Right Back

2. Completely seen teeth 46 47 45

3. partially seen Teeth 44

4. Anatomical Land marks

	Radiopaque	Radiolucent
a. dental	enamel dentin	pulp space
b. osseous.	Lamina dura cancellous Bone.	-

5. most pathological Tooth 46
an irregular ill-defined radiolucency involving
→ crown: enamel, dentin, encroaching pulp

→ Root : 2 roots with 2 root canals
widening in furcation and mesial 1/3rd

→ PDL space : of mesial root.

→ Lamina dura : continuous

→ periapical area : dilated marrow spaces

→ interdental bone : Horizontal Bone loss

→ any other finding : —

6. other complitley seen teeth 47 43

-> crown : NAD

-> Root : NAD

-> PDL space : No widening

-> Lamina Dura : continious

-> Periapical area : NAD

-> interdental bone : Horizontal Bone Loss

-> any other finding : Dilated marrow spaces

7. Radiographic Diagnosis

1. apical periodontitis ε 46

8. Radiographic Differential

-

9. Radiographic fault

clip mark

Radiographic interpretation (68)

1. region: maxillary Right Back

2. completely seen teeth 18 17 16 15

3. partially seen teeth. 14

4. Anatomical Landmarks

	Radiopaque	Radiolucent
a. Dental	Enamel Dentin	pulp space
b. osseous	max. sinus floor Lamina Dura	max. sinus marrow space

5. Most pathologic Tooth 16

→ crown: an ill defined, irregular radiolucency involving enamel, dentin, pulp.

→ Root: 2 roots with 1 patent canal

→ PDL space: widening seen

→ Lamina Dura: Discontinuous

→ periapical area: an ill defined irregular radiolucency seen

→ interdental bone: NAD

→ any other finding: Pneumatization of floor of maxillary sinus floor.

6. other completley seen teeth

→ crown : 2 is an ill defined radiolucy involving enamel dentin and pulp.

→ ROOT : NAD

→ PDL SPACE : widening @ 1 5

→ lamina dura : NAD i.e continuous

→ periapical area : NAD

→ interdental bone : NAD

→ any other finding -

7. Radiographic Diagnosis

1. periapical abscess @ 1 6
2. apical periodontitis @ 1 5

8 Radiographic differential

1. periapical granuloma @ 1 6

9. Radiographic fault

1. clip mark
2. Light radiograph

Ab

Radiographic interpretation of

1. region : maxillary front Regin

2. most complitley seen Teeth 21 22 23 24

3. Particuly seen Teeth "

4. Anatomical Landmarks

	Radiopaque	Radiolucent
a. Dental	Enamel	Pulp space
	Dentin	
		marrow space
b. osseous	nasal septum	nasal fossa
	inf. turbinates	
	ant. nasal spine	

5 most Pathologic Tooth 24

→ Crown : Loss of enamel, dentin sugestive of gross crown destriction

→ Root : 2 root piece remain

→ PDL space : widening seen

→ Lamina Dura : Discontinuous

→ Periapical area : a small radiolucency visible on distal side

→ interdental bone : NAD

→ any other finding : -

6. other compitley seen Teeth. 21 22 23

→ Crown : NAD

→ Root : NAD

→ PDL space : No widening

→ Lamina Dura : continious

→ periapical area : NAD

→ interdental bone : NAD

→ any other finding :-

7. Radiographic Diagnosis

1. Periapical abscess (intial stage) ε 24

8. Radiographic Differential

1. periapica granuloma ε 24

2. apical periodontis ε 24

9. Radiographic fault

1. clip mark

2. Developer stain

Radiographic interpretation 10

1. region : maxillary front left

2 completely seen teeth : 11 12 13 14

3 Partially seen Teeth 15

4 Anatomical Landmarks

	radiopaque	radiolucent
a. dental	enamel dentin	pulp space
b. osseous	ant. nasal spine floor of nasal fossa	max. sinus incisive fossa PDL space

5. most Pathologic Tooth 13

→ Crown : an radiolucey seen in crown region
sugestive of complete loss of crown

→ Root : 1 root piece remain

→ PDL space : widening seen

→ Lamina Dura : not continious

→ periapical area : a white line near to mesio aspect of root

→ interdental bone : Horizontal Bone Loss

→ any other finding : -

6. Other completley seen teeth 11 12 14

→ crown : NAD

→ Root : NAD

→ PDL Space : wideing

→ Lamina Dura : not continuous

→ Periapical area : NAD

→ interdental bone : Horizontal Bone loss

→ any other finding : -

7 Radiographic Diagnosis

1. healed apical periodontis ⌐ 13
2. periapical abscess ⌐ 13 (initial stage)
3. ~~generalized periodontis~~

8 Radiographic Differential

1. apical Perodontis ⌐ 13

9. Radiographic fault

1. clip mark
2. developer stain

Radiographic interpretation (1)

1. region : mandibular lower right

2 compitley seen teeth 46 47 48

3. Partially seen teeth -

4. Anatomical land marks

	Radiopaque	Radiolucer
a. Dental	enamel	Pulp spac
	Dentin	
b. osseous	external oblique	Marrow
	Cuncellous Bone	Spale

5. most pathologic Tooth 46

→ crown : a full metal crown till CEJ

→ Root : 2 roots with obturating material

→ PDL space : widening

→ Lamina Dura : not continious

→ Periapical area : a diffuse ill defined radiolucency extending from the furcation.

→ interdental bone : Horizontal bone loss

→ any other finding

6. other compitley seen 47, 48

→ crown : Filling ∈ 47 absent crown ∈ 48

→ Root : 48 has curved root

→ PDL space : widening

→ Lamina Dura : Discontinuous

→ Periapical area : NAD

→ Interdental bone : horizontal Bone Loss

→ any other finding : -

7 Radiographic Diagnosis

1. Periapical abscess ∈ 46
2. apical periodontis

8. Radiographic Differential

-

9. Radiographic fault

1. clip mark
2. Loss in sharpness

Radiographic interpretation (12)

1. region : mandibular left Back

2 Compitley seen Teeth : 36 37 35

3. Partially seen Teeth 34

4. Anatomical Landmarks

	Radiopaque	Radiolucent
a. Dental	Enamel	Pulp Space
	Dentin	
b. osseous	Lamina dura	marrow space
	cancellous Bone	
	alveolar crest Bone	

5. most Pathological Tooth 36

→ crown : comple loss of crown

→ Root : Root piece visible

→ PDL space : widening

→ Lamina dura : Discontinuous

→ Periapical area : an ill defined difuse radiolucency seen

→ interdental Bone : angular Bone Loss evident

→ any other finding -

6. other Compitley seen Teeth 35 , 37

→ crown : NAD

→ Root : NAD

→ PDL space : widining seen

→ Lamina Dura : continious

→ periapical area : NAD

→ interdental Bone : Horizontal Bone loss

→ any other finding -

7. Radiographic Diagnosis

1. Periapical abscess c̄ 36
2. generealized periodontis .

8. Radiographic Differential

1. periapical granuloma

9. Radiographic fault

1. clip mark
2. scratch mark
3. low contrast

Radiographic interpretation (13)

1. region : mandibular left Back

2. completely seen teeth 37 38

3. Partially seen teeth. 36

4. Anatomical landmarks

	Radiopaque	Radiolucent
a. Dental	enamel dentin	Pulp space
b. Osseous	Lamina Dura cancellous Bone alveolar crest	nutrient canal Submandibular fossa int. alveolar canal

5. most Pathologic Tooth 37
an ill defined irregular radiolucency on the distal aspect

→ crown at cervical 1/3rd involving enamel and dentin

→ Root : 2 roots with 1 Patent canal

→ PDL space : widening

→ Lamina Dura : continious

→ Periapical area : NAD

→ interdental bone : Horizontal bone loss

→ any other finding : Dilated marrow space.

6. other completely seen teeth 38

→ crown : radiopaque filling done

→ ROOT : 2 roots with 2 patent canals

→ PDL space : No widening

→ Lamina dura : continious

→ periapical area : Horizontal Bone Loss

→ interdental bone : NAD

→ any other finding -

7 Radiographic Diagnosis

1. Proximal caries [37]
2. mild periodontitis

8. Radiographic Differential

-

9. Radiographic fault

1. clip marks
2. Light radiograph.

Radiographic interpretation

1. region : mandibular R9ght Back

2 completley seen teeth 44 45 47

3 Particuly seen teeth 43

4 Anatomical Landmarks

	Radiopaque	Radiolucent
a. Dental	Enamel	Pulp space
	Dentin	
b. osseous	cancellous Bone	marrow space
	Lamina Dura	
	Alveolar crest Bone	

5. most pathologic Tooth 45

→ crown: an ill defined irregular radiolucey seen on mesical aspect middle 3rd to apical 1/3rd.

→ Root : 1 root with a patent canal

→ PDL space: widening seen on apical 1/3rd of the

→ Lamina Dura : not continuity

→ Periapical area: an well defined radiolucey visible on the apex

→ interdental bone: Horizontal bone loss

→ any other finding : -

6. Other complikey seen teeth 94 47

→ crown : NAD

→ Root : NAD

→ PDL space : NO widening

→ Lamina dura : continuous

→ Periapical area : NO abnormality detected.

→ interdental bone : Horizontal Bone loss

→ any other findings: Pathologic mesial tilt of 47

7. Radiographic Diagnosis

1. apical Periodontitis 7 95

8. Radiographic Differential

-

9. Radiographic fault

1. clip mark

Radiographic interpretation - 15

1. region : maxillary left BAC

2 completley seen teeth 24 25 26 27

3 portialy seen teeth 28 23

4. Anatomical Landmarks

	Radiopaque	Radiolucent
a. dental	enamel dentin	pulp spac
b. osseous	septa in max sinus	max sinus inverted Y line

5. most pathologic Tooth 25

→ crown : an ill defined irregular radiolucy seen involving enamel, dentin and pulp

→ Root : 1 root with patent canal

→ PDL space : widening seen at cervical, middle and apical 1/3rd.

→ Lamina Dura : continious

→ periapical area : well defined corticated radiolucency which is about 1.5 cm seen near apical 1/3rd.

→ interdental bone : WNL

→ any other finding -

6. other completely seen teeth

=> 24

→ crown : NAD

→ Root : NAD

→ PDL space : No widening

→ Lamina dura : NAD

→ periapical area : NAD

→ interdental bone : NAD

→ any other findings : -

=> 26

→ crown : NAD

→ Root : NAD

→ PDL space : NAD

→ periapical area : NAD

→ interdental bone : NAD

→ any other finding

→ 27

→ Crown: NAD

→ Root: NAD

→ PDL space: NAD

→ Lamina Dura: NAD

→ Interdental Bone: NAD

→ Periapical area: NAD

→ any other finding -

⇒ Radiographic Diagnosis:

1. Periapical granuloma (25)

⇒ Differential Diagnosis:

1. Periapical cyst (25)

→ Radiographic fault

1. Clip mark

2. fixer stain

CASE HISTORY

Department of Pedodontics

D Y PATIL GROUP

D Y PATIL DENTAL SCHOOL

Dr. D. Y. Patil Knowledge City, Charholi (BK) Via- Lohegaon, Pune- 412105

JOURNAL OF PAEDODONTICS AND PREVENTIVE DENTISTRY

Name : Omkar. N. Shelke

Roll No.: 64 BATCH: H

YEAR : 2023

MUHS Seat No.: 49615

EXAMINEER'S SIGNATURE :

D Y PATIL GROUP

D Y PATIL DENTAL SCHOOL

Dr. D. Y. Patil Knowledge City, Charholi (BK) Via- Lohegaon, Pune- 412105

JOURNAL OF PAEDODONTICS AND PREVENTIVE DENTISTRY

CERTIFICATE

This is to certify that Omkar. N. Shelke

Roll No. 64 *has Attended and Completed all The Practical Recorded in PAEDODONTICS AND PREVENTIVE DENTISTRY in the Year* _____

Name : Omkar. N. Shelke

MUHS University Seat No.: 49615

Examination Centre : _____

Date of Practical Examination : _____

Signature of the Head
Of the Department

Signatures of the Staff

INDEX

Sr. No	Date	Title of the Topic	Signature of the Staff
1.	7/4/23	Difference between primary & permanent teeth	
2.	7/4/23	Tooth no. system	
3.	7/4/23	Aims & objectives of pediatric dentistry	
4.	8/4/23	Development of occlusion	
5.	8/4/23	GIC	
6.	8/4/23	fluorides	
7.	9/4/23	pit & fissure sealant	
8.	9/4/23	Dental indices	
9.	9/4/23	local anesthesia	
10.	9/4/23	Pediatric & Exodontia.	
11.			
12.			

EXAMINATION FORM

Name of the Patient : Shruti Panchal

Age : 5yrs Gender : Female OPD No. 937122

Address : Pride world city, charholi, Pune

Chief Complaint: Patient complains of decayed tooth in upper left back region of jaw since 5-6 days

No. of teeth Present : 20

(i) FDI Notation :

55 54 53 52 51 61 62 63 64 65

85 84 83 82 81 71 72 73 74 75

(ii) Zsigmondy & Palmer Notation:

E D C B A	A B C D E
E D C B A	A B C D E

Dental Age: 2-2·5yrs

Occlusion :	Left	Right
Primary molar relation	Mesial step	Mesial step
Permanent molar relation		
Canine relation	class-I	class I
Anterior relation	overjet overbite - normal	overjet overbite - normal

Other(S)

Permanent Dentition

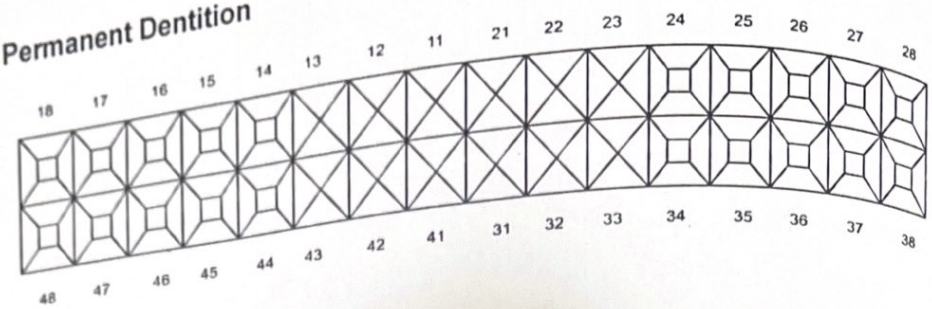

Primary Dentition

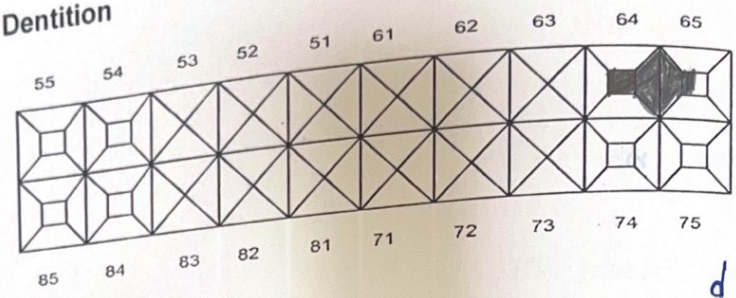

dmft
d-2
m-0
f-1
total-3

dmfs
d-2+2
m-0
f-1
total-5

Caries

Filling / Restoration

Missing

Erupting

Root Piece

Fractured

Provisional Diagnosis : 1) Mesioocclusal caries $\bar{c}$ 65
2) Distoocclusal caries $\bar{c}$ 64
3) Restoration done $\bar{c}$ 84

Vsmuti
27/5/22

CASE HISTORY

Date : 15/11/22

Name of the Student : omkar.r.shelke OPD No.

Teacher: Dr. Smruti Malam Case History No. 4

PATIENT'S INFORMATION :

1) Name : Kartik Raikar
2) Nick Name : Munna
3) Date of Birth : 08/08/19
4) Age: 4years (4/12)
5) Gender : Male
6) Address : lohegaon.
7) Telephone No : 8805862160
8) Mother tongue : Marathi
9) Name of the accompanying person :

PARENTS	FATHER	MOTHER
a) Name	Sujit Raikar	Renuka Raikar
b) Occupation	marketing	Homemaker
c) Education	B.com	12th
d) Income	30000/month	

10) Paediatrician/ Family Physician's Name & Contact No.

CHIEF COMPLAINT : [Origin/ Onset/Duration/Progress/Nature of Plan/ H/o Present illness/ Aggravating Factors/ Relieving Factors]

c/c : patient c/o pain in upper left back region of jaw since 1 month
H/o pt - spontaneous pain, dull, continuous pain & lasts for minutes. Aggregavates on mastication.
H/o Medication : Amox syrup 3 times for 3 days.
Metronidazole (200 mg) - 2 times. 3 days.

2) **HISTORY :**

i) **FAMILY HISTORY**

1) **Past Medical History :** no relevant history

- Premature / Full term - full term ✓
- Birth Weight : 3.4 half kg
- H/o Hypoxia/ Cyanosis/Jaundice : no relevant history
- H/o Medication : no relevant history
- H/o allergy : no relevant history
- H/o illness and hospitalization no relevant history
- Immunization Status : Incomplete (complete upto 6 months ago)

2) **Past dental History :** no relevant history

- Dental Visits :
- Dental Treatment

- Behavior of Child during Dental Visit + positive

- Past Dental experience : –

II) INFANT FEEDING HISTORY :

1) H/O Breast feeding

- Duration : for 3 years

- Frequency : 4.5 times a day

- Night feeding : positive history

2) H/O Bottle feeding no relevant history

- Duration Frequency ;

- Night Feeding:

- Contents of Bottle:

3) Use of Pacifiers : no relevant history

4) H/O Weaning : 7 month of age

III) DIET :

1) Meals per day : 3 - 4 times a day

2) Diet Includes: Dal, Chawal, Roti, Sabji

3) Type and frequency of snaks: chocolate - 5 times, Tea - 3 times, chips - 1 time

4) Balanced Diet:

5) Any other :

food score
chapati - 6x3 = 18
Bhaji - 6x3 = 18
Dal - 6x2 = 12
Rice - 6x2 = 12
Tea - 6x2 = 12
chocolate - 10x3 = 30
chips - 10x2 = 20
= 136

dental health score = 136 - 70 = 66 ⇓ Patient education

Sugar score = tea = 5x2 = 10
chocolate = 10x5 = 50
chips = 1x10 = 70

IV) ORAL HYGIENE MAINTENANCE

1) Whether child brushes himself/herself : ✓

2) Since when: 1 to 1½ years

3) How many times: once

4) Which tooth paste (fluoridated/Non fluoridated) colgate - fluoridated

5) How often does he/she change his/ her tooth brush: after 7 to 8 months

V) Trauma to teeth and supporting tissues :

1) When :

2) Where: Injury to lips (3-4 times)

3) How: falling on ground during playing

4) If fracture, (?)

VI) ORAL HABITS (Duration/Frequency/ Intensity)

1) Tongue Thrusting :

2) Thumb sucking:

3) Lip/Nail Biting

4) Mouth Breathing:

5) Bruxism:

6) Any other ;

} no relevant history

VII) BEHAVIORAL RATING SCALE :

1) Frankl's Behavior Rating Scale: positive (+)

3) EXAMINATION :

1) GENERAL

- Height : 3 feet
- Weight: 12lb kg
- Somatoype:
- Gait:
- Skin :
- Nails:
- Hair:

no Abnormality detected

2) HEAD, NECK & FACE

- Symmetry : Bilaterally symmetrical
- Profile : straight
- T M J: no clicking no deviation
- Lips: incompetent
- Lymph nodes : Palpable /non Palpable ✓ Tender/Non Tender ✓

INTRA- ORAL

1) Oral hygiene status :
2) Deposits:
   - Hard : +
   - Soft +

3) Stains :

- Intrinsic
- Extrinsic

4) Soft tissue Examinations ;

- Lips / Labial Mucosa
- Buccal Mucosa :
- Floor of Mouth :
- Tongue :
- Palate:
- Tonsils :
- Gingiva:

no abnormality detected

5) Hard Tissue Examination :

A) **No. of teeth Present ;** 20

A) Primary : 20

B) Permanent:

B) Dentition :

C) Teeth present (FDI System)

55 54 53 52 51 61 62 63 64 65

85 84 83 82 81 71 72 73 74 75

D) Dental Age :

5 years

E) Occlusion :

1) Primary Dentition : Mesial step

2) Mixed / Permanent Dentition

- Overjet : normal
- Overbite : decreased
- Deepbite :
- Crossbite: } no relevant history
- Any other Findings :

F) **Teeth restored (Material used)**

G) **Dental Caries :** proximal caries ⊏ 51, 61
smooth surface caries ⊏ 52, 62
occlusal caries ⊏ 54, 55, 75, 84, 85

H) **Fractured tooth :** distoproximal caries ⊏ 64
no relevant history

Classification :

I) **Developmental defects :** no relevant history

J) **Discoloration of tooth :** no relevant history

K) **Mobility :** no relevant history

L) **Pulp :**

A) Not exposed

B) Exposed ⊏ 64

M) **Missing teeth :**

DMFT/ Deft : d = 10 = 10
e = 0
f = 0

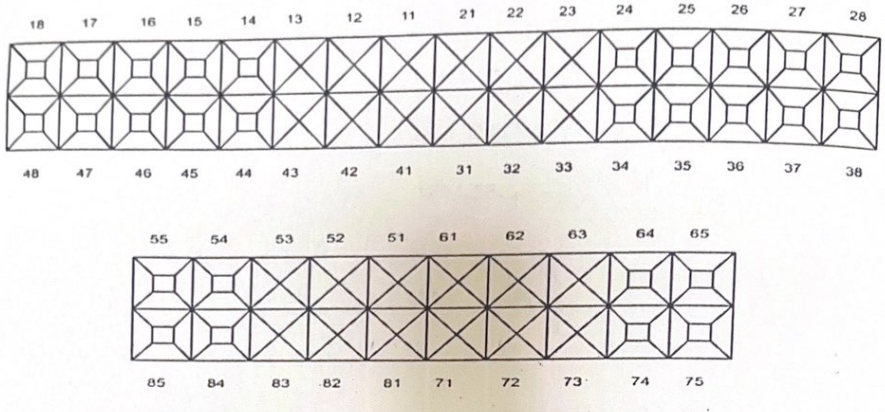

■ Caries

⬆ Erupting

● Filling / Restoration

+ Root Piece

Missing

Fractured

AREA OF CHIEF COMPLANT : $\bar{c}$ 6 4
Deep occlusal caries

PROVISIONAL DIAGONSIS : Dentoalveolar abscess $\bar{c}$ 6 4
secondary to deep distoocclusal caries $\bar{c}$ 6 4

INVESTIGATION IOPA $\bar{c}$ 6 4

- Radiograph (IOPA Bitewing OPG)
- Vitality
- Model Analysis :

- Photographs :

- Routine blood examinations (Hb, BT, CT)

- Any other

Type of radiograph - OVG
Tooth completely seen - 64 65
Tooth partially seen - 63
succedaneous tooth - 24, 25, 26
Tooth of interest - 64

RADIOGRAPHIC INTERPRETATION

FINAL DIAGNOSIS : Dentoalveolar abscess c̄ 64 secondary to deep disto-occlusal caries

TREATMENT PLAN :

1) Emergency Treatment : Access opening c̄ 64
Amox syrup - 3days
Ibuprofen (200mg) BID = 3days

2) Planned Treatment :

a) Preparatory & Preventive Phases:

1) Oral Prophylaxis : ultrasonic scaling

2) Topical Fluoride Application :

3) Pit & fissure sealant :

4) Dietary Counseling : diet modification & pt education

b) Restorative Phase/ Endodontic Treatment ;
carries excavation & restoration
7 51, 61, 52, 62, 54, 55, 75, 84, 85

c) Surgical Phase :
pulpectomy 64
stainless steel crown 64

d) Orthodontic Phase :

e) Recall : follow up after 7 days

Signature of Teacher

10/4/23

CASE HISTORY

Department of Public Health Dentistry

D Y PATIL DENTAL SCHOOL

Department of Public Health Dentistry

This is to certify that Intern named Mr/Ms Ajmera krishna. ,

Roll No 1 has satisfactorily completed the work of this department as per the DCI guidelines.

I hereby give him/her the certification of internship completion from this department.

Date: 19/12/22

PROFESSOR & HEAD
Dept. of Public Health Dentistry
D Y Patil Dental School
D Y Patil Knowledge City
Charoli (Bk), Via Lohegaon, Pune - 412105

Head of the Department

Department of Public Health Dentistry

ASSIGNED CLINICAL EXERCISES AND OUTREACH PROGRAM DURING INTERNSHIP

1. Organizing Dental Camp	5
2. Participation in Dental Camp	10
3. Satellite Center Charholi PHC	5
4. Rajiv Gandhi Hospital Posting	5
5. Comphrensive Dental Care in Integrated Clinic	10

OUTREACH ACTIVITIES

No of camps organised:

Sr No	Date	Venue
1.	19/11/22.	Sant Tukaram Maharaj Mandir.
2.	23/11/22.	Trinity Skool Dighi.
3.	24/11/22.	Smart kids primary school.
4.	25/11/22	Akanksha Academy Lohegaon.
5.		
6.		
7.		
8.		
9.		
10.		

No of Camps Attended:

Sr No	Date	Venue
1.	19/11/22.	Sant Tukaram Maharaj Mandir.
2.	23/11/22.	Trinity Skool Dighi.
3.	24/11/22.	Smart kids primary school.
4.	25/11/22.	Akansha Academy Lohegaon.
5.	30/11/22.	Santulan Bhavan Kharadi.
6.	1/12/22	Fun & fun preschool.
7.	3/12/22.	SS English Medium School.
8.		
9.		
10.		
11.		
12.		
13.		
14.		
15.		

Comphrensive Dental Care in Integrated Clinic

Sl No	Date	OPD No	Name of Patient	Treatment	Sign
1.	3/01/22	80192	Manisha Sonawane	Scaling	
2.	3/01/22	80193	Bapurao Harinwale	Scaling	
3.	5/01/22	80194	Monika Devkar	Extraction	
4.	5/01/22	80195	Adarsh Devkar	Extraction	
5.	5/01/22	80196	Janhavi kholam	Scaling	
6.	10/01/22	80197	Sushmakholam	Extraction	
7.	10/01/22	80198	Prakash Palkar	Oral prophylaxis	
8.	10/01/22	80263	Rutuja Pol	Scaling	
9.	10/01/22	80264	Nitin Jangale	Extraction	
10.	11/01/22	80265	Reshma Ingale	Scaling	
11.	11/01/22	80266	Ashis Dhiwar	Oral prophylaxis	
12.	11/01/22	80267	Sujit kalokhi	Extraction	
13.	13/01/22	80268	Jyoti Varma	Toothbrush demo	
14.	13/01/22	80269	Dinesh Sonar	Scaling	
15.	14/01/22	80270	Nikhil Gomase	Scaling	

D Y PATIL DENTAL SCHOOL

Department of Public Health Dentistry

This is to certify that Intern named Mr/Ms Ajrekar Iftisam.,

Roll No 2 has satisfactorily completed the work of this department as per the DCI guidelines.

I hereby give him/her the certification of internship completion from this department.

Date: 19/12/22

PROFESSOR & HEAD
Dept. of Public Health Dentistry
D Y Patil Dental School
D Y Patil Knowledge City
Charoli (Bk), Via Lohegaon, Pune - 412105

Head of the Department

Department of Public Health Dentistry

ASSIGNED CLINICAL EXERCISES AND OUTREACH PROGRAM DURING INTERNSHIP

1.	Organizing Dental Camp	5
2.	Participation in Dental Camp	10
3.	Satellite Center Charholi PHC	5
4.	Rajiv Gandhi Hospital Posting	5
5.	Comphrensive Dental Care in Integrated Clinic	10

OUTREACH ACTIVITIES

No of camps organised:

Sr No	Date	Venue
1.	25/11/22.	Akansha Academy Lohegaon.
2.	30/11/22	Santulan Bhavan Khandi
3.	1/12/22.	Fun & fun Preschool.
4.		
5.		
6.		
7.		
8.		
9.		
10.		

No of Camps Attended:

Sr No	Date	Venue
1.	19/11/22.	Sant Tukaram Maharaj Mandir.
2.	23/11/22.	Trinity school Dighi.
3.	24/11/22.	Smart kids Primary School.
4.	25/11/22.	Akansha Academy Lohegaon.
5.	30/11/22.	Santulan Bhavan Khandi.
6.	5/12/22.	Eyes school.
7.	6/12/22.	PHC Wagholi.
8.	9/12/22.	Trinity School Dighi.
9.		
10.		
11.		
12.		
13.		
14.		
15.		

Satellite Centre Postings

PHC Charholi

Sr No	Date	Signature
1.	2/10/22	
2.	7/10/22	
3.	11/10/22	
4.	16/10/22	
5.	19/10/22	
6.	26/10/22	
7.	1/11/22	
8.	5/11/22	

Late Shri Rajeev Gandhi Hospital, Yerwada

Sr No	Date	Signature
1.	7/11/22.	
2.	12/11/22.	
3.	16/11/22	
4.	21/11/22	
5.	27/11/22	
6.	2/12/22	
7.	5/12/22	
8.	7/12/22	
9.	11/12/22.	

Comphrensive Dental Care in Integrated Clinic

Sl No	Date	OPD No	Name of Patient	Treatment	Sign
1.	11/11/22	80335	Pankaj Kanlar	Scaling	
2.	11/11/22	80336	Malika Detroja	Extraction	
3.	11/11/22	80337	Pradeep Rave	Scaling	
4.	11/11/22	80338	Prachi Sharma	Oral prophylaxis	
5.	11/11/22	80339	Vasant Bhorat	scaling	
6.	11/11/22	80340	Alakanshi Mehta	Extraction	
7.	11/11/22	80341	Ashish Goswami	Scaling	
8.	12/11/22	80414	Pankaj Kadam	scaling	
9.	12/11/22	80415	Sanita Detoli	Extraction	
10.	12/11/22	80416	Sohan Gaikwad	Scaling	
11.					
12.					
13.					
14.					
15.					

D Y PATIL DENTAL SCHOOL

Department of Public Health Dentistry

This is to certify that Intern named Mr/Ms Agarkar Mrutyuja Vinod,

Roll No 1 has satisfactorily completed the work of this department as per the DCI guidelines.

I hereby give him/her the certification of internship completion from this department.

Date: 09/10/23

PROFESSOR & HEAD
Dept. of Public Health Dentistry
D Y Patil Dental School
D Y Patil Knowledge City
Charoli (Bk), Via Lohegaon, Pune - 412105

Head of the Department

Department of Public Health Dentistry

ASSIGNED CLINICAL EXERCISES AND OUTREACH PROGRAM DURING INTERNSHIP

1. Organizing Dental Camp	5
2. Participation in Dental Camp	10
3. Satellite Center Charholi PHC	5
4. Rajiv Gandhi Hospital Posting	5
5. Comphrensive Dental Care in Integrated Clinic	10

OUTREACH ACTIVITIES

No of camps organised:

Sr No	Date	Venue
1.	28/7/23	Ikids Paradise Preschool
2.	17/8/23	Time kids Dhanori
3.	5/9/23	Shining Star School.
4.		
5.		
6.		
7.		
8.		
9.		
10.		

No of Camps Attended:

Sr No	Date	Venue
1.	28/7/23	Ikids Paradise Preschool
2.	3/8/23	MMIT Lohegaon
3.	4/8/23	Bumble bee preprimary school
4.	7/8/23	~~Imma~~ Immanuel School
5.	17/8/23	Time kids Dhanori
6.	22/8/23	Tapas foundation
7.	24/8/23	Kidzenia Dhanori
8.	31/8/23	DY Patil International School
9.	2/9/23	Little sprout preschool
10.	5/9/23	Shinining star school
11.		
12.		
13.		
14.		
15.		

Satellite Centre Postings

PHC Charholi

Sr No	Date	Signature
1.	30/7/23	
2.	5/8/23	
3.	12/8/23	
4.	21/8/23	
5.	25/8/23	
6.	31/8/23	
7.	4/9/23	
8.	6/9/23	

Late Shri Rajeev Gandhi Hospital, Yerwada

Sr No	Date	Signature
1.	7/9/23	
2.	15/9/23	
3.	18/9/23	
4.	21/9/23	
5.	23/9/23	
6.	25/9/23	
7.	27/9/23	
8.	4/10/23	
9.	6/10/23	

Comphrensive Dental Care in Integrated Clinic

Sl No	Date	OPD No	Name of Patient	Treatment	Sign
1.	25/7/23	113315	Manihar Waseem	Scaling	
2.	28/7/23	131449	Siddhesh Patil	Extraction.	
3.	27/7/23	113321	Sumita Devi	Extraction	
4.	28/7/23	131450	Prajwal Patil	Extraction.	
5.	29/7/23	113268	Sunny Dalvi	Oral Prophylaxis	
6.	31/7/23	131452	Durgesh Sapkal	Scaling	
7.	1/8/23	113271	Omkar Dhotre	Extraction	
8.	2/8/23	131466	Sumedh Lokhande	Scaling	
9.	3/8/23	113273	Akash Sumindre.	Scaling	
10.	4/8/23	131471	Pranay Shinde	Scaling.	
11.	5/8/23	113275	Sachin Jadhav	Extraction	
12.	6/8/23	131415	Tanvi Jadhav	Scaling	
13.	7/8/23	133527	Kiran Devkar	Scaling	
14.	8/8/23	133528	Amruta Pawar	Extraction	
15.	9/8/23	133529	Sanjay Patil	Oral Prophylaxis	

D Y PATIL DENTAL SCHOOL

Department of Public Health Dentistry

This is to certify that Intern named Mr/Ms Aglave Sakshi Suresh,

Roll No 2 has satisfactorily completed the work of this department as per the DCI guidelines.

I hereby give him/her the certification of internship completion from this department.

Date: 9/10/23

PROFESSOR & HEAD
Dept. of Public Health Dentistry
D Y Patil Dental School
D Y Patil Knowledge City
Charoli (Bk), Via Lohegaon, Pune - 412105

Head of the Department

Department of Public Health Dentistry

ASSIGNED CLINICAL EXERCISES AND OUTREACH PROGRAM DURING INTERNSHIP

1.	Organizing Dental Camp	5
2.	Participation in Dental Camp	10
3.	Satellite Center Charholi PHC	5
4.	Rajiv Gandhi Hospital Posting	5
5.	Comphrensive Dental Care in Integrated Clinic	10

OUTREACH ACTIVITIES

No of camps organised:

Sr No	Date	Venue
1.	3/8/23	MMIT
2.	4/8/23	Bumble Bee preprimary School
3.	7/8/23	Immanual school.
4.		
5.		
6.		
7.		
8.		
9.		
10.		

No of Camps Attended:

Sr No	Date	Venue
1.	28/7/23	Ikids Paradise Preschool
2.	3/8/23	MMIT Lohegaon
3.	4/8/23	Bumble Bee preprimary school
4.	7/8/23	Immanual School
5.	17/8/23	Time kids Dhanori
6.	22/8/23	Tapas foundation.
7.	24/8/23	Kidzenia Dhanori
8.	31/8/23	DY Patil International School
9.	2/9/23	Little sprout preschool
10.	5/9/23	Shinning star School.
11.		
12.		
13.		
14.		
15.		

Satellite Centre Postings

PHC Charholi

Sr No	Date	Signature
1.	30/7/23	
2.	5/8/23	
3.	12/8/23	
4.	21/8/23	
5.	25/8/23	
6.	31/8/23	
7.	4/9/23	
8.	6/9/23	

Late Shri Rajeev Gandhi Hospital, Yerwada

Sr No	Date	Signature
1.	7/9/23	
2.	15/9/23	
3.	18/9/23	
4.	21/9/23	
5.	23/9/23	
6.	25/9/23	
7.	27/9/23	
8.	4/10/23	
9.	6/10/23	

Comphrensive Dental Care in Integrated Clinic

Sl No	Date	OPD No	Name of Patient	Treatment	Sign
1.	25/7/23	133530	Chandama Naik	Scaling	
2.	26/7/23	133531	Anuj Kawale	Extraction	
3.	27/7/23	133532	Anjali Shelke	Extraction	
4.	28/7/23	133533	Amar Barwase	Extraction	
5.	29/7/23	133534	Pooja Gawane.	Extraction	
6.	31/7/23	133535	Dhanashree Mane	Scaling	
7.	1/8/23	133536	Reshma Bhagat.	Extraction	
8.	2/8/23	130075	Tejal Kadam	Scaling	
9.	3/8/23	127376	Bharat Shahane.	Scaling	
10.	4/8/23	130085	Dipak rathod	Scaling	
11.	5/8/23	127372	Shivaji Biradar.	Scaling	
12.	6/8/23	130093	Kavita Patil	Scaling	
13.	7/8/23	127364	Sunil Pawar	Extraction	
14.	8/8/23	130097	Sangita Pawar	Extraction	
15.	9/8/23	127364	Anand Shendge.	Scaling	

Satellite Centre Postings

PHC Charholi

Sr No	Date	Signature
1.	2/10/22	
2.	4/10/22.	
3.	6/10/22	
4.	7/10/22	
5.	8/10/22.	
6.	9/10/22	
7.	12/10/22.	
8.	19/10/22	

Late Shri Rajeev Gandhi Hospital, Yerwada

Sr No	Date	Signature
1.	21/10/22	
2.	24/10/22	
3.	28/10/22.	
4.	29/10/22	
5.	2/11/22	
6.	3/11/22.	
7.	7/11/22.	
8.	9/11/22	
9.	11/11/22	

CASE HISTORY

Department of Periodontics

Department of Periodontology

D Y PATIL GROUP

D Y PATIL DENTAL SCHOOL

Dr. D. Y. Patil Knowledge City, Charholi (BK), Via - Lohegaon, Pune - 412 105

Department of Periodontology
and
Oral Implantology

Year: 2018 - 19

Name: Shubhangi Barode. Subhash

Roll No.: 02

Univ. Examination No.: 27900

Date 23/12/19 **Signature of In-charge** **Signature of HOD**

Demonstrations

III B.D.S.

Sr no.	Date.	Topic.	Staff signature.
1.	04/4/19	Case History & Incision. Phase I	
2.	5/4/19	Revision Instruments	
3.	5/4/19	Case History Instruments discussion	
4.	9/4/19	Demo - scaling	
5.	10/4/19	Periodontal Pocket and Mobility	

III B.D.S.

Sr no.	Date.	Topic.	Staff signature.
1.	11-4-19	Calculus, Recession & Furcation	
2.	12-4-19	Trauma from occlusion. Etiological factors.	
3.	15-4-19	Diagnostic, Prognosis & Treatment	
4.	16-4-19	Indices discussion	
5.			

WORK DONE

Sr. No.	Date.	O.P.D. No.	Nature of Work Done.	Grade.	Staff Signature
01.	23-8-18	23110	supergingival scaling		
02.	3/4/19	32048	Supergingival scaling		
03.	8/4/19	32177	supergingival scaling		
04.	8/4/19	32233	supragingival scaling		

Sr. No.	Date.	O.P.D. No.	Nature of Work Done.	Grade.	Staff Signature
05.	10/4/19	31414	supragingival scaling		
06	11/4/19	32370	gross scaling		
07	15/4/19	31404	gross scaling		
08	16/4/19	32524	supragingival scaling		

Sr. No.	Date.	O.P.D. No.	Nature of Work Done.	Grade.	Staff Signature

CASE HISTORY.

S. No : 01 **Year :** 2019

Patients' Name : Mala singh. **O.P.D No. :** 27898

Age : 42 **Date :** 4/10/19

Sex: female **Occupation:** Home maker

Address : Lonegaon Pune. **Income :** 20,000 1 month.

Chief Complaint : Pt. complains of pain in upper left back Region since 4-5 months.

History of present Illness : Patient feels pain while chewing ~~food~~ since 4-5 months aggravates on any kind of food chewing

Past Dental History : NRH

Past Medical History : NRH

Family History : NRH

Personal History : WRH

Oral Hygiene Habits : Tooth Brush + Tooth Paste

Other Habits : –

Extra Oral Examination :

Symmetry of Face :

Lips : Competent

Lymph Nodes : No on palpable

T . M. Joint : No clicking & popping sound

Intra Oral Examination :

Halitosis : present

Oral Mucous Membrane : No Ab. seen

Tongue : No Abnormality seen

Palate : Normal

Gingiva :

	Region	Colour	Contour	Consistency	Surface Texture	Size	Bleeding On Probing	Exudation
MAXILLARY	Anterior	Coral pink	Scalloped	Firm & Resilient	Stippling Absent	Normal	Absent	–
	Posterior	Coral pink	Scalloped	Firm & Resilient	Stippling Absent	Normal	Absent	–
MANDIBULAR	Anterior	Coral pink	Scalloped	Firm & Resilient	Stippling Ab.	Normal	Absent	–
	Posterior	Coral pink	Scalloped	Firm & Resilient	Stippling Ab.	Normal	Absent	–

Mucogingival Problems : Shallow vestibule.

Frenal Attachment :

Upper :

Lower :

Width of Attached Gingiva : **Adequate/ Inadequate**

Tension Test:

Periodontal Pockets :

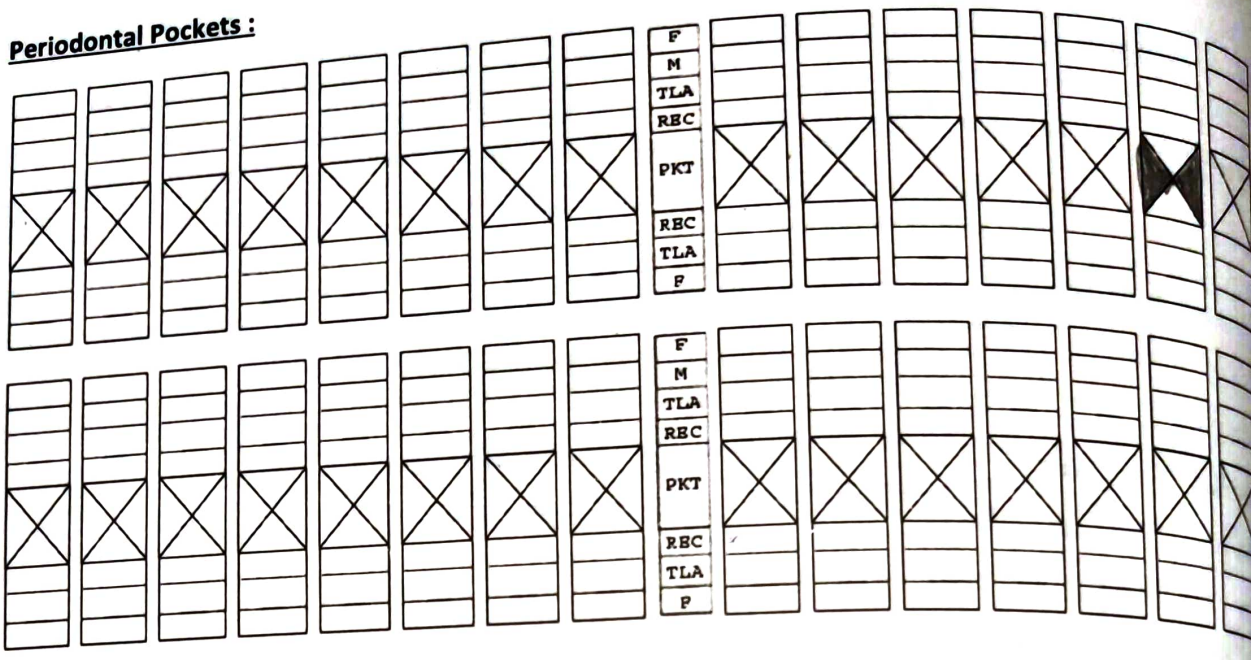

F-Furcation involvement,

M-Mobility,

TLA- Total loss of attachment,

REC-Recession,

PKT-Pocket

Examination of Teeth :

Teeth Present : 21

7 6 5 4 3 2 1 | 1 2 3 4 5 6 7
7 6 5 4 3 2 1 | 1 2 3 4 5 6 7

Wasting Diseases : **Attrition** / **Abrasion** / **Erosion**

(Present) (Absent) (Absent)

Carious Teeth : E T

Restored Teeth: Absent

Faulty Restoration : Absent.

Pathologic Migration: Absent

Drifiting : Absent

Proximal Contacts : Absent

Food Impaction : +/-

Occlusion : Normal.

Fremitus Test :

Teeth Deposits : Plaque **Plaque :** + **Calculus :** + **Stains :** +

Hypersensitivity : –

Etiological Factors : –

Local : –

Primary : –

Secondary : –

Systemic: –

Investigations : ~~Radio~~ IOPA C +7

Laboratory : -

Radiographic :

Diagnosis: Localised Periodontitis C +6

Prognosis : ~~generalised gingivitis~~

Overall: generalized gingivitis

Individual: Localised Periodontitis C +5

Treatment Plan:

Preliminary / Emergency Treatment:

Phase I : scaling & polishing
↓
supra & sub gingival

Phase II : Surgical

Phase III : Restoration

Phase IV : maintenance

INDICES

1. Simplified Oral Hygiene Index (Greene & Vermillion 1964):

DI-S



CI-S



OHIS Score Per Person:

Oral Hygiene Status : Good / Fair / Poor

2. Plaque Index (Turesky-Gilmore Glickman, 1970)



Plaque Score Per Person :

3. Gingival Index (Loe and Silness 1963)

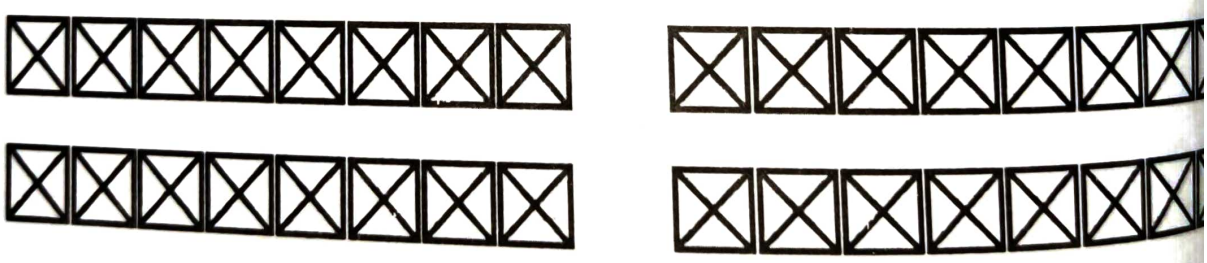

Gingival Score Per Person :

CASE HISTORY.

S. No : 02

Year : 2018

Patients' Name : mandar zite.

O.P.D No. : 231110

Age : 24

Date : 28/08/2018

Sex: male

Occupation: work in office

Address : wadgaon sheri, Pune.

Income : 20,000/- m.

Chief Complaint : Patients complains of unclear teeth.

History of present Illness : Patient complains of unclear teeth since 2 months.

Past Dental History : No Relevent History

Past Medical History : NORH

Family History : NORH

Personal History : NRH

Oral Hygiene Habits : tooth Brush & tooth Paste.

Other Habits : -

Extra Oral Examination :

Symmetry of Face : symmetrical.

Lips : compitent

Lymph Nodes : Non palpable

T. M. Joint : No clicking & Doping found

Intra Oral Examination :

Halitosis : Not Present

Oral Mucous Membrane : Normal

Tongue : Normal

Palate : Normal

Gingiva :

	Region	Colour	Contour	Consistency	Surface Texture	Size	Bleeding On Probing	Exudation
MAXILLARY	Anterior	Coral Pink	Scalloped	Firm & Resilient	Stippled	Normal	Absent	–
	Posterior	Coral Pink	Scalloped	Firm & Resilient	Stippled	Normal	Absent	–
MANDIBULAR	Anterior	Coral pink	Scalloped	Firm & Resilient	Stippled	Normal	Absent	–
	Posterior	Coral Pink	Scalloped	Firm & Resilient	Stippled	Normal	Absent	–

Mucogingival Problems : Absent.

Frenal Attachment :

Upper :

Lower :

Width of Attached Gingiva : **Adequate/ Inadequate**

Tension Test:

Periodontal Pockets :

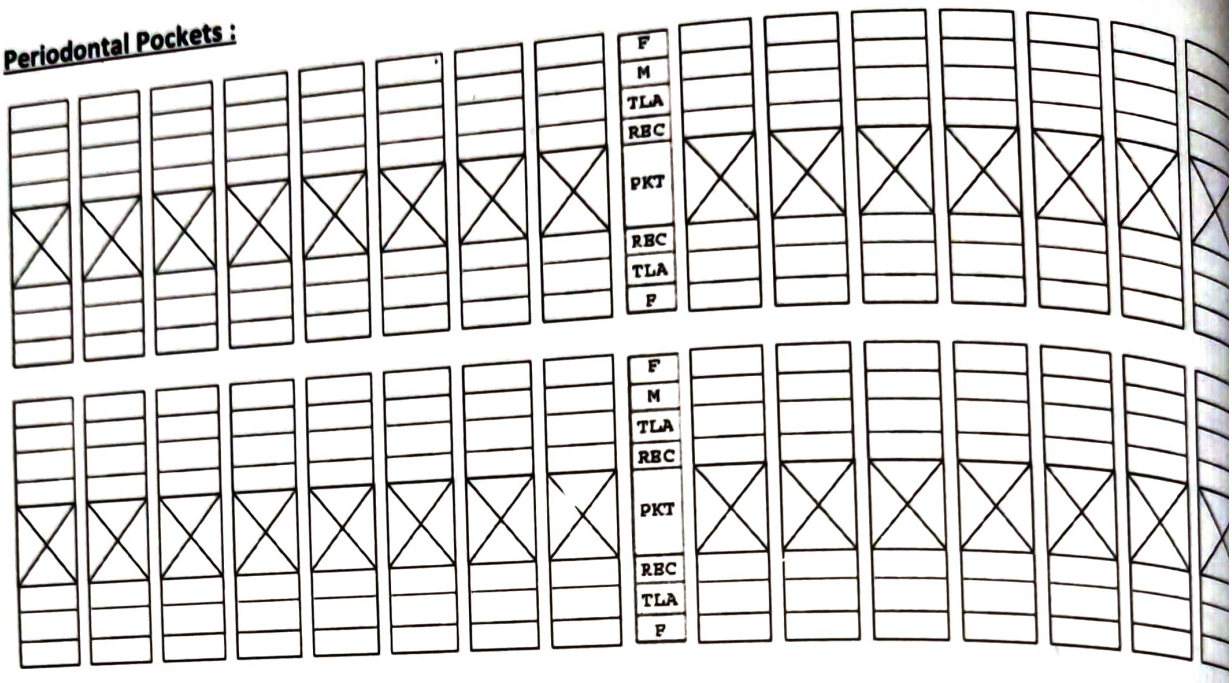

F-Furcation involvement,

M-Mobility,

TLA- Total loss of attachment,

REC-Recession,

PKT-Pocket

Examination of Teeth :

Teeth Present : 8 7 6 5 4 3 2 1 | 1 2 3 4 5 6 7 8

8 7 6 5 4 3 2 1 | 1 2 3 4 5 6 7 8

Wasting Diseases : **Attrition** / **Abrasion** / **Erosion**

(Absent) (Absent) (Absent)

Carious Teeth : +

Restored Teeth: –

Faulty Restoration : –

Pathologic Migration: –

Drifiting : –

Proximal Contacts : –

Food Impaction : –

Occlusion : Normal

Fremitus Test : –

Teeth Deposits : **Plaque :** + **Calculus :** + + **Stains :** +

Hypersensitivity : Absent

Etiological Factors : –

Local : –

Primary :

–

Secondary : –

Systemic: –

Investigations : Radiographic

Laboratory : –

Radiographic : IOPA $\bar{C}$ $\overline{\beta 6}$

Diagnosis: generalised gingivitis.

Prognosis :

Overall: generalised gingivitis.

Individual:

Treatment Plan:

Preliminary / Emergency Treatment:

Phase I : Scaling & Polishing

Phase II : Surgical

Phase III : Restorative

Phase IV : Maintenance

INDICES

1. Simplified Oral Hygiene Index (Greene & Vermillion 1964):

DI-S



CI-S



OHIS Score Per Person:

Oral Hygiene Status : Good / Fair / Poor

2. Plaque Index (Turesky-Gilmore Glickman, 1970)

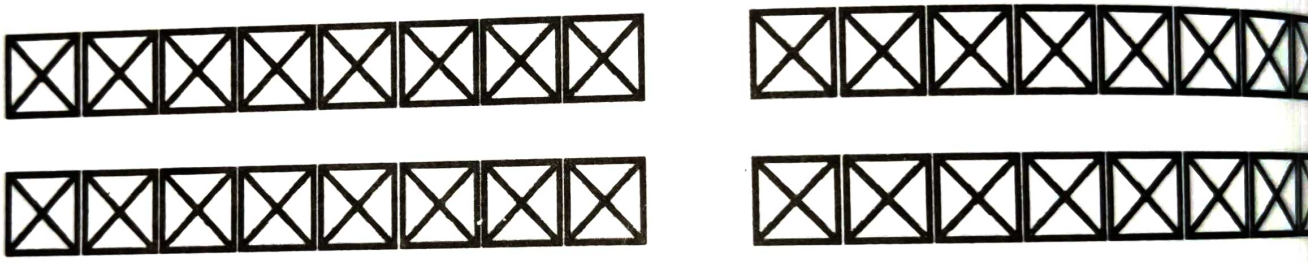

Plaque Score Per Person :

3. Gingival Index (Loe and Silness 1963)

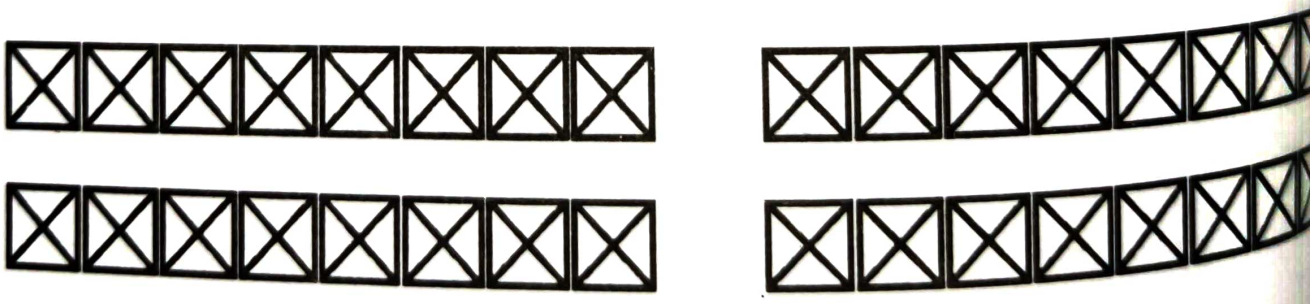

Gingival Score Per Person :

CASE HISTORY.

S. No :

Year :

Patients' Name : Pavan Pendharkar.

O.P.D No. :

Age : 25

Date :

Sex: M.

Occupation: Job. bzness

Address : Kharadi, Pune.

Income : 15-20 Lack /yr.

Chief Complaint : Pt. want to get his teeth clean

History of present Illness : Since 2 yrs.
tobacco Placing in left Buccal Area since 2yrs
Habi Left from ~~2 yrs~~ months.

Past Dental History : Extraction done before 1 yrs $\bar{c}$ 8

Past Medical History : —

Family History :

Personal History :

Oral Hygiene Habits : colgate & Brushing once in morning, by Horizontal method. in 2 months.

Other Habits : mixed food, medium spicy.

Extra Oral Examination :

Symmetry of Face : equal / normal

Lips : stained / dark Brownish.

Lymph Nodes : Not palpable.

T. M. Joint : No Ab.

Intra Oral Examination :

Halitosis : Not present

Oral Mucous Membrane :

Tongue : Normal

Palate : No.

Gingiva :

	Region	Colour	Contour	Consistency	Surface Texture	Size	Bleeding On Probing	Exudation
MAXILLARY	Anterior	Red. Pink	Scallop	Firm & Resilient	Stippled	Normal without any attraction	Ab	Δ -ve
	Posterior							
MANDIBULAR	Anterior							
	Posterior							

Mucogingival Problems : Ab.

Frenal Attachment :

Upper : gingival

Lower : gingival.

Width of Attached Gingiva : **Adequate/ Inadequate** Adequate

Tension Test: - ve

Periodontal Pockets :

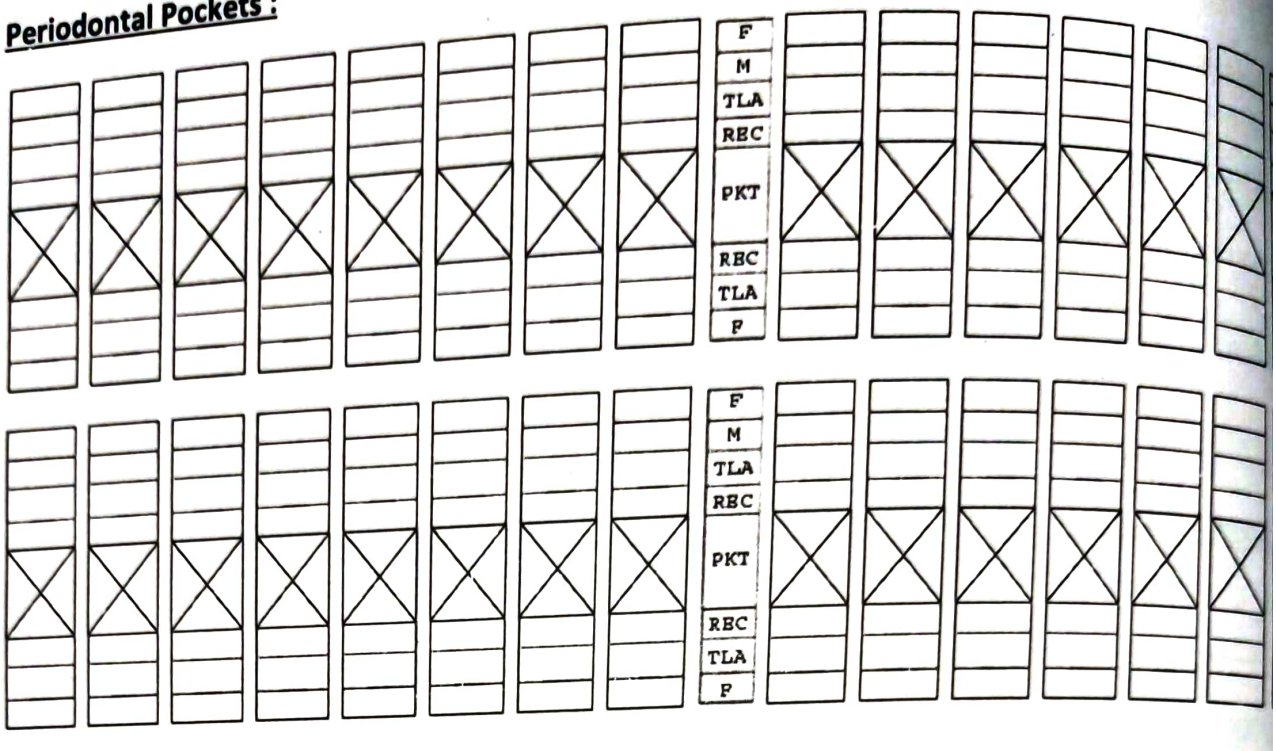

F-Furcation involvement,

M-Mobility,

TLA- Total loss of attachment,

REC-Recession,

PKT-Pocket

Examination of Teeth : 8 7 6 5 4 3 2 1 | 1 2 3 5 6 7 8 / 7 6 5 4 3 2 1 | 1 2 3 4 5 6 7 8

Teeth Present :

Wasting Diseases : **Attrition** / **Abrasion** / **Erosion**

(✓) ( ) ( )

Carious Teeth : 8 | 8 7 / 7 8

Restored Teeth:

Faulty Restoration :

Pathologic Migration:

Drifiting : Present with 13

Proximal Contacts : ~~Loose~~ tight

Food Impaction : 36, 37

Occlusion : ~~Angle~~ class I malocclusion

Fremitus Test :

Teeth Deposits : **Plaque :** ~~+++~~ **Calculus :** + + **Stains :** + +

Hypersensitivity : -

Etiological Factors : -

Local :

Primary :

Secondary :

Systemic:

Investigations :

Laboratory :

Radiographic :

Diagnosis: chronic Marginal gingivitis

Prognosis :

Overall:

Individual:

Treatment Plan:

Preliminary / Emergency Treatment:

Phase I : Adv. scaling.

Phase II :

Phase III :

Phase IV :

INDICES

1. Simplified Oral Hygiene Index (Greene & Vermillion 1964):

DI-S

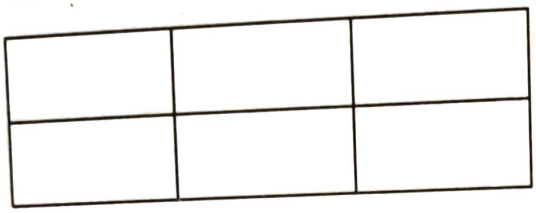

CI-S

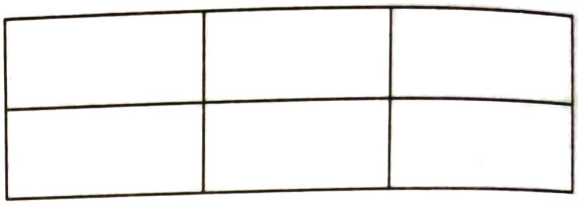

OHIS Score Per Person:

Oral Hygiene Status : Good / Fair / Poor

2. Plaque Index (Turesky-Gilmore Glickman, 1970)



Plaque Score Per Person :

3. Gingival Index (Loe and Silness 1963)



Gingival Score Per Person :

periodontal instruments are designed are specific purpose such as removing calculus, planing root surface, curettage the gingiva & removing descarded tissue.

Classification

• On the basis of purpose they serve:

i) periodontal probes These are used to locate measure & mark pocket as well as determine their course on individual tooth surface

ii) Explores :- They are used to locate calculus & deposite and caries.

iii) scaling and root planing & curretage instrument they are used for removal of biofilm and root of the tooth, removal of altered cementum from the subligual roots surface debriment of soft tissue lining the pocket.

scaling and curretage instruments are following.

- Sickle scalers :- These are heavy instruments used remove subingival calculus.

- Curretes :- used for subgingival scaling, root planing & removal of soft tissue lining the pocket

- Hoes, chiesel and files :- Removal of tenecious.

- ultrasonic & sonic instruments used for scaling and cleaning tooth surface in altering the soft tissue wall of POCKET.

iv) Periodontal endoscope :- They are used to visualize deeply into subgingival POCKET & furcation allowing the detection of deposits.

v) Scaling & Polishing instrument :- Such as rubber cups & Brushes, Dental tapes are used to clean & polish tooth surface

- Parts of Instruments :-

1) Handle
2) Shank
3) working end



1) mouth mirror.

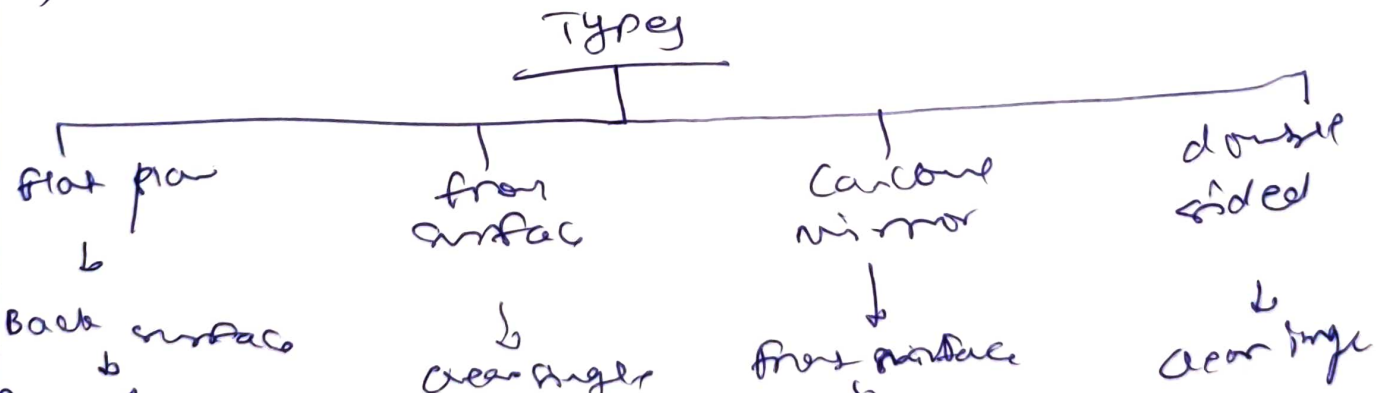

2) Periodontal Probe :-

Periodontal probes are used to measure the depth of pocket & determine the configuration

- A typical probe is tapered, rodlike instrument calibrated in millimeters, with blunt rounded tip.
- Shaft should be aligned with long axis of tooth.

i) Williams probe -

Marking : 1, 2, 3, 5, 7, 8, 9, 10.

(4 & 6 are missing which minimize to optical during reading)

ii) WHO probe

Marking - 3.5, 5.5, 8.5 & 11.5

iii) Marquis color coded probe -

Marking : 3-6, 9-12.

iv) Nicholson 'O' Probe.

Marking = 3-6, 9-12.

Easy to read, marking should be differentiated between color codes.

4) Naber's probe :-



Williams probe



WHO Probe

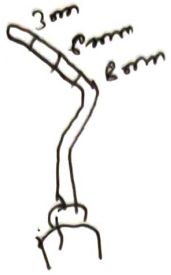

Michigan O-probe



Naber's Probe

5) Explorer :- Dental explorer are diagnostic instruments used to conduct tactile experiments. It has sharp point at the end, explorer tip is 1-2 mm in length.

Uses - It is used to locate subgingival depths and caries to check smoothened and root surface after root planing

Types :- # 23.

Accepted book :- Explorer are diagnostic instruments used to conduct a tactile experimentation - It has sharp point at the end. Explorer tip is 1-2 mm in length

Caries : To check contoured and root surfaces after root planing.

Types - : 17 :- Commonly used explorer tip of explorer is at 90° with lower shaft

Adv - when inserted.

iv) # 3 ~ ~~(pigtail &~~
(pigtail & Go whorn)

The name of is because of shape of the shank of the instrument that is used to

Incompleted
23/12/19

D Y PATIL GROUP

D Y PATIL DENTAL SCHOOL

Dr. D. Y. Patil Knowledge City, Charholi (BK) Via - Lohegaon, Pune - 412105

DEPARTMENT OF PERIODONTOLOGY

AND

ORAL IMPLANTOLOGY

Year : 2021 - 22

Name : Gargi Rajendra Ghosalkar

Roll No. : 23

Univ. Examination No.: 43130

Signature of In -Charge

12/8/22

Signature of HOD

Do's and Don'ts for Students

1. Students should be punctual to clinics and works sincerely.
2. Each student should wear a clean apron and strictly follow- Formal dress code with Name plate.
3. No Slippers or sports shoes allowed **formal shoesto be worn compulsory.**
4. Equipments in clinics should be **handled** with utmost care. Students shall be fined for any damage/loss.
5. No page from journal should be torn, nor any remark to be rubbed off.
6. Use of **Sterilized instruments,** Face **Mask, Head camp, Hand gloves** and **eye protector** is mandatory while working on a patient.
7. **Mobile Phones** are strictly not allowed in clinics. Any misbehavior in this regard shall lead to the mobiles being confiscated.
8. Students should pay attention to their personal hygiene, such as- nails should be trimmed and without nail polish.
9. Each student should carry the **Journal** daily for clinics.
10. Each student should make **Entries** in the work done and appointment register every day after treatment.
11. Students must take **signature** on case history and work done on the same day of treatment.
12. Students cannot leave the Department without permission.
13. Students shall be given demonstration of various procedures during the course of the postings, hence attendance is considered of utmost importance. Students who remain absent have to justify their absence appropriately.

List of Instruments for III B.D.S. and IV B.D.S. Clinics

1. Mouth Mask
2. Surgical Gloves
3. Head Cap
4. Eye Protector
5. Drape
6. Mouth Mirror
7. Explorer
8. Straight Probe
9. WillamsGranduated Periodontal Probe.
10. Tweezer
11. Cotton Holder
12. Cotton Receiver
13. Disposable Glasses
14. Dappen Dish – 02
15. Kidney Tray – 01
16. SupragingivalScalers (Set of 8)
17. SubgingivalScalers (Set of 7)
18. Universal Curettes 2R/2L,4R/4L
19. Contra- angle MicromotorHandpiece
20. Polishing Cup -02
21. Polishing Brush -02
22. Green Cloth (3) and Instrument Pouch (2)
23. Oral Hygiene Demostration Kit

    (Tooth Brush

    Floss

    Small Face Mirror

    Study Cast- Upper & Lower)

(Note :-All the above instruments are mandatory during posting and should be in working condition.)

Demonstrations

III B.D.S.

Sr. No.	Date	Topic	Staff Signature
1.	4/4/21	Case history - I, II	
2.	5/4/21	Instruments	
3.	7/4/21	Mechanical plaque control	
4.	8/4/21	Principles of instrumentation	
5.			

III B.D.S.

Sr. No.	Date	Topic	Staff Signature
1.	17/5/21	Chemical plaque control	
2.	18/5/21	Case history II	
3.	10/5/21	Instrument discussion	
4.	21/5/21	Scaling demo.	
5.	29/5/21	Polishing demo.	

Sr. No.	Date	Topic	Staff Signature
1.	12/12/22	Instruments revision	
2.	14/12/22	Principles of instrumentation (revision)	
3.	13/12/22	Mechanical plaque control (II)	
4.	17/12/22	Chemical plaque control II	
5.	20/12/22	Case history revision	

IV B.D.S.

Sr. No.	Date	Topic	Staff Signature
1.	09/4/22	Case history revision Page 1	
2.	4/4/22	Case history discussion Page 2.3 (Revision)	
3.	9/4/22	Instruments (revision)	
4.	10/4/22	Case history (Page 6)	
5.	11/5/22	~~Case history~~ Chemical Plaque control	

WORK DONE

Sr.No	Date	O.P.D.No	Name of work Done	Grade	Staff Signature
1.	11/8/21	73827	Saroj Joshi - Full mouth hand scaling		
2.	12/8/21	74114	Jitendra Mundhe Full mouth hand scaling		
3.	14/12/21	82685	Shalaka Dixit Full mouth hand scaling		
4.	15/12/21	79928	Aditi Mane Full mouth hand scaling		

Sr.No	Date	O.P.D.No	Name of work Done	Grade	Staff Signature
5.	16/12/21	81223	Kishor Nalawade Full mouth hand scaling		
6.	6/4/22	91234	Sangita More Full mouth hand scaling		
7.	8/4/22	92345	Abhishek Shinde Full mouth hand scaling		
8.	9/4/22	89921	Akash Mogale Full mouth hand scaling		

Sr.No	Date	O.P.D.No	Name of work Done	Grade	Staff Signature
9.	16/12/21	83157	Babita Kelkar Mandibular anteriors		
10.	23/12/21	83435	Vishwas Devkar Full mouth scaling		

CASE HISTORY

Sr. No.: 01 Year : 2021

Patient's Name : Shalaka Dixit O.P.D. No.: 82685

Age : 28 years Date : 14/12/21

Sex : Female Occupation : Architect

Address: Vimannagar, Pune Income: 40,000/-

Chief Complaint : Patient complains of uncleaned teeth since 1 month

History of present illness : Patient was apparently asymptomatic 1 month ago. Then, she noticed uncleaned teeth

Past Dental History : Patient has undergone RCT $\bar{c}$ $\frac{+}{6}$ tooth which was deeply carious, in 2014 at private dental clinic. Then Patient also has undergone restorative treatment (composite restoration) $\bar{c}$ $\frac{+}{6|}$ in 2014 at private clinic.

Past Medical History :

NRH

Family History :

NRH

Personal History: Diet - Vegetarian (+ eggs)

Oral hygiene habits: Horizontal brushing once a day with medium toothbrush & toothpaste. No other dental hygiene aids are being used.

Other habits :

Extra Oral Examination :

Symmetry of face : Grossly symmetrical

Lips: Competent

Lymph Nodes : Normal (non palpable)

T.M.Joint: No deviation, clicking. Adequate movement is seen.

Intra Oral Examination :

Halitosis: Absent

Oral Mucous Membrane : No abnormalities detected

Tongeue: No abnormalities detected

Palate: No abnormalities detected

Gingiva :

	Region	Colour	Contour	Consistency	Surface Texture	Size	Bleeding On Probing	Exudation
MAXILLARY	Anterior	pink with pigmentation	Scalloped	Firm	Stippling +ve	Normal	~~Absent~~ present	Absent
	Posterior	-11-	-11-	-11-	-11-	-11-	present ~~Absent~~	-11-
MANDIBULAR	Anterior	-11-	-11-	-11-	-11-	-11-	-11-	-11-
	Posterior	-11-	McCall's festoon $\frac{C}{5}\frac{+}{5}$	-11-	-11-	-11-	-11-	-11-

Mucogingival Problems : None

Frenal Attachment :

Upper : Mucosal

Lower : Mucosal

Width of attached Gingiva : ✓ Adequate/Inadequate

Tension Test Negative

Periodontal Pockets :

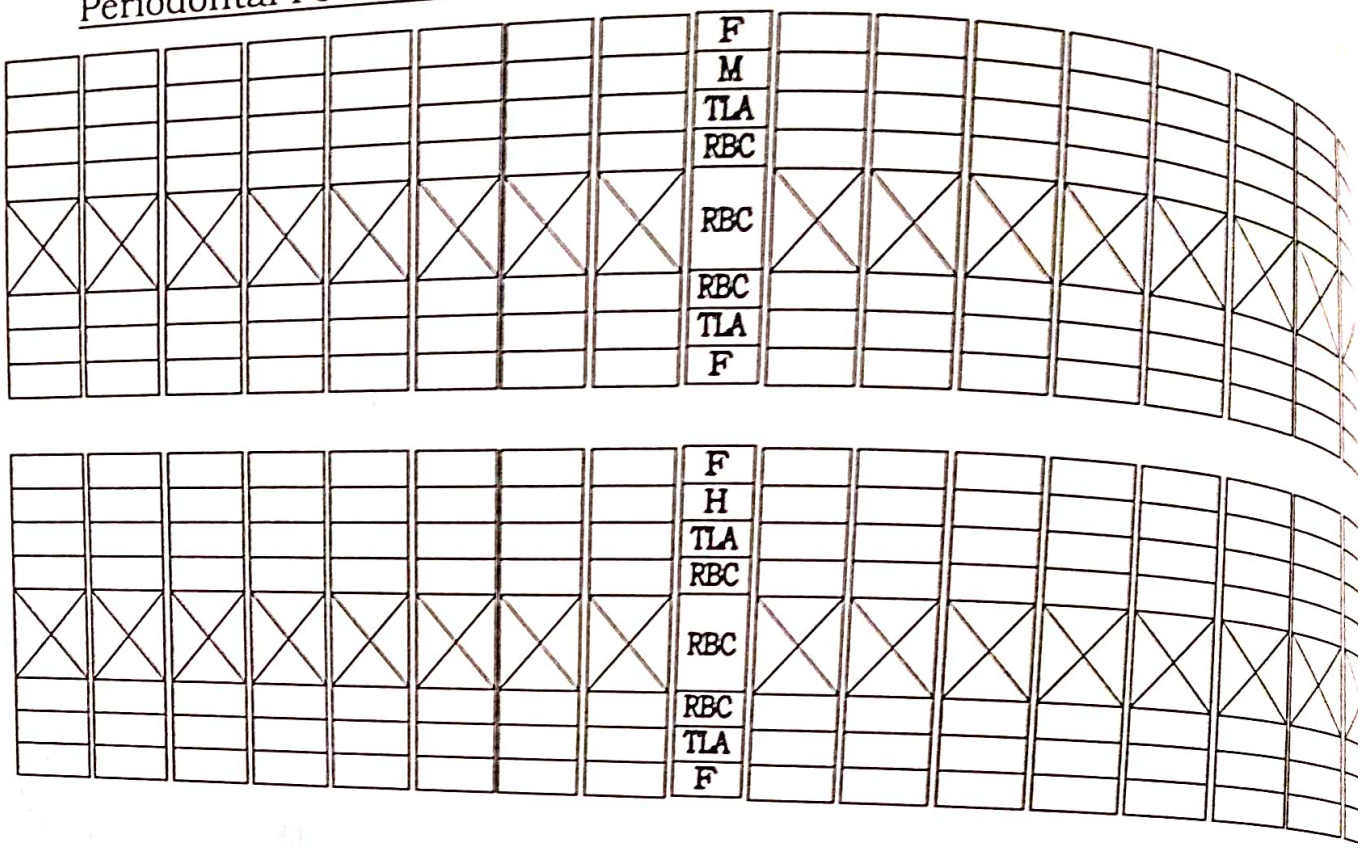

F- Furcation Involvement,

M- Mobility

TLA- Total loss of attachment,

REC- Recession,

PKT-Pocket

Examination of Teeth :

Teeth Present ; 32

Wasting Diseases :Attrition / Abrasion /Erosion

(–) (–) (–)

Carious Teeth : c̄ 6 +

Restored Teeth: c̄ 6 | 6 (6 + : RCT)

Faulty Restoration : –

Pathologic Migration: –

Drifting : –

Proximal Contacts : Close contacts

Food Impaction : –

Occlusion : Angle's Class I

Fremitus Test : -ve

Teeth Deposits : Plaque : ++ Calculus ++ Stains +

Hypersensitivity: –

Etiological Factors :

Local :

Primary :

Secondary :

Systemic :

Investigations : –

Laboratory : –

Radiographic : –

Diagnosis : Chronic generalized marginal gingivitis

Prognosis :

Overall: Good

Individual: Good

Treatment Plan

Preliminary/ Emergency Treatment ;

Phase I : Comprehensive scaling & root planing,
Or Brushing technique instructions
~~Tobacco~~

Phase II : —

Phase III:

Restoration $\overline{c}$ $\overline{6|}$

Phase IV: Maintenance phase

INDICES

1. Simplified Oral Hygiene Index (Greene & Vermillion 1964):

DI-S		

CI-S		

OHIS Score Per Person:

Oral Hygiene Status : Good / Fair / Poor

2. Plaque Index (Turesky- Gilmore Glickman, 1970)

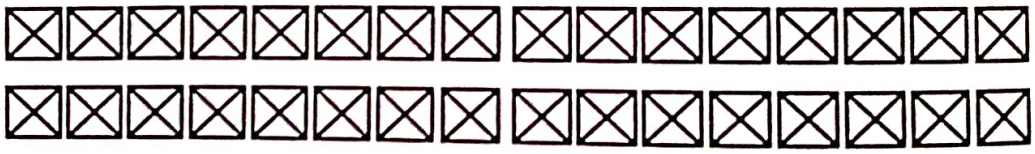

Plaque Score Per Person :

3. Gingival Index (Loe and Silness 1963)

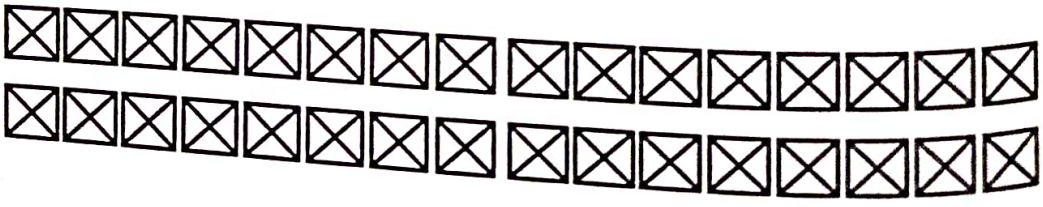

Gingival Score Per Person :

· CASE HISTORY

Sr. No.: 02

Year : 2021

Patient's Name : Aditi Mane

O.P.D. No.: 79928

Age : 19 years

Date : 15/12/2021

Sex : Female

Occupation : Student

Address: Lohegaon, Pune

Income: –

Chief Complaint : Patient complains of uncleaned teeth since 1 month.

History of present illness : Patient was apparently asymptomatic 1 month ago then she noticed some uncleaned teeth.

Past Dental History : Patient is undergoing root canal treatment $\frac{\bar{C}}{6}$. This tooth was paining due to deep caries. Endodontic therapy is being done since 1 month in D Y Patil Dental School. Obturation is done. Crown placement is remained.

Past Medical History :

NRH

Family History :

NRH

Personal History: –

Oral hygiene habits: Horizontally once a day with medium bristles toothbrush and toothpaste.

Other habits : –

Extra Oral Examination :

Symmetry of face : Grossly symmetrical

Lips: Competent

Lymph Nodes : Non palpable

T.M.Joint: No clicking sound, no deviation seen Adequate mouth opening.

Intra Oral Examination :

Halitosis: Absent

Oral Mucous Membrane : No abnormalities detected.

Tongeue: No abnormalities detected

Palate: No abnormalities detected

Gingiva :

	Region	Colour	Contour	Consistency	Surface Texture	Size	Bleeding On Probing	Exudation
MAXILLARY	Anterior	pink with pigmentation	Scalloped	Firm & resilient	Stippling seen	Normal	+ve	Absent
	Posterior	-"-	-"-	-"-	-"-	-"-	-"-	-"-
MANDIBULAR	Anterior	-"-	-"-	-"-	-"-	-"-	-"-	-"-
	Posterior	-"-	-"-	-"-	-"-	-"-	-"-	-"-

Mucogingival Problems : Absent

Frenal Attachment :

Upper : Gingival

Lower : Gingival

Width of attached Gingiva : Adequate/Inadequate

Tension Test Negative

Periodontal Pockets :

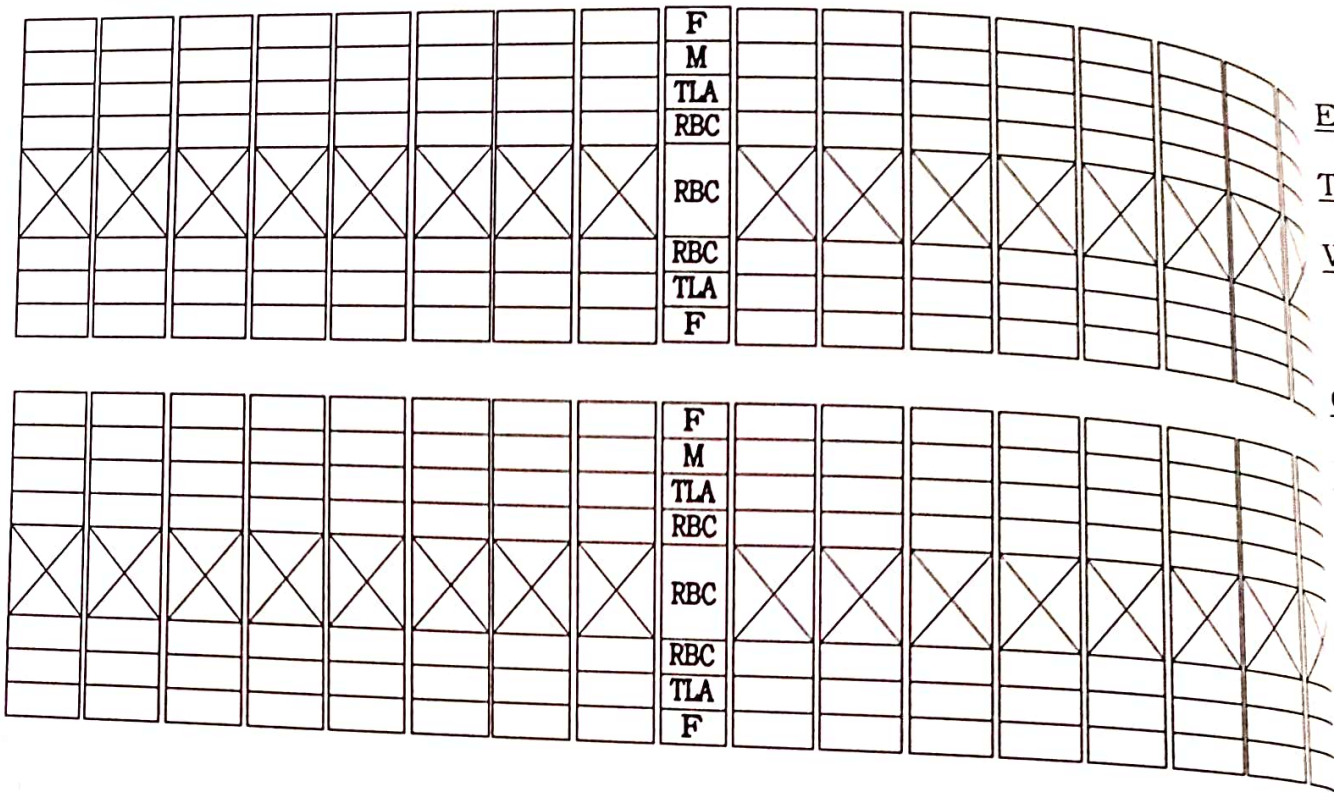

F- Furcation Involvement,

M- Mobility

TLA- Total loss of attachment,

REC- Recession,

PKT-Pocket

Examination of Teeth :

Teeth Present ; 28

Wasting Diseases :Attrition / Abrasion /Erosion

(-ve) (-ve) (-ve)

Carious Teeth : -

Restored Teeth: $\overline{C}$ $\overline{6}$

Faulty Restoration : -

Pathologic Migration: -

Drifting : -

Proximal Contacts : Tight contacts

Food Impaction : -

Occlusion : Angle's Class I

Fremitus Test : -ve

Teeth Deposits : Plaque : Calculus ++ Stains +

Hypersensitivity: -

Etiological Factors :

Local : -

Primary : -

Secondary : -

Systemic : -

Investigations : –

Laboratory : –

Radiographic : –

Diagnosis : Chronic generalized marginal gingivitis



Prognosis :

Overall: Good

Individual: Good

Treatment Plan

Preliminary/ Emergency Treatment ;

Phase I : Comprehensive Scaling & Root planing
Brushing technique instructions

Phase II : –

Phase III:
Crown $\bar{c}$ 6

Phase IV: Maintenance phase

INDICES

1. Simplified Oral Hygiene Index (Greene & Vermillion 1964):

DI-S		

CI-S		

OHIS Score Per Person:

Oral Hygiene Status : Good / Fair / Poor

2. Plaque Index (Turesky- Gilmore Glickman, 1970)

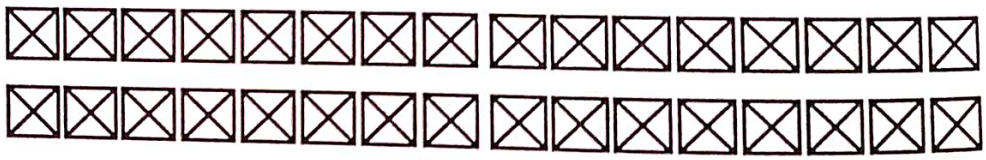

Plaque Score Per Person :

3. Gingival Index (Loe and Silness 1963)

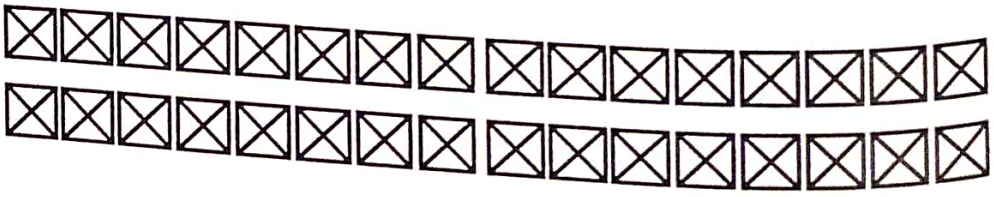

Gingival Score Per Person :

CASE HISTORY

Sr. No.: 03

Year :

Patient's Name : Babita Kelkar

O.P.D. No.: 83157

Age : Female 40 yrs

Date : 16/12/2021

Sex : Female

Occupation : Housewife

Address: Alandi, Pune

Income: –

Chief Complaint : Patient complains of unclean teeth since 1 month.

History of present illness : Patient was apparently asymptomatic 1 month ago then she noticed under teeth and food impaction in upper left posterior region of jaw.

Past Dental History : ~~NRH~~ None

Past Medical History : NRH

Family History : NRH

Personal History: Mixed diet

Oral hygiene habits: Pt brushes teeth twice a day with soft toothbrush & dentifrice - Horizontally
No other aids.

Other habits :
-

Extra Oral Examination :

Symmetry of face : Grossly symmetrical

Lips: Competent

Lymph Nodes : Non palpable

T.M.Joint: No clicking, deviation

Intra Oral Examination :

Halitosis: Absent

Oral Mucous Membrane :
No abnormalities detected.

Tongeue: No abnormalities detected.

Palate: No abnormalities detected.

Gingiva :

	Region	Colour	Contour	Consistency	Surface Texture	Size	Bleeding On Probing	Exudation
MAXILLARY	Anterior	pink with pigmentation	Scalloping	firm & resilient	Stippling absent	Normal	+ve	-ve
	Posterior	-11-	-11-	-11-	-11-	-11-	+ve	-ve
MANDIBULAR	Anterior	11	11	11	11	11	+ve	-ve
	Posterior	11	11	11	11	11	+ve	-ve

Mucogingival Problems : –

Frenal Attachment :

Upper : Mucosal

Lower : Mucosal

Width of attached Gingiva : ✓ Adequate/Inadequate

Tension Test – ve

Periodontal Pockets :

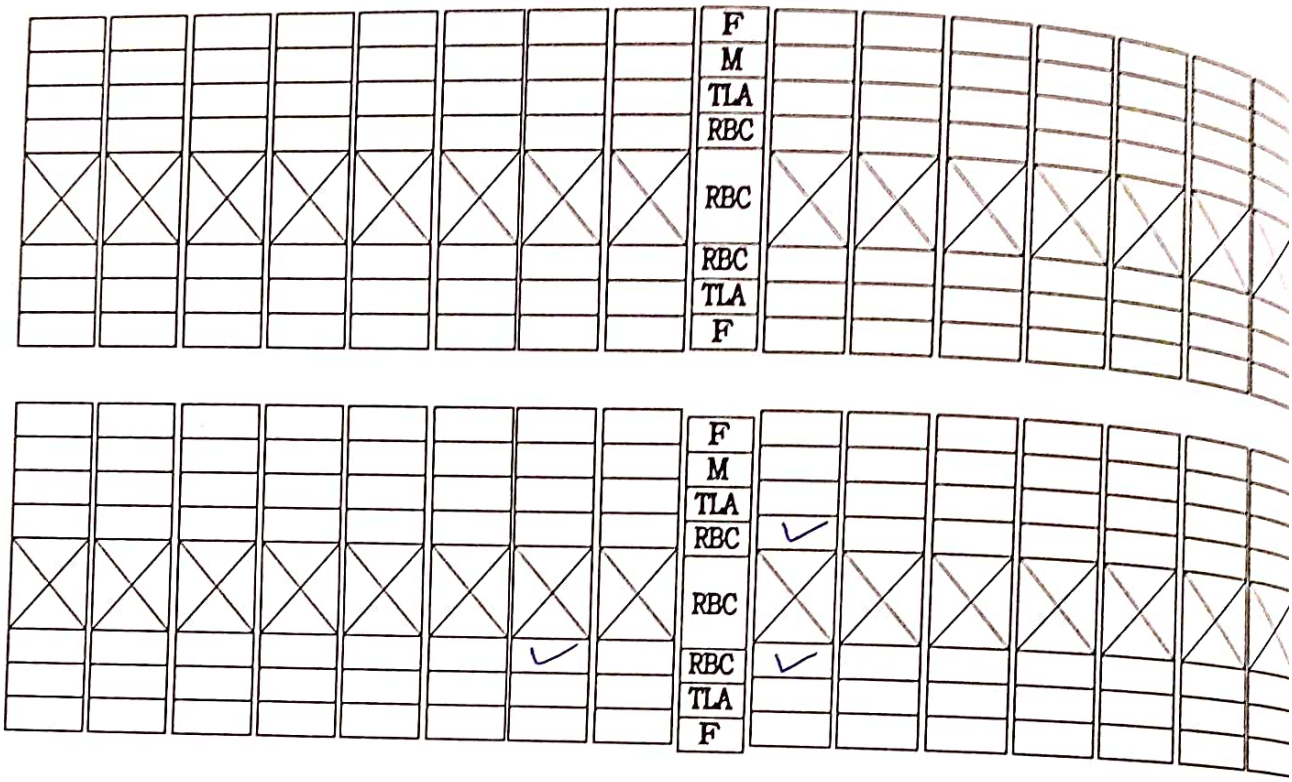

F- Furcation Involvement,

M- Mobility

TLA- Total loss of attachment,

REC- Recession,

PKT-Pocket

Examination of Teeth :

Teeth Present ;

Wasting Diseases :Attrition / Abrasion /Erosion

(21 \| 12) (-) (-)

Carious Teeth : 7 \| 6 / 7

Restored Teeth: –

Faulty Restoration : –

Pathologic Migration: -

Drifting : –

Proximal Contacts : Close

Food Impaction : +ve

Occlusion : Angles Class I

Fremitus Test : -ve

Teeth Deposits : Plaque : + Calculus ++ Stains –

Hypersensitivity: –ve

Etiological Factors : –

Local :

Primary :

Secondary :

Systemic :

Investigations : –

Laboratory : –

Radiographic : –

Diagnosis : Chronic generalized marginal gingivitis and localized periodontitis
Chronic

$\bar{c}$ 6 | 2 | 1

Prognosis :

Overall: Good

Individual: Good

Treatment Plan

Preliminary/ Emergency Treatment ;

Phase I : Comprehensive scaling & root planing
Brushing technique instructions
Other oral hygiene aids - interdental brushes, Dental floss.

Phase II : -

Phase III: Restorations $\frac{\overline{C}}{7}\Big|\frac{6}{7}$

Phase IV: Maintenance phase

INDICES

1. Simplified Oral Hygiene Index (Greene & Vermillion 1964):

DI-S		

CI-S		

OHIS Score Per Person:

Oral Hygiene Status : Good / Fair / Poor

2. Plaque Index (Turesky- Gilmore Glickman, 1970)

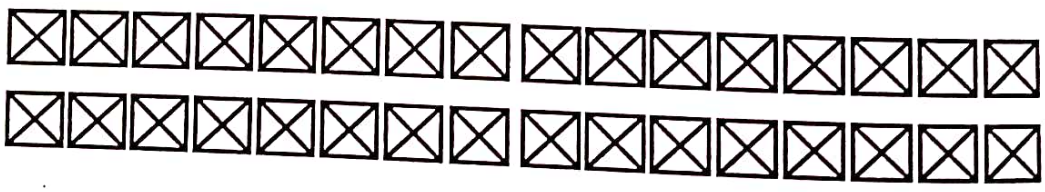

Plaque Score Per Person :

3. Gingival Index (Loe and Silness 1963)

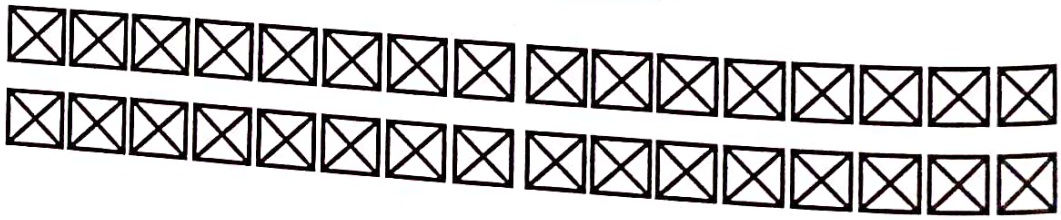

Gingival Score Per Person :

Examination of Teeth :

Teeth Present ; 28

Wasting Diseases :Attrition / Abrasion /Erosion

(-ve) (-ve) (-ve)

Carious Teeth : -

Restored Teeth: $\frac{C}{6}$ +

Faulty Restoration : -

Pathologic Migration: -

Drifting : -

Proximal Contacts : Tight contacts

Food Impaction : -

Occlusion : Angle's Class I

Fremitus Test : -ve

Teeth Deposits : Plaque : Calculus ++ Stains +

Hypersensitivity: -

Etiological Factors :

Local : -

Primary : -

Secondary : -

Systemic : -

Investigations : -

Laboratory : -

Radiographic : -

Diagnosis : Chronic generalized marginal gingivitis

Prognosis :

Overall: Good

Individual: Good

Treatment Plan

Preliminary/ Emergency Treatment ;

Phase I : Comprehensive Scaling & Root planing

Brushing technique instructions

Phase II : –

Phase III:

Crown $\bar{c}$ $\frac{}{6}$

Phase IV: Maintenance phase

INDICES

1. Simplified Oral Hygiene Index (Greene & Vermillion 1964):

DI-S		

CI-S		

OHIS Score Per Person:

Oral Hygiene Status : Good / Fair / Poor

2. Plaque Index (Turesky- Gilmore Glickman, 1970)

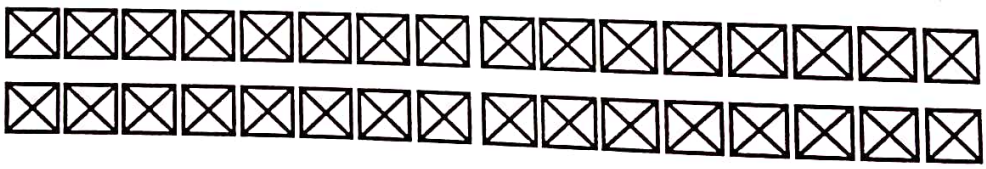

Plaque Score Per Person :

3. Gingival Index (Loe and Silness 1963)

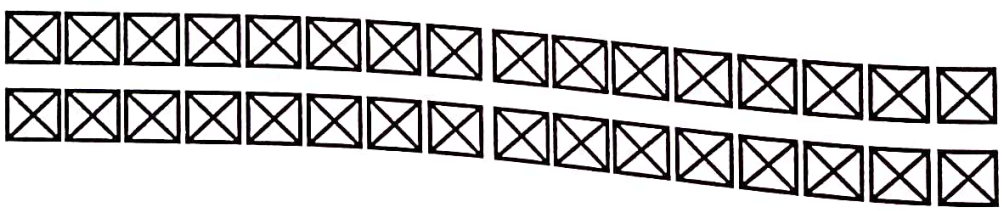

Gingival Score Per Person :

CASE HISTORY

Sr. No.: 03 Year :

Patient's Name : Babita Kelkar O.P.D. No.: 83157

Age : Female 40 yrs Date : 16/12/2021

Sex : Female Occupation : Housewife

Address: Alandi, Pune Income: –

Chief Complaint : Patient complains of unclean teeth since 1 month.

History of present illness : Patient was apparently asymptomatic 1 month ago then she noticed unc teeth and food impaction in upper left posterior region of jaw.

Past Dental History : ~~NRH~~ None

Past Medical History : NRH

Family History : NRH

Personal History: Mixed diet

Oral hygiene habits: Pt brushes teeth twice a day with soft toothbrush & dentifrice - Horizont
No other aids.

Other habits :
-

Extra Oral Examination :

Symmetry of face : Grossly symmetrical

Lips: Competent

Lymph Nodes : Non palpable

T.M.Joint: No clicking, deviation

Intra Oral Examination :

Halitosis: Absent

Oral Mucous Membrane :
No abnormalities detected.

Tongeue: No abnormalities detected.

Palate: No abnormalities detected.

Gingiva :

	Region	Colour	Contour	Consistency	Surface Texture	Size	Bleeding On Probing	Exudation
MAXILLARY	Anterior	pink with pigmentation	Scalloping	firm & resilient	Stippling absent	Normal	+ve	-ve
	Posterior	-11-	-11-	-11-	-11-	-11-	+ve	-ve
MANDIBULAR	Anterior	11	11	11	11	11	+ve	-ve
	Posterior	11	11	11	11	11	+ve	-ve

Mucogingival Problems : –

Frenal Attachment :

Upper : Mucosal

Lower : Mucosal

Width of attached Gingiva : ✓ Adequate/Inadequate

Tension Test – ve

Periodontal Pockets :

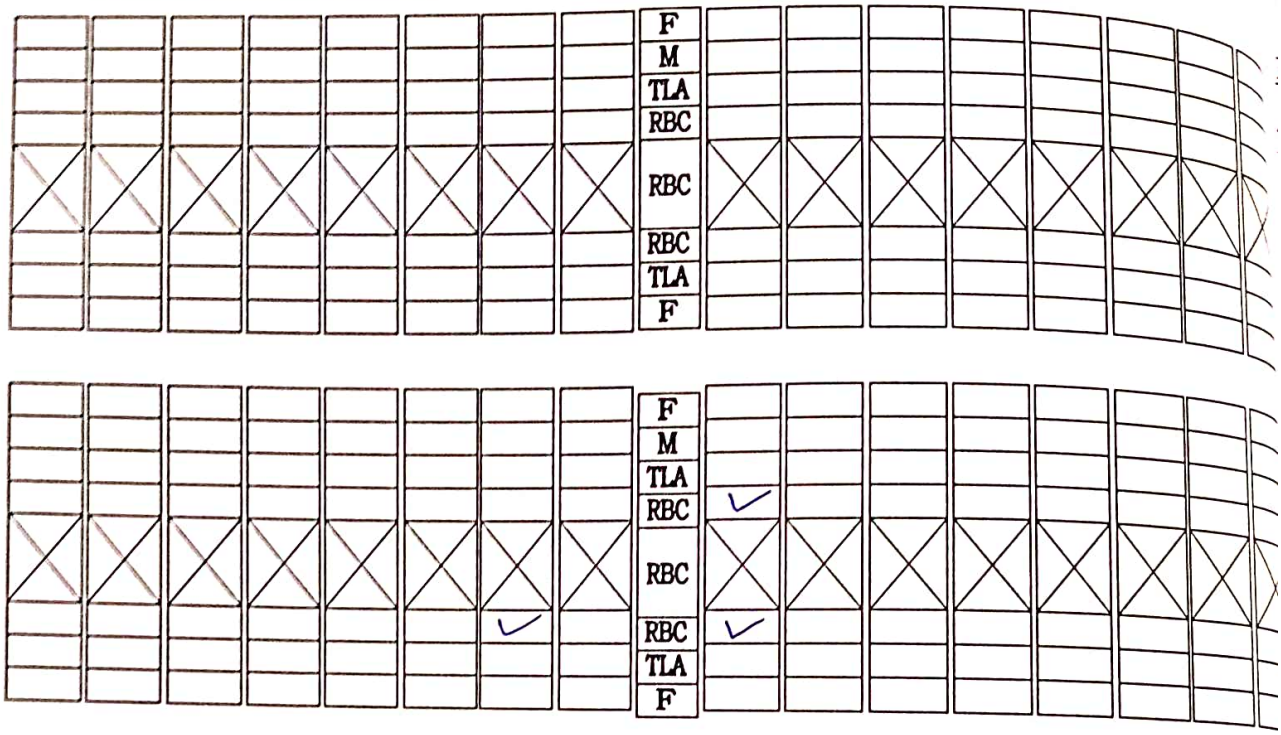

F- Furcation Involvement,

M- Mobility

TLA- Total loss of attachment,

REC- Recession,

PKT-Pocket

Periodontal Pockets :

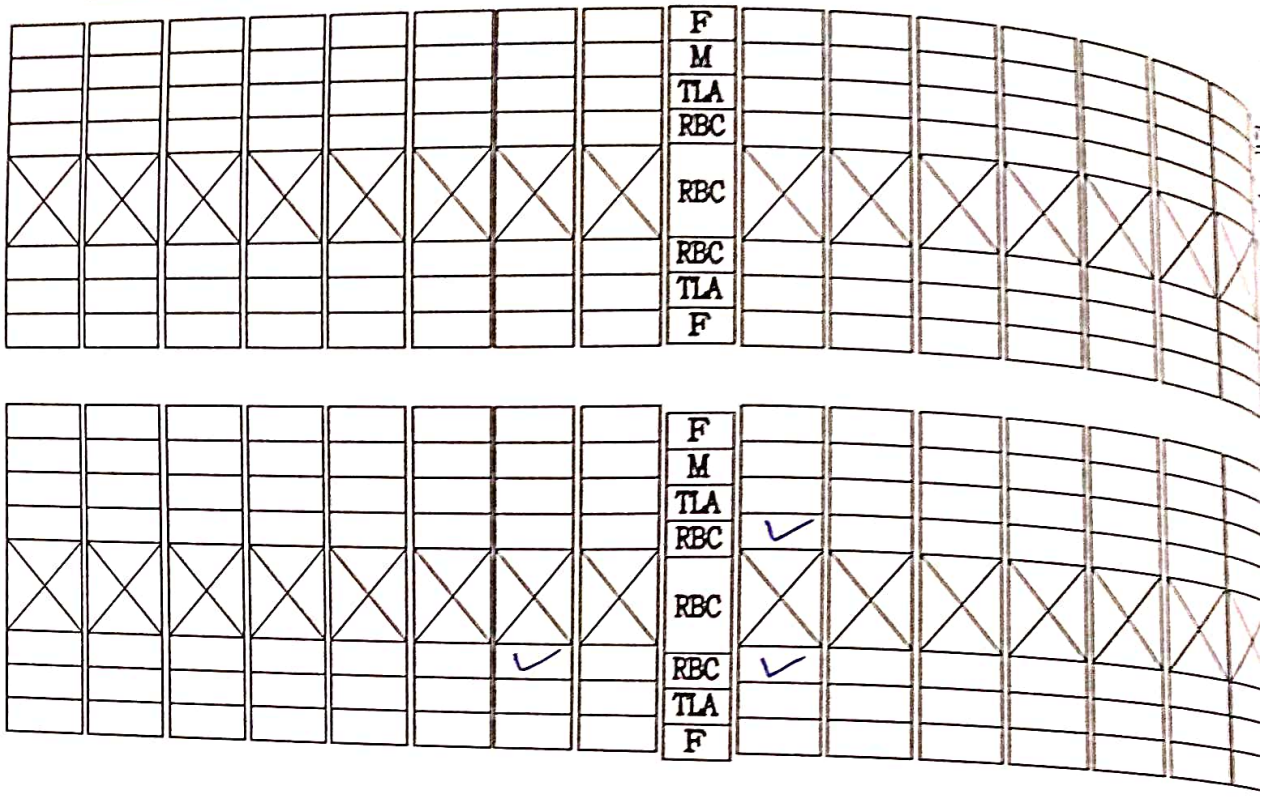

F- Furcation Involvement,

M- Mobility

TLA- Total loss of attachment,

REC- Recession,

PKT-Pocket

Examination of Teeth :

Teeth Present ;

Wasting Diseases :Attrition / Abrasion /Erosion

(21 \| 12) (-) (-)

Carious Teeth : 7 \| 6 / 7

Restored Teeth: –

Faulty Restoration : –

Pathologic Migration: –

Drifting : –

Proximal Contacts : Close

Food Impaction : +ve

Occlusion : Angles Class I

Fremitus Test : –ve

Teeth Deposits : Plaque : + Calculus ++ Stains –

Hypersensitivity: –ve

Etiological Factors : –

Local :

Primary :

Secondary :

Systemic :

Investigations : –

Laboratory : –

Radiographic : –

Diagnosis : Chronic generalized marginal gingivitis and localized periodontitis
Chronic

$\overline{C}$ 6 | 2 | 1

Prognosis :



Overall: Good

Individual: Good

Treatment Plan

Preliminary/ Emergency Treatment ;

Phase I : Comprehensive scaling & root planing
Brushing technique instructions
Other oral hygiene aids - interdental brushes , Dental floss.

Phase II : -

Phase III: Restorations $\overline{C}$ $\begin{array}{c|c} & 6 \\ \hline 7 & 7 \end{array}$

Phase IV: Maintenance phase

INDICES

1. Simplified Oral Hygiene Index (Greene & Vermillion 1964):

DI-S		

CI-S		

OHIS Score Per Person:

Oral Hygiene Status : Good / Fair / Poor

2. Plaque Index (Turesky- Gilmore Glickman, 1970)

☒☒☒

CASE HISTORY

Sr. No.: 04

Year : 2021

Patient's Name : Vishwas Devkar

O.P.D. No.: 83435

Age : 43 yrs

Date : 23/12/21

Sex : Male

Occupation : Driver

Address: Kalas Pune

Income: 30,000/-

Chief Complaint : Patient complains of pain in upper right back region of jaw and fractured tooth in same region. Patient also complains of unclean teeth since 1 month.

History of present illness : Pt was apparently asymptomatic 1 month ago, then he ~~not~~ undergone trauma & tooth got fractured also he noticed uncleaned teeth.

Past Dental History : Extraction due to caries $\bar{c}$ 6 (6 months ago)

Restoration $\bar{c}$ 5 2 years ago

Past Medical History : NRH

Family History : NRH

Personal History: –

Oral hygiene habits: Pt brushes teeth twice a day horizontally with toothbrush-past-medium No other aids

Other habits : None

Extra Oral Examination :

Symmetry of face : Grossly symmetrical

Lips: Competent

Lymph Nodes : Non palpable

T.M.Joint: No deviation, no clicking sound

Intra Oral Examination : ‡

Halitosis: Absent

Oral Mucous Membrane : No abnormalities detected

Tongeue: No abnormalities detected

Palate: No abnormalities detected

Gingiva :

	Region	Colour	Contour	Consistency	Surface Texture	Size	Bleeding On Probing	Exudation
MAXILLARY	Anterior	Pink with pigmentation	Scalloped	Firm & resilient	Stippling present	Normal	+ve	Absent
	Posterior	"	"	"	"	"	+ve	"
MANDIBULAR	Anterior	"	"	"	"	"	+ve	"
	Posterior	"	"	"	"	"	+ve	"

Mucogingival Problems : None

Frenal Attachment :

Upper : Mucosal

Lower : Mucosal

Width of attached Gingiva : ✓ Adequate/Inadequate

Tension Test -ve

Periodontal Pockets :

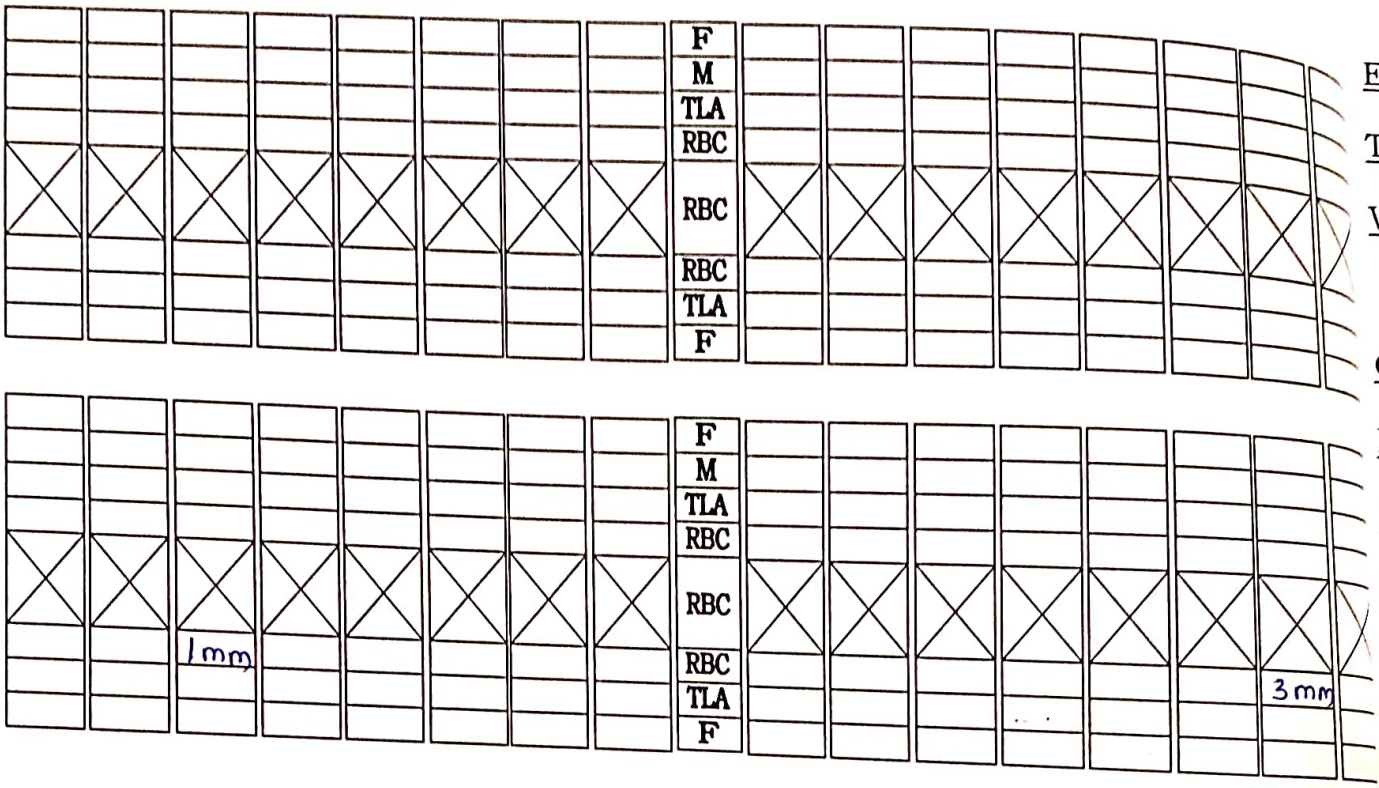

F- Furcation Involvement,

M- Mobility

TLA- Total loss of attachment,

REC- Recession,

PKT-Pocket

Examination of Teeth : 8 7 6 5 4 3 2 1 | 1 2 3 4 5 6 7 8
                        7 6 5 4 3 2 1 | 1 2 3 4 5 7 8

Teeth Present ; 30

Wasting Diseases :Attrition / Abrasion /Erosion

(1/1) (-) (-)

Carious Teeth : 5

Restored Teeth: *

Fractured restoration

Carious teeth : 8 7 | 8
                7 | 7

Faulty Restoration : -

Pathologic Migration: -

Drifting : -

Proximal Contacts : -

Food Impaction : -

Occlusion : Angles Class I

Fremitus Test : -ve

Teeth Deposits : Plaque : Calculus Stains

Hypersensitivity: -

Etiological Factors :

Local :

Primary :

Secondary :

Systemic :

Investigations :

Laboratory : –

Radiographic : –

Diagnosis : Chronic generalized marginal gingivitis with localized chronic preriodontitis $\frac{\bar{C}}{6|7}$

Prognosis :

Overall: Good

Individual: Good

Treatment Plan

Preliminary/ Emergency Treatment ;

Phase I : Comprehensive scaling & root planing
Proper Brushing technique instructions.

Phase II : 1) Root canal treatment $\bar{c}$ 7
2) Implant body placement $\bar{c}$ 6

Phase III: 1) Post endodontic treatment restoration (crown) 7
2) Crown of implant placement 6
3) Re-restoration $\bar{c}$ 5

Phase IV: Maintenance phase

Treatment Plan

Preliminary/ Emergency Treatment ;

Phase I : Comprehensive scaling & root planing
Proper Brushing technique instructions.

Phase II : 1) Root canal treatment $\bar{c}$ $\frac{7}{}$
2) Implant body placement $\bar{c}$ $\frac{}{6}$

Phase III: 1) Post endodontic treatment restoration (crown) $\frac{7}{}$
2) Crown of implant placement $\frac{}{6}$
3) Re-restoration $\bar{c}$ $\frac{}{5}$

Phase IV: Maintenance phase

INDICES

1. Simplified Oral Hygiene Index (Greene & Vermillion 1964):

DI-S		

CI-S		

OHIS Score Per Person:

Oral Hygiene Status : Good / Fair / Poor

2. Plaque Index (Turesky- Gilmore Glickman, 1970)

Plaque Score Per Person :

3. Gingival Index (Loe and Silness 1963)

Gingival Score Per Person :

CASE HISTORY

Sr. No.: 05 Year: 2021

Patient's Name: Anish Sarode O.P.D. No.: 82790

Age: 20 years Date: 17/12/2021

Sex: Male Occupation: Student

Address: Lohegaon Pune Income: -

Chief Complaint: Patient complains of uncleaned teeth since 5 months

History of present illness: Patient was apparently asymptomatic 5 months ago then he noticed uncleaned teeth.

Past Dental History: Patient has not undergone any dental treatment yet.

Past Medical History: NRH

Family History: NRH

Personal History: Mixed diet

Oral hygiene habits: Patient brushes teeth once a day horizontally with medium toothbrush. No other oral hygiene aids are being used

Other habits : –

Extra Oral Examination :



Symmetry of face : Grossly symmetrical

Lips: Competent

Lymph Nodes : Non palpable

T.M.Joint: No clicking, deviation

Intra Oral Examination :

Halitosis: Absent

Oral Mucous Membrane : No abnormalities detected

Tongeue: No abnormalities detected

Palate: No abnormalities detected.

Gingiva :

	Region	Colour	Contour	Consistency	Surface Texture	Size	Bleeding On Probing	Exudation
MAXILLARY	Anterior	pink with pigmentation	Scalloped	Firm	Stippling seen	Normal	+ve	-ve
	Posterior	-11-	-11-	-11-	Not seen		+ve	-ve
MANDIBULAR	Anterior	-11-	-11-	-11-	Stippling seen		+ve	-ve
	Posterior	-11-	-11-	-11-	Not seen		+ve	-ve

Mucogingival Problems : None

Frenal Attachment :

Upper : Mucosal

Lower : Mucosal

Width of attached Gingiva : ✓ Adequate/Inadequate

Tension Test Negative

Periodontal Pockets :



F- Furcation Involvement,

M- Mobility

TLA- Total loss of attachment,

REC- Recession,

PKT-Pocket

Periodontal Pockets :

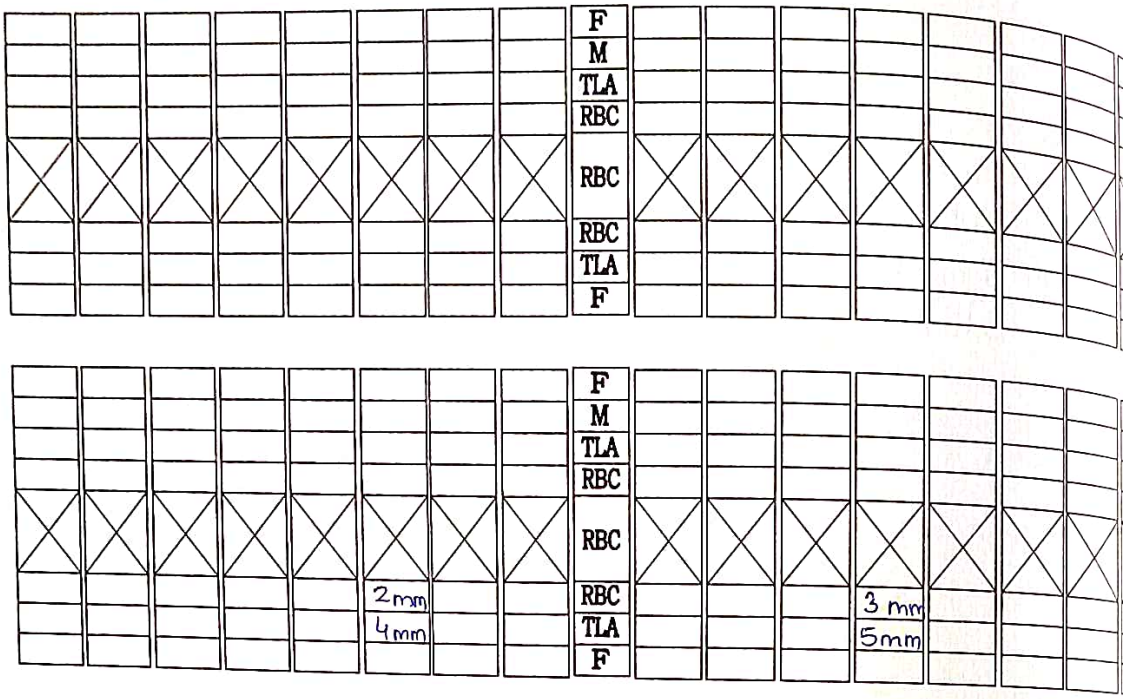

F- Furcation Involvement,

M- Mobility

TLA- Total loss of attachment,

REC- Recession,

PKT-Pocket

Examination of Teeth :

Teeth Present :

Wasting Diseases :Attrition / Abrasion /Erosion

(-) (-) (-)

Carious Teeth : $\frac{\bar{c}}{76|6}$

Restored Teeth: -

Faulty Restoration : -

Pathologic Migration: -

Drifting : -

Proximal Contacts : close contacts

Food Impaction : -

Occlusion : Angle's class III

Fremitus Test : -ve

Teeth Deposits : Plaque : ++ Calculus ++ Stains +

Hypersensitivity: -

Etiological Factors :

Local :

Primary :

Secondary :

Systemic :

Investigations : —

Laboratory : —

Radiographic : —

Diagnosis : Chronic generalized marginal gingivitis with chronic localized periodontitis c 3|4

Prognosis :

Overall: Good

Individual: Fair c 3|4

Treatment Plan

Preliminary/ Emergency Treatment ;

Phase I : Comprehensive ~~se~~ scaling & root planing treatment.
Brushing technique instructions
.

Phase II : Surgical phase.
Root coverage $\frac{\bar{c}}{3|4}$
(Gingival augmentation coronal to recession)

Phase III: Restoration $\frac{\bar{c}}{76|6}$
Orthodontic treatment for class III malocclusion.

Phase IV: Maintenance phase

INDICES

1. Simplified Oral Hygiene Index (Greene & Vermillion 1964):

DI-S		

CI-S		



OHIS Score Per Person:

Oral Hygiene Status : Good / Fair / Poor

2. Plaque Index (Turesky- Gilmore Glickman, 1970)

☒☒☒☒☒☒☒☒☒☒☒☒☒☒☒☒
☒☒☒☒☒☒☒☒☒☒☒☒☒☒☒☒

Plaque Score Per Person :

3. Gingival Index (Loe and Silness 1963)

☒☒☒☒☒☒☒☒☒☒☒☒☒☒☒☒
☒☒☒☒☒☒☒☒☒☒☒☒☒☒☒☒

Gingival Score Per Person :

CASE HISTORY

Sr. No.: 06

Year : 2021

Patient's Name : Pravin Kamble

O.P.D. No.: 96287

Age : 42 years

Date :

Sex : Male

Occupation : Shopkeeper

Address: Dhanori Kalas Pune

Income: 30,000/-

Chief Complaint : Patient complains of unclean teeth since 3 months

History of present illness : Patient was apparently asymptomatic 3 months ago. Then he noticed some uncleaned teeth.

Past Dental History : Patient has undergone RCT $\bar{c}$ $\overset{7}{+}$ 2 years ago in private dental clinic in Pune.

Past Medical History : NRH

Family History : NRH

Personal History: Diet - Mixed

Oral hygiene habits: Horizontal brushing once a day
No other aids.

Other habits : -

Extra Oral Examination :

Symmetry of face : Grossly symmetrical

Lips: Competent

Lymph Nodes : Non palpable

T.M.Joint: No clicking & deviation.

Intra Oral Examination :

Halitosis: Absent

Oral Mucous Membrane : No abnormalities detected

Tongeue: No abnormalities detected

Palate: No abnormalities detected.

Gingiva :

	Region	Colour	Contour	Consistency	Surface Texture	Size	Bleeding On Probing	Exudation
MAXILLARY	Anterior	Pink with pigmentation	Scalloped	Firm & resilient	Stippling	Normal	+ve	Absent
	Posterior						+ve	—11—
MANDIBULAR	Anterior						+ve	—11—
	Posterior						+ve	—11—

Mucogingival Problems : None

Frenal Attachment :

Upper : Mucosal

Lower : Mucosal

Width of attached Gingiva : Adequate/Inadequate

Tension Test Negative

Periodontal Pockets :

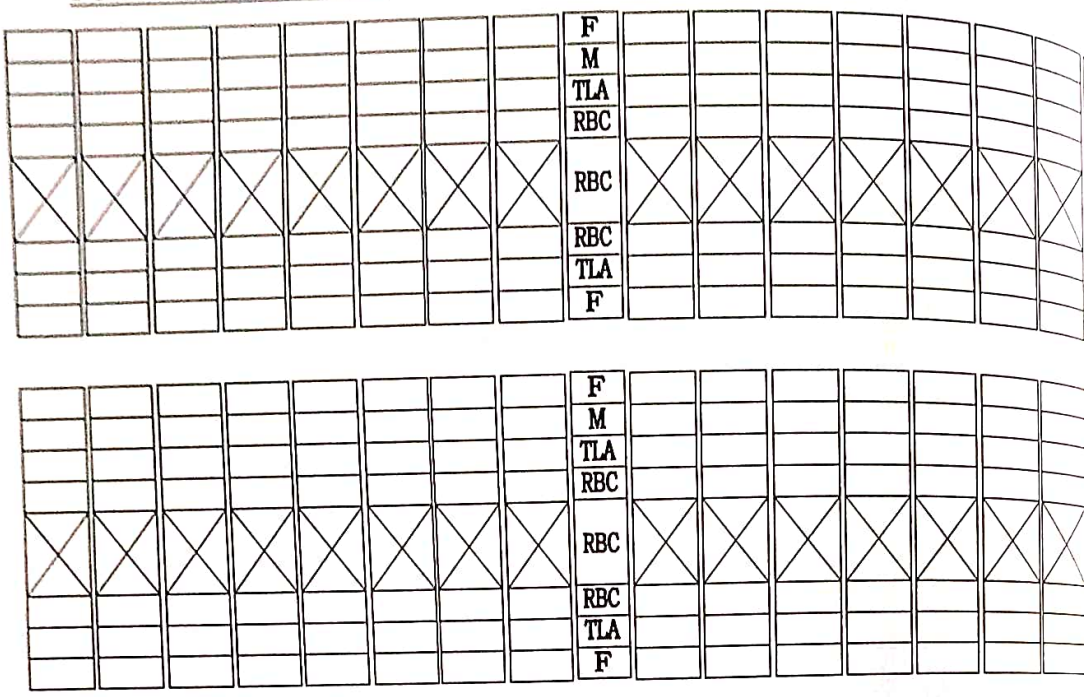

F- Furcation Involvement,

M- Mobility

TLA- Total loss of attachment,

REC- Recession,

PKT-Pocket

Examination of Teeth :

Teeth Present ; 32

Wasting Diseases :Attrition / Abrasion /Erosion

(-) (-) (-)

Carious Teeth : $\bar{c}$ +7

Restored Teeth: -

Faulty Restoration : -

Pathologic Migration: -

Drifting : -

Proximal Contacts : Close contacts

Food Impaction : -

Occlusion : Angle's Class I

Fremitus Test : Negative

Teeth Deposits : Plaque : + Calculus ++ Stains +

Hypersensitivity: -

Etiological Factors :

Local :

Primary :

Secondary :

Systemic :

Investigations : -

Laboratory : -

Radiographic : -

Diagnosis : Chronic generalized marginal gingivitis

Prognosis :

Overall: Good

Individual: Good

Treatment Plan

Preliminary/ Emergency Treatment ;

Phase I : Comprehensive scaling & root planing
Brushing technique instructions

Phase II : —

Phase III: Restoration $\overline{c}$ $\overline{7}$

Phase IV: Maintenance phase.

INDICES

1. Simplified Oral Hygiene Index (Greene & Vermillion 1964):

DI-S		

CI-S		

OHIS Score Per Person:

Oral Hygiene Status : Good / Fair / Poor

2. Plaque Index (Turesky- Gilmore Glickman, 1970)

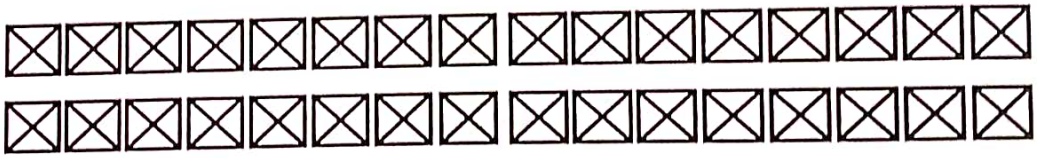

Plaque Score Per Person :

3. Gingival Index (Loe and Silness 1963)

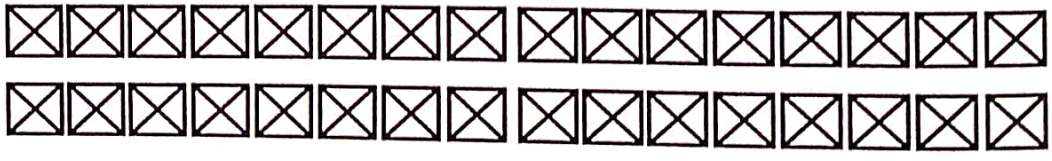

Gingival Score Per Person :

CASE HISTORY

Sr. No.: 07 Year :

Patient's Name : Khushi Bhat O.P.D. No.: 96424

Age : 20 years Date : 7/6/2022

Sex : Female Occupation : Student

Address: Lohegaon, Pune Income: –

Chief Complaint : Patient complains of unclean teeth since 2 months.

History of present illness : Patient was apparently asymptomati 2 months ago then she noticed some unclean teeth

Past Dental History : Patient has visited a private dental clinic for pain in right lower back region of jaw because of 3rd molar eruption (2 years ago).

Past Medical History : No relevant history

Family History : No relevant history

Personal History: Mixed diet

Oral hygiene habits: Patient brushes teeth once a day horizontally with toothpaste & toothbrush. No oth aids are being used.

Other habits : —

Extra Oral Examination :

Symmetry of face : Grossly symmetrical

Lips: Competent

Lymph Nodes : Non palpable

T.M.Joint: No clicking, no deviation, adequate mouth opening.

Intra Oral Examination :

Halitosis: Absent

Oral Mucous Membrane : No abnormalities detected

Tongeue: No abnormalities detected.

Palate: No abnormalities detected

Gingiva :

	Region	Colour	Contour	Consistency	Surface Texture	Size	Bleeding On Probing	Exudation
MAXILLARY	Anterior	Pink with pigmentation	Scalloped	Firm & resilient	Stippling present	normal	positive	negative
	Posterior	-11-	-11-	-11-	Stippling Not seen	-11-	-11-	-11-
MANDIBULAR	Anterior	-11-	-11-	-11-	Stippling present	-11-	-11-	-11-
	Posterior	-11-	-11-	-11-	Stippling not seen	-11-	-11-	-11-

Mucogingival Problems : None

Frenal Attachment :

Upper : Mucosal

Lower : mucosal

Width of attached Gingiva : Adequate Adequate/Inadequate

Tension Test Negative

Periodontal Pockets :

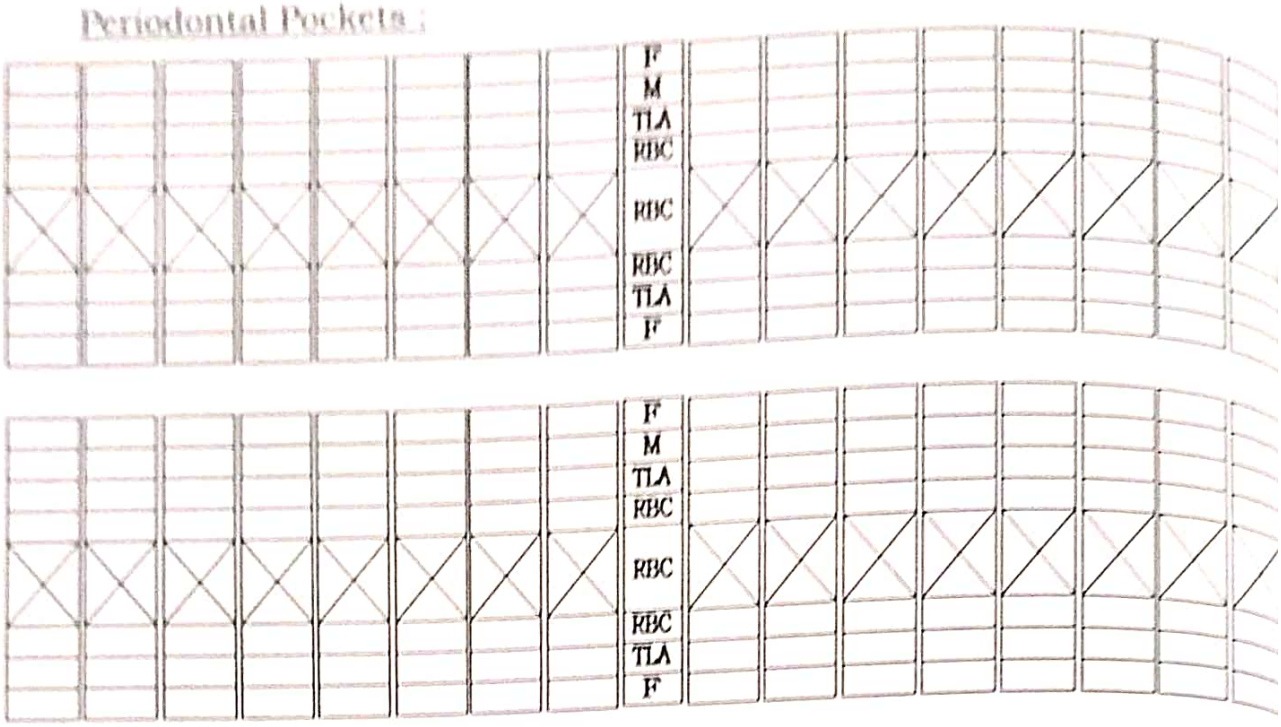

F- Furcation Involvement,

M- Mobility

TLA- Total loss of attachment,

REC- Recession,

PKT-Pocket

Examination of Teeth :

Teeth Present : 30 permanent, 2 retained deciduous

Wasting Diseases : Attrition / Abrasion / Erosion

Carious Teeth :

Restored Teeth: –

Faulty Restoration : –

Pathologic Migration: –

Drifting : –

Proximal Contacts : tight contacts

Food Impaction : –

Occlusion : Angles class I malocclusion

Fremitus Test : Negative

Teeth Deposits : Plaque : ++ Calculus + Stains

Hypersensitivity: –

Etiological Factors :

Local :

Primary :

Secondary :

Systemic :

Investigations : –

Laboratory : –

Radiographic : –

Diagnosis : Chronic generalized marginal gingivitis. ~~Overall health is good.~~

Prognosis :

Overall: Good

Individual: Good

Treatment Plan

Preliminary/ Emergency Treatment ;

Phase I :

Extraction of retained root in posterior maxilla.

Comprehensive scaling & root planing

Instructions about proper brushing technique ( ) given

Phase II :

—

Phase III: Restorations $\frac{7\,6\,4\,|\,6}{8\,7\,6\,|\,6\,7}$

Phase IV: Maintenance phase

INDICES

1. Simplified Oral Hygiene Index (Greene & Vermillion 1964):

DI-S		

CI-S		

OHIS Score Per Person:

Oral Hygiene Status : Good / Fair / Poor

2. Plaque Index (Turesky- Gilmore Glickman, 1970)

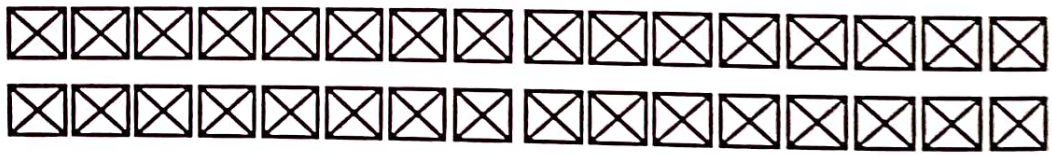

Plaque Score Per Person :

3. Gingival Index (Loe and Silness 1963)



Gingival Score Per Person :

Periodontal Probes

Periodontal probes are used to measure the depth of the pockets and to determine their configuration

The typical probe is tapered, rod like instrument calibrated in millimeters, with round and blunt tip.

Types of Periodontal Probes

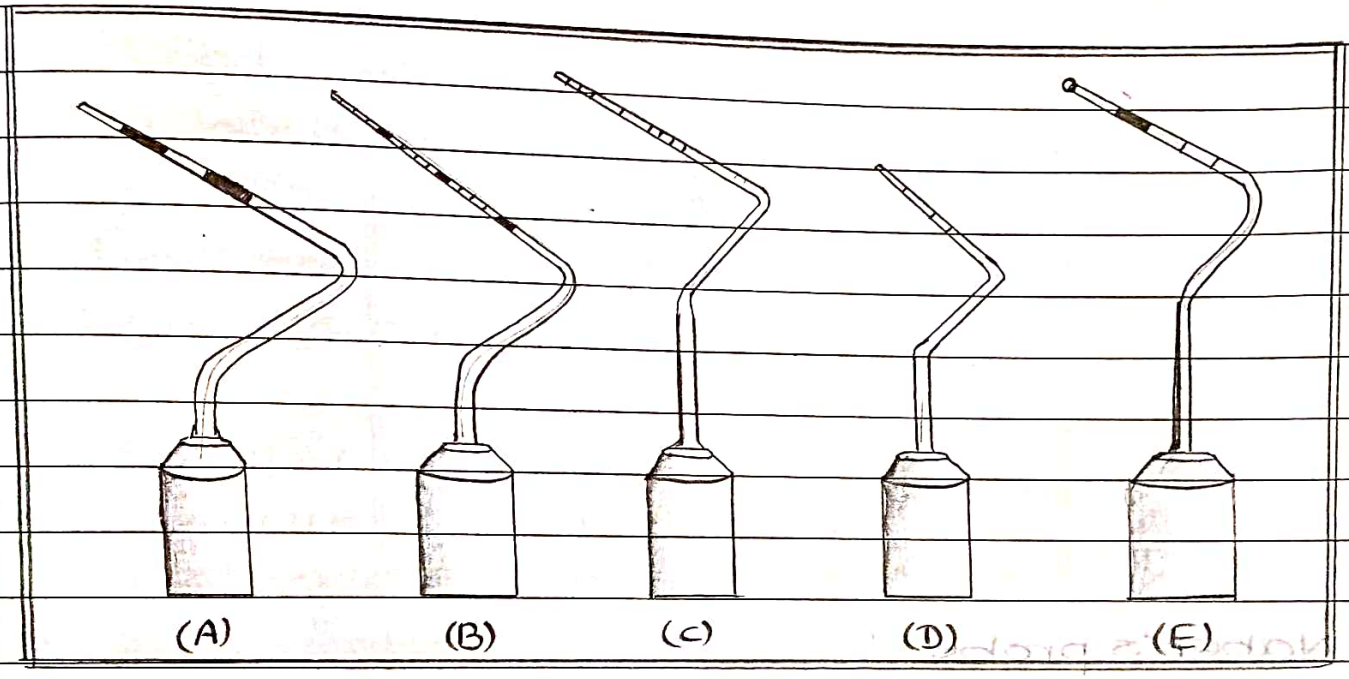

A) Marquis color coded probe
Calibrations are in 3mm sections

B) University of North Carolina - 15 probe
a 15 mm long probe with millimeter markings at each millimeter and color coding at the 5, 10 and 15mm

C) University of Michigan "0" probe with-
Williams markings at 1, 2, 3, 5, 7, 8, 9, and 10 mm)

D) Michigan "0" probe with markings at 3, 6 and 8 mm.

Classification of Periodontal Instruments

*enlivo
Date: __/__/____
Page: _____

Introduction:

Periodontal instruments are designed for specific purposes such as removing calculus, planing root surfaces, curetting the gingiva and removing diseased tissue.

Classification of periodontal instruments:

1. Periodontal probes
   (to locate, measure, mark pockets)

2. Explorers
   (to locate calculus deposites and caries)

3. Scaling, root planing and curettage instruments
   these are classified as -
   a) Sickle scalers
   b) Curettes
   c) Hoe, chisels, file scalers
   d) Ultrasonic and sonic instruments

4. Periodontal endoscopes.

5. Cleansing and polishing instruments.

- Parts of instrument :



Periodontal instrument is composed of :

i) Blade
ii) Shank
iii) Handle

- Mouth mirror :

- It is a diagnostic instrument with a reflecting mirrored surface on the working end.
- Uses :

i) Indirect vision : To view a tooth surface or intraoral structure that cannot be seen directly.
ii) Retraction : Use of mirror head to hold the patient's cheek, lip or tongue for better view structures.
iii) Indirect illumination : To reflect light onto a tooth surface where it is needed.
iv) Transillumination : Technique of directing light off the mirror surface and through the anterior te

- Classification of mouth mirror (According to types of surfaces) :

a) Front surface : Reflecting surface is on front s of glass that produces clear image with no distortion and good image quality.
- It can be easily damaged and are expensive

b) Plane (flat surface) : Reflecting surface is on t back surface of mirror lens and produces double (ghost) images which can be distracting.

c) Concave surface : Reflecting surface is concave - front surface mirror that shows magnified image. -may lead to distortion.

I. Periodontal Probes :

Periodontal probes are used to locate, measure and mark pockets, as well as determine their course on individual tooth surfaces.
A typical probe is a tapered, rod like instrument callibrated in millimeters with a blunt rounded tip.
When measuring a pocket, the probe is inserted with a fine, gentle pressure to the bottom of the pocket.
The shank should be aligned with the long axis of the tooth.



II. Explorers :

- Explorers are used to locate calculus deposits, caries.
- Also used to locate subgingival deposits and check the smoothness of the root surfaces after root planing.
- Explorers are designed with diff.t shapes and angles for a variety of use according to its needs

*enlivo
Date: __/__/__
Page:

I. Periodontal Probes :

- Periodontal probes are used to locate, measure and mark pockets, as well as determine their course on individual tooth surfaces.
- A typical probe is a tapered, rod like instrument callibrated in millimeters with a blunt rounded tip.
- When measuring a pocket, the probe is inserted with a fine, gentle pressure to the bottom of the pocket.
- The shank should be aligned with the long axis of the tooth.

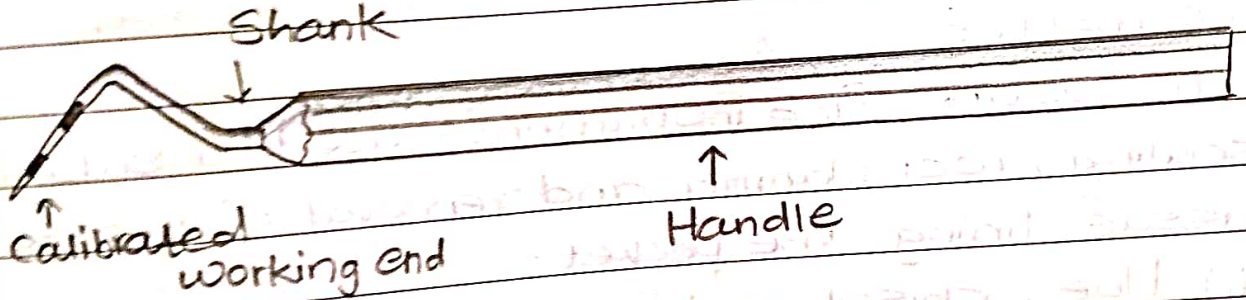

II. Explorers :

- Explorers are used to locate calculus deposits, caries.
- Also used to locate subgingival deposits and check the smoothness of the root surfaces after root planing.
- Explorers are designed with diff.t shapes and angles for a variety of use according to its needs

*enlivo
Date: / /
Page:

III. Scaling, root planing and curettage inst

- Used for removal of biofilm and calcified def from the crown, root of a tooth, removal of altered cementum from the subgingival root surface and debridement of the soft tissue lining the pocket.
- They are classified as below:

i) Sickle scalers:
- Have a flat surface and two cutting edges converge in a sharply pointed tip.
- It is primarily used to remove supragingival calculus.

ii) Curettes:
- These are fine instruments used for subgingiva scaling, root planing and removal of the soft tissue lining the pocket.

iii) Hoe, chisel and file scalers:
- Used to remove tenacious subgingival calcul and attached cementum.
- Their use is limited compared with that of curettes.
- Hoe scalers are used for scaling of ledges or rings of calculus.
- Chisel scalers are designed for the proximal surfaces of teeth.
- Files are used to fracture/crush calculus.

iv) Ultrasonic and sonic instruments:
- Used for scaling and cleaning of tooth surfaces and curettage the soft tissue wall of the

The five basic scaling instruments

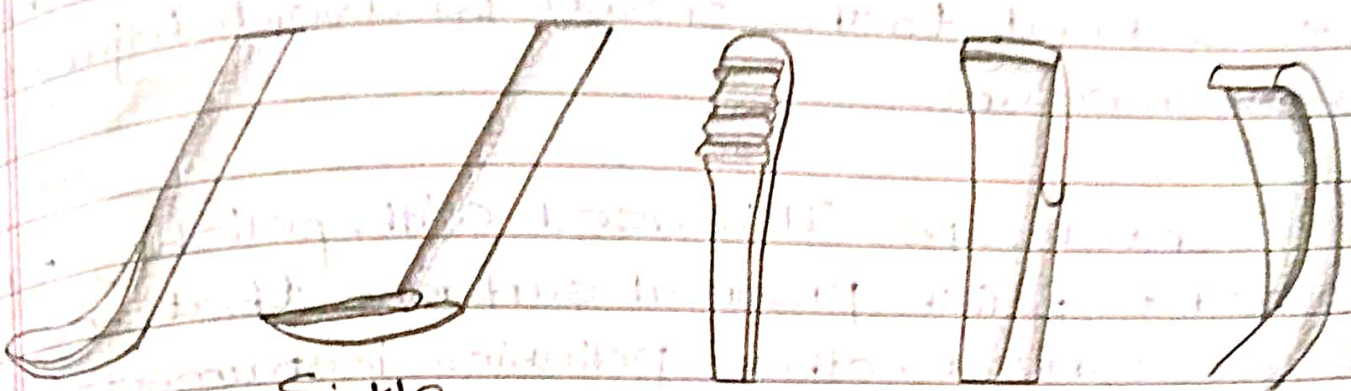

IV. Periodontal endoscopes :

- A dental endoscope has been introduced for use subgingivally in the diagnosis and treatment or periodontal disease
- This device allows clear visualization deeply into subgingival spockets and furcation.
- It permits operators to detect subgingival deposits and guides them in thorough removal of these deposits.

V. Cleansing and polishing instruments :

These instruments category consists of -

a) Rubber cups : They consist of a rubber shell with or without webbed configurations in the hollow interior.

- They are attached to the handpiece and a good cleansing & polishing paste that contains Fluoride is used to keep the rubber cups moist and minimize frictional heat.

b) Bristle brushes : There are available in wheel and cup shapes.

- Since the bristles are stiff, the brush should be confined to the crown to avoid injury to the cementum.

c) Dental tape: It is used with polishing paste used to polish proximal surfaces that are inaccessible to other polishing instruments.

d) Air-power polishing: A specially designed handpiece is used to deliver an air powered slurry of water and sodium bicarbonate for polishing.
- It is effective in removing extrinsic stains.

VI. Surgical instruments:
- Periodontal surgery is accomplished by various instruments.
a) Excisional and incisional instruments eg. Periodontal knives, interdental knives, surgical blades
b) Surgical curettes and sickles
c) Periosteal elevators
d) Surgical chisels.

Curettes

The curette is the instrument of choice for removing deep subgingival calculus, root planing altered cementum and removing the soft tissue lining the periodontal pocket.
Each working end has a cutting edge on both sides and a rounded toe.
The curette is finer than sickle scalers and does not have any sharp points or corners other than cutting edges of the blade.
Therefore, curettes can be adapted and provide good access to deep pockets, with minimal soft tissue trauma.
There are two types of curettes:

1. Universal
2. Area specific

1. Universal curettes

- Universal curettes have cutting edges that may be inserted in most areas of the dentition by altering and adapting the finger rest, fulcrum and hand position of the operator.
- The blade size and the angle and length of the shank may vary, but the face of the blade of every universal curette is at 90° angle (Perpendicular) to the lower shank when seen in cross section from the tip.

Examples - 1. The Barnhart curettes # 1-2 & 5-6
2. Columbia Curettes # 13-14, 2R-2L, 4R-4L
3. Younger Good # 7-8, McCall's # 17-18
4. Indiana University # 17-18

Date: ___/___/___
Page:

Basic characteristics of a curette:

Spoon shaped blade and rounded tip:



Basic characteristics of a curette

Specifications	Gracey Curette	Universal Cur
Area of use	Set of many curettes designed for specific areas and surfaces.	One curette desig for all areas and surfaces.
Cutting edge Use	One cutting edge used, work with outer edge only.	Both cutting edges used, work with either outer or inne edge.
Curvature	Curved in two planes blade curves up & to the side	Curved in one plan Blade curves up not to the side
Blade angle	Offset blade, face of blade beveled at 60 degree to shank	Blade not offset Face of blade beveled at 90° to shank

Diagrams

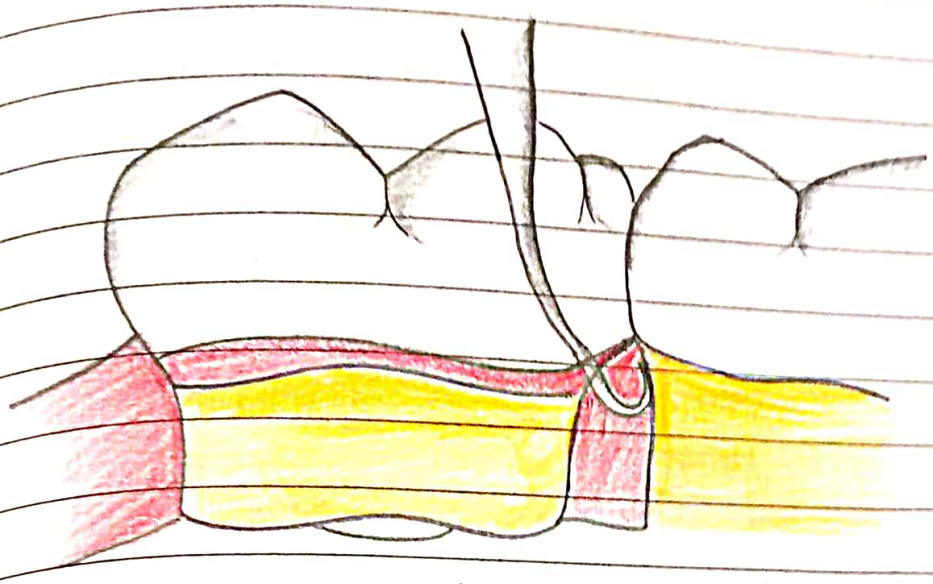

Curette inserted in pocket in a position of the base of a pocket on the distal surface of mandib. molar.

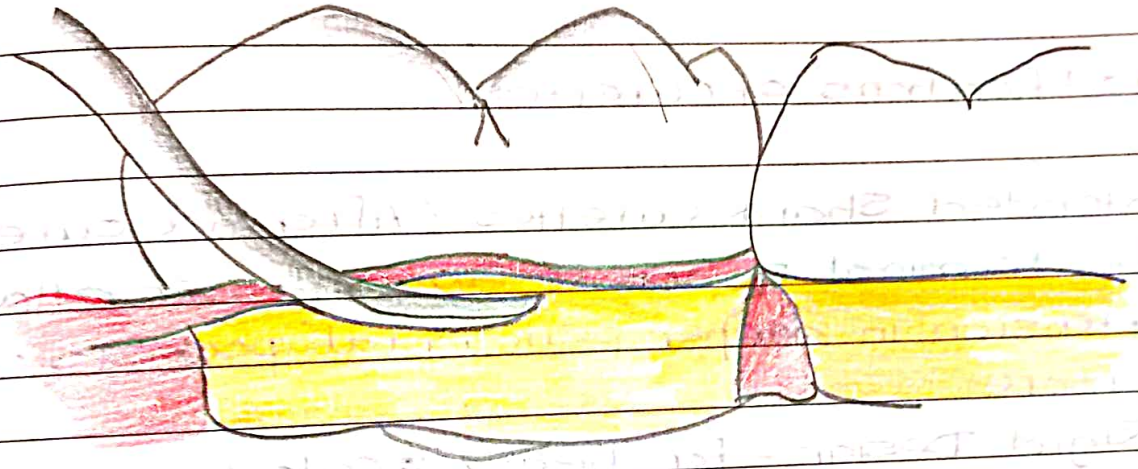

Curette inserted in apocket with the tip directed apically

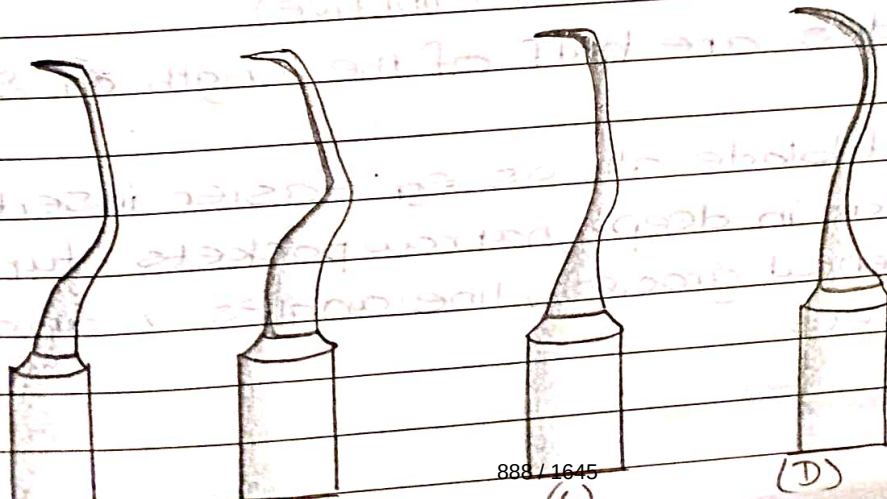

Micro mini five Gracey Curettes

Universal Curette

Gracey Curette



(A)

(B)

Modifications of curettes:

1) Extended Shank Curettes (After five curettes)
- The terminal shank is 3mm longer allowing extension in deeper periodontal pockets of 5mm or more
- Rigid Design - for heavy calculus removal
- Finishing design - light scaling or deplaquing.

2) Mini bladed curettes (Mini five)
- The blades are half of the length of Standard curettes
- The short blade allows easier insertion and adaptation in deep, narrow pockets, furcations, developmental grooves, line angles, and deep tight pockets.

3) Micro mini five Gracey curettes :
- Their blades are 20% thinner and smaller than mini five curettes.
- These are smallest of all curettes and provide exceptional access and adaptation to tight, deep or narrow pockets
- ~~These are smallest of all curettes, and provide e~~

4) Gracey Curettes (Set of 4 minibladed curettes)
- The blade length is 50% shorter than conventional Gracey curettes and blade is curved slightly upward.
- This curvature allows Gracey curettes to adopt more closely to tooth elf than any other curette.

5) Periodontal maintenance Curette (most recent → November 2015)
- The blade is 1mm shorter and 20% thinner, and face of the blade is offset from terminal shank at 60 degrees (Other Gracey designs offset at 70 degrees)
- These are used for patients with tight tissues, recessions and residual pocket depth following initial periodontal therapy or periodontal surgery.

6) Larger and mini Larger Curettes (Set of 3) :
- The universal blade is honed at 90° angle rather than offset blade of Gracey curette.

- This marriage of Gracey and universal cur
designs allows the advantages of area spe
shank to be combined with the versatility of
the universal curette blade.



Tutorials

RINCIPLES OF INSTRUMENTATION

Effective instrumentation is governed by a
f general principles that are common
e basic principles of instrumentation are -

Accessibility
Visibility, Illumination, retraction
Conditioning and sharpness of instruments
maintenance of clean field
Instrument stabilization < Instrument grasp / Finger rest

Instrument - Activation
- Adaptation
- Angulation
- Lateral pressure
- Strokes

1) Accessibility:
ccessibility facilitates thoroughness of instrumentation
e position of the patient and the operator should
provide maximum accessibility to the area
of operation. Neutral seated position for the
clinician — i) Forearm parallel to the floor
ii) Weight evenly balanced iii) Resting elbow should
be at the level of oval acuity
Thighs parallel to the floor
Back straight and head erect.
Avoid positioning your legs under the back of
patient chin. Four Basic positions -
7 0'clock, 9 0'clock, 10-11 0'clock, 12'o clock
Patient position -
For maxillary arch - Chin up
For mandibular arch - chin down

Tutorials

2) Visibility, Illumination and retraction :
- The operator should prefarably operate on the patient with direct illumination.
- The light beam of dental chair lamp shauld be oriented parallel to the viewing direction in order
- ~~The light beam of~~ to abbain shadow from lighting.
- Dental mirror is used for viewing the tooth surface that cannot be seen by direct vision.
- Transillumination : A mirror is used for transillumination It is effective only with anterior teeth because the are thin enough to allow light to pass through them.

Retraction - Mouth mirror is used to retract the lips and cheeks while retracting cheek with mouth mirror the index finger on non operating hand should be used to retract the lips and protect angle of mouth.

3) Conditioning and sharpness of instruments :
The working ends of the pointed or bladed instrument must be sharp to be effective.
- Methods to check instrument sharpness -
a) Glare test - A sharp cutting edge does not reflect but a dull instrument does.
b) Acrylic test
c) Clinical performance
d) Comparing with new instrument
- Advantages of sharp instrument -
  Easier calculus removal
  Improved stroke control
  Reduced no of strokes
  Increased patient comfort
  Reduced clinician fatigue

4) Maintaining clean, dry field :
Adequate suction is essential and can be achieved with saliva ejector or an aspirator.

Tutorials

Blood and debris can be removed using a suction by wiping and blotting with gauze squares.
Compressed air and gauzes can be used to facilitate visual inspection of tooth surfaces just below gingival margins during instrument?
Instrument stabilization:
Stability of the instrument and hand is primary requisite for controlled and effective instrumentation and avoidance of injury to the patient or clinician.
-Two factors that promote stability are
Instrument grasp:
Modified pen grasp: Most effective and stable Modification of standard pen grasp, ensures contact in performing instrument procedures. The thumb, index finger and middle finger is positioned so that side of pad next to finger nail is resting on instrument. The side of pad next to finger nail is resting on instrument shank. The index finger is bent at second joint from the finger tip and is placed midway between middle finger and the index finger This creates Tripod effect. It enhances control and tactile sensitivity.
Palm and thumb grasp: Used for stabilizing instrument during sharpening and for manipulating air and water syringes.
Finger rests:
. Finger rest serves to stabilize the hand and the instrument by providing a fulcrum as movements are made to activate the instrument.
Classification - 1) Intraoral finger rests
2) Extraoral finger rests

Modified pen grasp: **Tutorials**

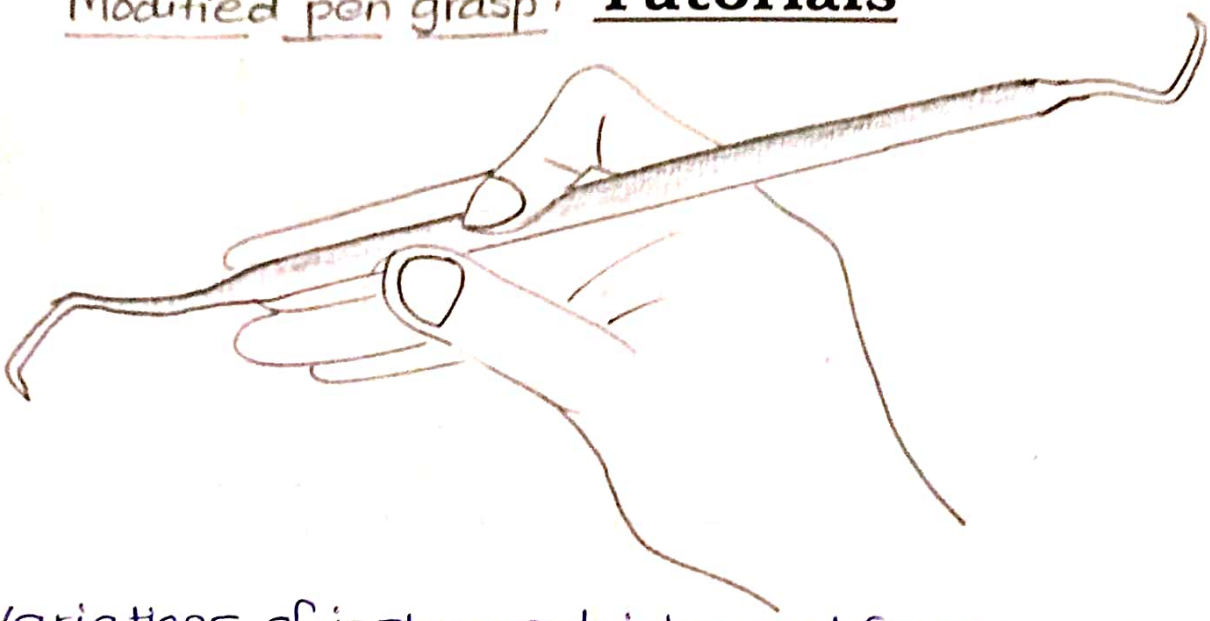

Variations of instrument intraoral finger rests -
- Conventional-adjacent teeth
- Cross arch - rest on other side of same arch
- opposite arch
- Finger on finger - The fingers rest is stabilizing the tooth surface by index finger or thumb of non operating hand.

Extra oral fulcrums -
- Palm up
- Palm down

Both intraoral and extraoral fulcrums may be reinforced by applying the index finger or thumb of non operating hand to the handle of instrument for added control and pressure against tooth.

6) Instrument activation:

• Adaptation: It refers to manner in which the working end of a periodontal instrument is placed against surface of tooth.

Objective of adaptation is to make the working end of the instrument conform to the contours of tooth surface. If an instrument is adapted so that only the tip is in contact, the soft tissue can be compressed by working end also causing trauma and discomfort.

Tutorials

Angulation - Refers to an angle bet.n the face of bladed instrument and the tooth surface. It may also be called the tooth blade relationship.
For subgingival insertion, angulation should be close to 0°

Lateral pressure - Lateral pressure may be firm, moderate or light often removing calculus. Lateral pressure is initially applied firmly or moderately and is progressively diminished auntil light lateral pressure is applied for final root planing.

Strokes - 3 basic types of strokes
1) Exploratory stroke
2) Scaling stroke
3) Root planing stroke

Exploratory stroke - It is light stroke that is used with probes and explorers to evaluate and dimensions of pocket and explorers to evaluate the dimensions of pocket and to detect calculus and irregularities of tooth surface.

Scaling stroke : It is a short powerful pull stroke that is used with bladed instrument for the removal of both supra and subgingival calculus. The muscles of finger and hands are tensed to establish a secure grasp and lateral pressure is established against tooth surface. The wrist and forearm motion, pivoting In an arc on finger rest produces a more powerful strokes and is therefore preferred for scaling.

Root planing strokes - It is moderate to light pull stroke that is used for final smoothening and planing of root surface.

Tutorials

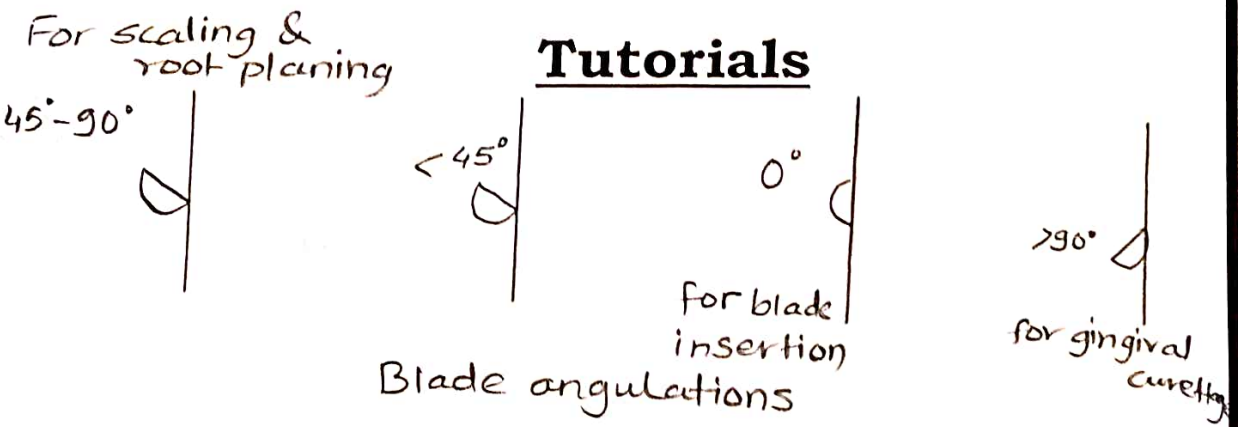

Blade angulations

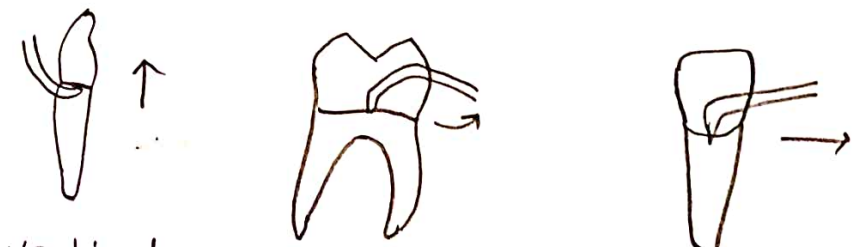

Vertical | Oblique | Horizontal

Blade stroke direction

Tutorials

Mechanical Plaque Control

Plaque control is the regular removal of microbial plaque and preservation of its accumulation on the teeth and adjacent gingival surfaces. It is also called as oral physiotherapy.

Plaque control
- Mechanical
  - Brushes
    - Natural
    - synthetic
    - Manual
    - Powered
  - Interdental aids
- Chemical

Toothbrushes:
The first toothbrush was made by William Addis in England 1780 The handle was carved from bone and brush from seume bristles
-Toothbrush design, ADA specification -119
Width - 3/8 - 5/16 inches
length - 1 - 1 1/4 inches
5-12 rows of tufts
80-86 tufts per bristle
Group of bristles is called tufts.
Diameter of toothbrush -
0.07 inches for soft bristles
0.012 inches for medium bristles
0.014 inches for hard bristles
Bristle hardness is directly proportional to square of diameter and inversely proportional to square of bristle length.
Powered toothbrushes -
1st created in Switzerland 1937

Tutorials

These have oscillating and rotating motion. Low frequency acoustic energy to enhance cleaning ability.

- Most commonly used in - Hospitalized patients children and with physical and mental disabilities, patients with fixed orthodontic appliances.

Dentrifrices -

These aid in cleaning and polishing tooth surfaces Dentifrices ingredients help in reducing calculus plaque, ~~den~~ gingivitis, stains.

Component	Composition		Material	Purpose
	Paste	Powder		
Abrasive	20-55%.	90-95%.	-Calcium Carbonate -Dibasic Ca -Silica	Removes plaque & Stains, polishes tooth surface
Detergents	1-2 %.	1-6 %.	Sodium lauryl sulfate	Aids in debris removal by ↓ surface tension
Colourants	1-2 %.	1-2 %.	Food colours TiO_2, mica	Used for coloured appearance.
Flavouring agents	1-2 %.	1-2 %.	Oil of menthol Sorbitol Peppermint	Provides Flavours
Humectants	20-30%.	0	Sorbitol, Glycerine	Moisture
Water	3%.	0	✗	Acts as Suspension

Tutorials

Binder	3%	0	Xantham gum Synthetic cellulose	Maintains viscosity
Fluorides Therapeutic agents			Sodium fluoride	Prevents caries
Tartar control	0-1%	0	Trisodium pyrophosphate	Inhibits formation of Calculus

Toothbrushing methods-
Horizontal scrub technique
Vertical - Leonard technique
Circular - Fones technique
Horizontal & Vibratory - Stillman's, Charter and Bass technique

Modified Bass technique -
Also called as sulcus cleaning technique
Indications - As a routine oral hygiene methode. Intrasulcular cleaning.

Technique -
The toothbrush is held in such a way that the bristles are at 45° to the gingiva. Bristles are gently vibrated by moving the brush back and forth. The bristle are then moved over the side of tooth towards their occlusal surfaces in a single motion in vertical direction.

Advantages -
Excellent, sulcus cleaning
Good interproximal and gingival cleaning
Good gingival stimulation.

Disadvantage - Dexterity of wrist is required.

Tutorials

Modified Stillman's technique -

Indications: For massaging the gingiva in cases of gingival recession, dental plaque removal from below the height of contour of the enamel & from exposed proximal surfaces.

Technique -

The bristles are pointed apically with an oblique angle to the long axis of the tooth.

The bristles are positioned partly on the adjacent gingiva. The bristles are activated by short back and forth motion are simultaneously moved in coronal direction.

Following 20 strokes the procedure is repeated systematically on adjacent teeth.

Disadvantage: Time consuming.

Improper brushing can damage epithelial attachment.

Charter's method -

Indications - Periodontal surgeries to promote healing and massaging.

Individual having open interdental spaces

Technique - Soft multitufted toothbrush is indicated for this technique. Bristles are pointed occlusally and are activated by mild vibratory strokes.

Advantage - Massage and stimulation for marginal and interdental gingiva.

Disadvantage - Brush ends do not engage the gingival sulcus to remove subgingival bacterial accumulation.

Tutorials

Interdental cleaning aids -
classification -
Based on types of embrasures :
Type I : Embrassure with no interdental gingival recession are adequately cleaned using a dental floss.
Type II : Longer surface with rounded interdental papillae and requires use of interproximal brushes.
Type III - Excessive recessed gingiva i-e. In diastema or exposed root furcation, single / ~~mul~~ unitufted brushes are used. eg Proxa brush.
Dental floss : Any toothbrush, regardless of the brushing method does not completely remove plaque biofilms Hence, interdental aids are necessary.

Types -

a) Monofilament or multifilament
b) Waxed, unwaxed
c) Twisted, non twisted

Interdental brushes - Concave root surface such as mesial aspect of the maxillary first premolar and furcation or if in periodontal patients there is significant attachment loss and recession are not cleaned by the floss.

Mufa
10/8/22

Tutorials

Classification -
1) Conical cylindrical 2) Tapered Rounded 3) Single tufted

Oral irrigation -
Aqua flosses are dental water jet has shown to significantly reduce gingivitis, bleeding on probing and periodontal pathogens.
- Either water or antimicrobial agents are used.
- MOA - It works on basis of hydrokinetic energy. Impact zone on which the solution initially comes in contact with the tooth surfaces.
Flushing zone - In which the solution reaches the subgingival sulcus and cleans it.
Clinical outcomes - Improved removal of plaque biofilm and reduction in calculus, gingivitis and bleeding on probing.

Chemical Plaque Control

Chemical plaque control is an adjunct to and not a substitute for mechanical plaque control.
An ideal chemical plaque control agent should have properties like -
1) Substantivity - Ability to bind to tissue surface and released over time.
2) Penetrability - ability to penetrate deeply into biofilm
3) Selectivity - Ability to affect a specific bacteria in mixed population.

Tutorials

Factors affecting to deliver clearance of plaque control agents from the oral cavity
1) Stability of active agent
2) Solubility of in oral cavity
3) Bio availability
4) Accessibility to site of action
5) Interaction between agent receptor site

Chemical plaque control agents are grouped as -

a) 1st generation
1) Phenolic compounds
- Phenol
- Thymol
- Triclosan
- Listerine
- Ethyl resorcinol

2) Quaternary ammonium compounds
Ethyl pyridinium fluoride
Benzothonium chloride

3) Antibiotics
Vancomycin
Kanamycin

b) 2nd generation
1) Bis biguanide
- Chlorhexidine
- Alexidine

2) Bispridine
Octenidine
Hydrochloride

3) Chlorhexidine

c) 3rd generation
Delmopinol

d) 4th generation
Probiotics

Tutorials

Halogens
- Iodine

Metallic ions
- Zinc
- Copper
- Tin
- Silver
- Mercury
- Herbal extracts

Antiplaque enzymes
- Mcrinase
  Mutanase
  Dextranase

Oxidizing fluoride

3) Chlorhexidine rinse –
This agent has shown most positive antibacterial results prescribed as twice a day with 10 ml of 0.2 % aqueous solution ~~is~~ of chlorhexidine digluconate.
It has completely inhibited dental plaque, calculus, gingivitis. It has a broad antimicrobial spectrum.

Mechanism of action :
At low concentration it causes leakage of intracellular potassium and reduction in bacterial acid production. Bacteristatic.
At high concentration it causes ~~leakage of intracellular p~~. bacterial cell wall disruption and coagulation of cytoplasmic constituents

Tutorials

It has also inhibited enzymes involved in bacterial adhesion bacterial growth and metabolism..

Side effects :-

It has reversible side effects. The teeth, tongue and silicate & resin restoration.

Imparement of taste.

It has low systemic toxicity

Anti Plaque action of chlorhexidine :

Preventing pellicle formation by blocking acid group on salivary glycoproteins

Preventing adsorption of bacterial cell wall to the tooth surface

Preventing binding of plaque by precipitation agglutination factors.

D Y PATIL GROUP

D Y PATIL DENTAL SCHOOL

Dr. D. Y. Patil Knowledge City, Charholi (BK) Via - Lohegaon, Pune - 412105

DEPARTMENT OF PERIODONTOLOGY

AND

ORAL IMPLANTOLOGY

Year : 2022-23

Name : Shraddha Ugran.

Roll No. : 75

Univ. Examination No.: 49627

Date 20/7/23 Signature of In -Charge Signature of HOD

INDEX

1. Do's and Don'ts for students.
2. List of Instruments for III B.D.S. and IV B.D.S. Clinics.
3. Clinical Quota.
4. Demonstrations.
5. Work Done.
6. Case History Sheets.
7. Tutorials.
8. Books for Reference .

Do's and Don'ts for Students

1. Students should be punctual to clinics and works sincerely.
2. Each student should wear a clean apron and strictly follow- Formal dress code with Name plate.
3. No Slippers or sports shoes allowed **formal shoesto be worn compulsory.**
4. Equipments in clinics should be **handled** with utmost care. Students shall be fined for any damage/loss.
5. No page from journal should be torn, nor any remark to be rubbed off.
6. Use of **Sterilized instruments,** Face **Mask, Head camp, Hand gloves** and **eye protector** is mandatory while working on a patient.
7. **Mobile Phones** are strictly not allowed in clinics. Any misbehavior in this regard shall lead to the mobiles being confiscated.
8. Students should pay attention to their personal hygiene, such as- nails should be trimmed and without nail polish.
9. Each student should carry the **Journal** daily for clinics.
10. Each student should make **Entries** in the work done and appointment register every day after treatment.
11. Students must take **signature** on case history and work done on the same day of treatment.
12. Students cannot leave the Department without permission.
13. Students shall be given demonstration of various procedures during the course of the postings, hence attendance is considered of utmost importance. Students who remain absent have to justify their absence appropriately.

List of Instruments for III B.D.S. and IV B.D.S. Clinics

1. Mouth Mask
2. Surgical Gloves
3. Head Cap
4. Eye Protector
5. Drape
6. Mouth Mirror
7. Explorer
8. Straight Probe
9. Willams Granduated Periodontal Probe.
10. Tweezer
11. Cotton Holder
12. Cotton Receiver
13. Disposable Glasses
14. Dappen Dish – 02
15. Kidney Tray – 01
16. Supragingival Scalers (Set of 8)
17. Subgingival Scalers (Set of 7)
18. Universal Curettes 2R/2L,4R/4L
19. Contra- angle Micromotor Handpiece
20. Polishing Cup -02
21. Polishing Brush -02
22. Green Cloth (3) and Instrument Pouch (2)
23. Oral Hygiene Demostration Kit

    (Tooth Brush

    Floss

    Small Face Mirror

    Study Cast- Upper & Lower)

(Note :- All the above instruments are mandatory during posting and should be in working condition.)

Clinical Quota

THIRD B.D.S

Sr. No.	NATURE OF WORK	No.
1.	Demostations.	5
2.	Case History And Clinical Examination	5
3.	Seminars.	1
4.	Supragingival /Subgingival Scaling	20

Final B.D.S.

Sr. No.	NATURE OF WORK	No.
1.	Demostations.	5
2.	Case History And Clinical Examination.	20
3.	Supragingival /Subgingival Scaling and Root Paining	30
4.	Curettage/Surgical Assistance.	1
5.	Seminars.	1

Demonstrations

III B.D.S.

Sr. No.	Date	Topic	Staff Signature
1.	11/1/22.	Principles of instrumentation. I.	Dr. Anuja.
2.	13/1/22.	Principles of instrumentation II.	Dr. Anuja.
3.	14/1/22.	Chemical plaque control.	Dr. Parag.
4.	17/1/22.	Mechanical plaque control. [Toothbrushes].	Dr. Sachin.
5.	18/1/22.	Mechanical plaque control.	Dr. Anuja.
6.	20/1/22.	Revision.	Dr. Parag.

III B.D.S.

Sr. No.	Date	Topic	Staff Signature
1.	20/5/22.	Mechanical plaque control. Revision.	Dr. Rakesh.
2.	24/5/22	Page I. Ch Discussion.	Dr. Parag.
3.	27/5/22	Page 2 Ch. Discussion.	Dr. Sachin.
4.	30/5/22.	Gingivitis / Diagnosis discussion	Dr. Parag.
5.			

Demonstrations

IV B.D.S.

Sr. No.	Date	Topic	Staff Signature
1.	9/1/23	CH Page I, II revision.	Dr. Anuja.
2.	10/1/23	CH Page III	Dr. Parag
3.	11/1/23	Diagnosis / Prognosis	Dr. Parag
4.	12/1/23.	Treatment Plan.	Dr. Sachin
5.			

IV B.D.S.

Sr. No.	Date	Topic	Staff Signature
1.	8/5/23	Periodontal Instrument revision.	Dr. Anuja
2.			
3.			
4.			
5.			

WORK DONE 3rd Ist.

Sr.No	Date	O.P.D.No	Name of work Done	Grade	Staff Signature
1.	4/2/22.	(Sonal Pimple) 86914 24 year.	Maxillary and mandibular hand Scaling done.		
2.	8/2/22. (87106)	Meghana Dhalkolia. (19 years)	Full mouth hand Scaling done.		
3.	9/2/22. [87207]	Kishor Gaikwad. [45 years].	Max. and Man. hand scaling done.		
4.	10/2/22. [45635]	Vishnu Yadav [32 years].	Full mouth hand scaling done.		

3rd IInd.

Sr.No	Date	O.P.D.No	Name of work Done	Grade	Staff Signature
5.	20/5/22.	94929 Irfan Shaikh [25 years]	Anterior Max. and Man. hand scaling done.		
6.	25/5/22. [32 years]	90471 Dipali Gaikwad	Full mouth hand scaling done.		
7.	26/5/22. [21 years].	Ishwar Pathade. [79415].	Full mouth hand Scaling done.		
8.	30/5/22. [20 years]	Athrav Borkar. [95775].	Maxillary and mandibular anterior hand scaling done.		

4th Ist.

Sr.No	Date	O.P.D.No	Name of work Done	Grade	Staff Signature
9.	31/5/22. [95887] 21 years.	Kshitij Sonawane	Full mouth hand scaling with polishing done.		
10.	7/1/23 [12872]	Rahul Dahekar 21 years.	Full mouth hand scaling done + Polishing done.		
11.	14/1/23 [20 years]	Nikita Chowdhari [116400]	Full mouth hand scaling done + polishing done.		
12.	21/1/23 [21 years]	Krishna Padule [117053]	Full mouth hand scaling done + polishing done.		

WORK DONE 4th IInd.

Sr.No	Date	O.P.D.No	Name of work Done	Grade	Staff Signat
13.	13/5/23. [21years]	Priya. Ukirde.	Full mouth hand scaling done + Polishing done.		
14.	20/5/23. [22years]	Pooja Lohar.	Full mouth hand scaling done.		

Sr.No	Date	O.P.D.No	Name of work Done	Grade	Staff Signa

Sr.No	Date	O.P.D.No	Name of work Done	Grade	Staff Signa

CASE HISTORY

Sr. No.: 1 **Year :** 4th Year.

Patient's Name : Mr. Salim Bale. **O.P.D. No.:** 114655

Age : 30 years. **Date :** 11/1/23

Sex : Male. **Occupation :** Delivery Agent

Address: Phulenagar, Alandi Road, Pune **Income:** 16,000 Rs/month.

Chief Complaint : Patient complains of uncleaned teeth since 2-3 months

History of present illness :

Patient was apparently asymptomatic 2-3 months back when he started experiencing white soft deposits on Tooth surface that gradually increased over 3 months. Patient has a history of tobacco chewing since 5-6 years, 2-3 times a day.

Past Dental History :

Extraction ⊼ 16.

Composite restoration ⊼ 37.

Past Medical History :

No relevant history.

Family History :

Both Parents are diagnosed with hypertension and diabetes.

Personal History: Mixed Diet.

Oral hygiene habits: Uses Toothbrush and Toothpaste [Dantkanti
Brushes once a day in morning.
Technique - Horizontal.

Other habits :

Tobacco chewing since 5-6 years, 2-3 times a day.

Extra Oral Examination :

Symmetry of face : No Gross Assymetry Detected.

Lips: Competent.

Lymph Nodes : Non-Tender
Non-Palpable.

T.M.Joint:

No abnormality detected.

Intra Oral Examination :

Halitosis: Present early in the morning as well as when the mouth is kept closed for longer time

Oral Mucous Membrane :

Tobacco Pouch Keratosis seen extending from 35 to 38 and 46 to 48 on Buccal Mucosa which is non-scrapable Homogenous type

Tongeue:

No abnormality detected.

Palate:

No abnormality detected.

Gingiva :

	Region	Colour	Contour	Consistency	Surface Texture	Size	Bleeding On Probing	Exudation
MAXILLARY	Anterior	Pink.	Scalloped & knife edged.	Firm and resilient.	Stippling present	Normal	Absent	Absent.
	Posterior	Pink.	Scalloped & knife edged.	Firm and resilent.	Stippling present	Normal.	Absent	Absent.
MANDIBULAR	Anterior	Reddish Pink.	Bulbous	Soft and Oedematous	Stippling present	Normal	Present	Absent.
	Posterior	Pink.	Scalloped and knife edged.	Firm and resilient	Stippling present	Normal	Absent	Absent.

Mucogingival Problems :

Frenal Attachment :

Upper : Gingival

Lower : Gingival

Width of attached Gingiva : ✓ **Adequate/Inadequate**

Tension Test Negative

Periodontal Pockets :

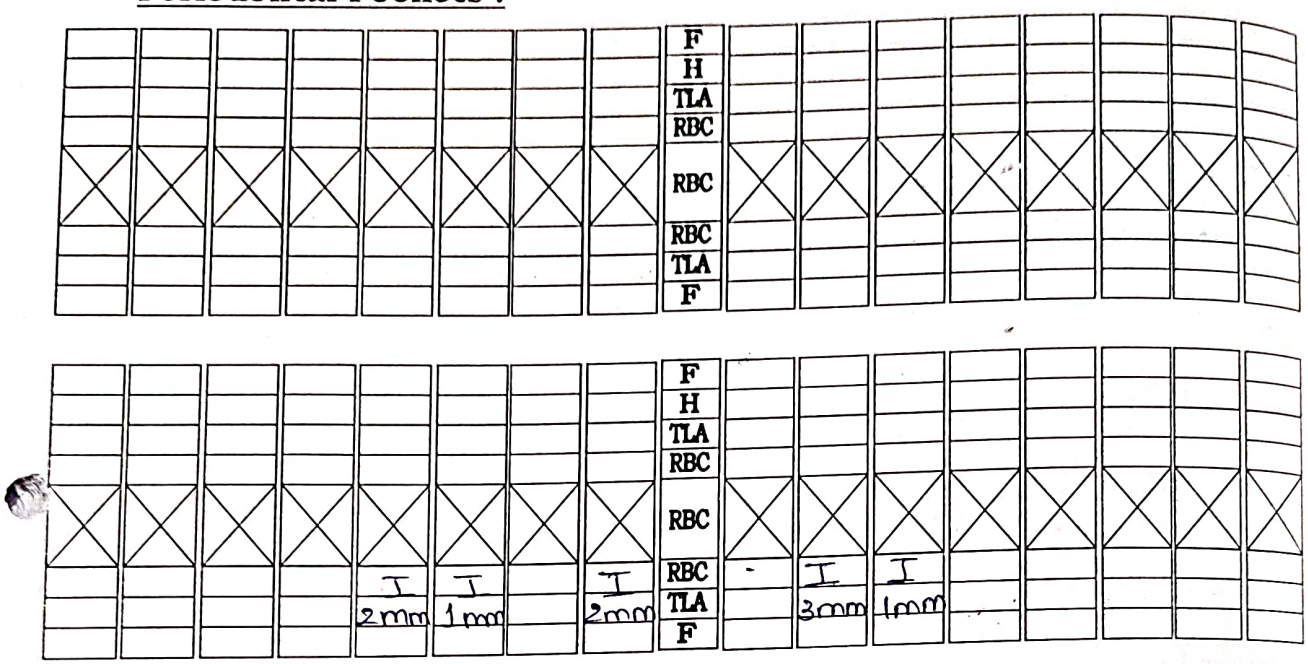

F- Furcation Involvement,

M- Mobility

TLA- Total loss of attachment,

REC- Recession,

PKT-Pocket

Examination of Teeth :

Teeth Present ;

8 7 6 5 4 3 2 1	1 2 3 4 5 6 7
8 7 6 5 4 3 2 1	1 2 3 4 5 6 7 8

Wasting Diseases : **Attrition** / **Abrasion** /**Erosion**

( ) ( ) ( )

Carious Teeth : Deep Occlusal caries $\bar{c}$ 36.
Pit and fissure caries $\bar{c}$ 38.

Restored Teeth: Composite restoration $\bar{c}$ 37

Faulty Restoration : Absent

Pathologic Migration: Absent.

Drifting : Absent.

Proximal Contacts : Tight.

Food Impaction : Absent.

Occlusion : Class I Molar Relationship - Left side.

Fremitus Test : Negative

Teeth Deposits : **Plaque :** + **Calculus** ++ **Stains** ++

Hypersensitivity:

Etiological Factors :

Local :

Primary : Plaque

Secondary : calculus, Faulty Brushing

Systemic : Absent

Investigations :

Laboratory : BT, CBC, PT-INR, CT, PTT, BSL.

Radiographic :

IOPA $\bar{c}$ +/7

Diagnosis :

Chronic localized periodontitis $\bar{c}$ 4 2 1 | 1 2 3

Prognosis :

Fair

Overall: Fair.

Individual:

Fair

Treatment Plan

Preliminary/ Emergency Treatment ;

Phase I : Non- surgical phase

1] Full Mouth scaling Advised.
2] Mechanical plaque control - Flossing Advised.
3] chemical plaque control- 0.2% Chlorhexidine Mouthwash.
4] Improve Brushing Technique - Modified Bass Technique
5] Excavation of caries and restoration $\bar{c}$ 38.

Phase II : Surgical phase

1] Root coverage procedure $\bar{c}$ $\frac{|}{4\,2\,1\,|\,1\,2\,3}$
2] Implant surgery $\bar{c}$ 16.
3] Root Canal Treatment $\bar{c}$ 36.

Phase III: Restorative phase

1] Prosthesis Crown $\bar{c}$ 36.

Phase IV: Maintenance Phase

class B - 3-4 months.

CASE HISTORY

Sr. No.: 2.

Year : Final Year, 2022-23.

Patient's Name : Mrs Hussanakaw Bhada.

O.P.D. No.: 116166.

Age : 50 years.

Date : 12/1/23.

Sex : Female.

Occupation : Housewife.

Address: Balaji Nagar, Yerawada, Pune.

Income:

Chief Complaint :

Patient complains of uncleaned teeth since 2-3 months

History of present illness : Patient was apparently asymptomatic 3 months back when she started experiencing white soft deposits on tooth surface that gradually increase over 3 months.

Past Dental History :

Extraction ⊼ 36 [Grossly decayed]

Extraction done before 1 year ago at Sassoon Hospital, Pune.

Past Medical History :

No relevant history.

Family History :

No relevant history.

Diet = Mixed.

Personal History: No relevant history.

Oral hygiene habits: Uses tooth brush and tooth paste [Colgate] brushes twice a day in morning and night [Horizontal].

Other habits :

No relevant history.

Extra Oral Examination :

Symmetry of face :

No gross asymmetry detected.

Lips:

Competant.

Lymph Nodes :

No abnormality detected.

T.M.Joint:

No abnormality detected.

Intra Oral Examination :

Halitosis:

Absent

Oral Mucous Membrane : No abnormality detected.

Tongeue:

Palate:

Gingiva :

	Region	Colour	Contour	Consistency	Surface Texture	Size	Bleeding On Probing	Exudation
MAXILLARY	Anterior	Pink.	Scalloped & knife edged.	Firm and resilient	Stippling present	Normal.	Absent	Absent.
	Posterior	Pink	Scalloped & knife edged.	Firm and resilient.	Stippling present	Normal	Absent	Absent.
MANDIBULAR	Anterior	Pink	Scalloped & knife edged.	Firm and resilient	Stippling present	Normal	Absent	Absent
	Posterior	Pink	Scalloped and knife edged.	Firm and resilient	Stippling present	Normal	Absent	Absent.

Mucogingival Problems : Absent.

Frenal Attachment :

Upper : Gingival

Lower : Gingival

Width of attached Gingiva : ✓ **Adequate/Inadequate**

Tension Test Negative

Periodontal Pockets :

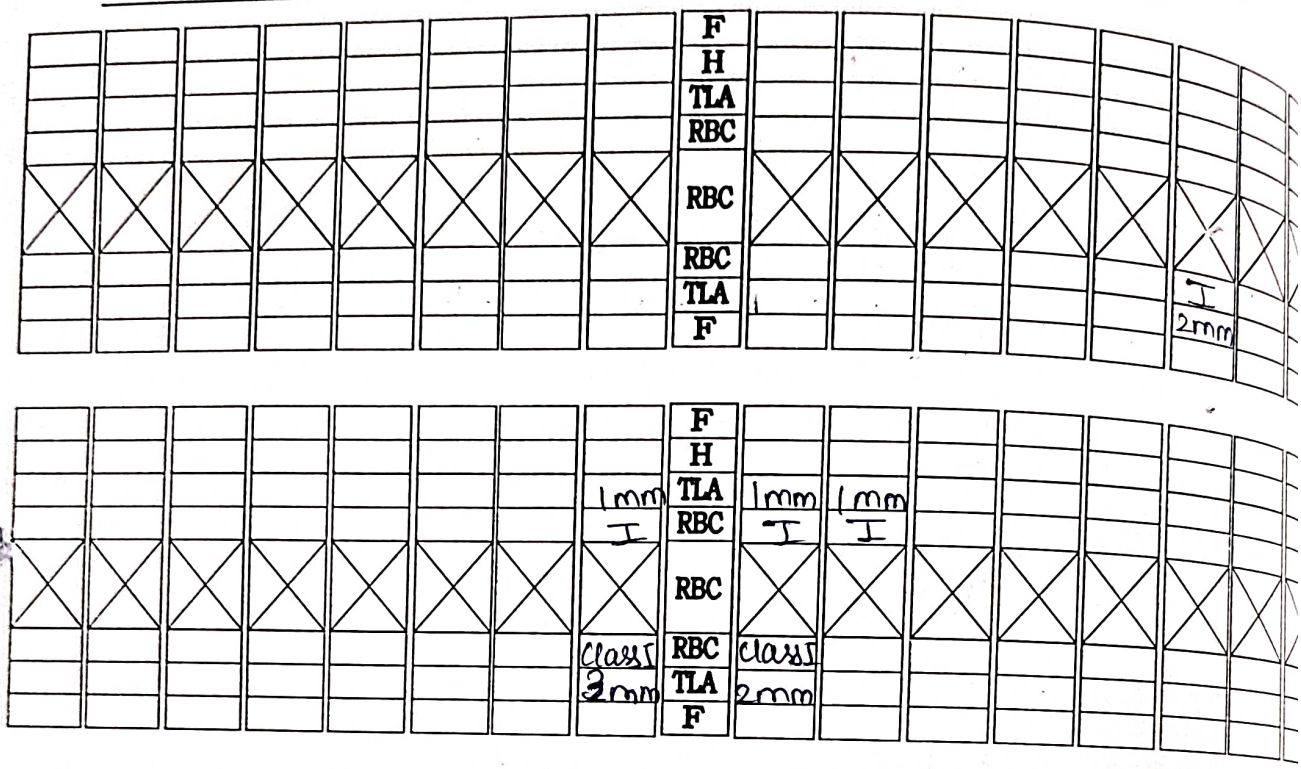

F- Furcation Involvement,

M- Mobility

TLA- Total loss of attachment,

REC- Recession,

PKT-Pocket

Examination of Teeth :

Teeth Present ;

8 7 5 4 3 2 1	1 2 3 4 5 6 7 8
7 6 5 4 3 2 1	1 2 3 4 5 7

Wasting Diseases : **Attrition** / **Abrasion** /**Erosion**

(46, 17, 41, 42, 43, 31, 32, 33.) (—) (—)

Carious Teeth : Mesioproximal caries ∈ 35, 15, Root piece ∈ 38, 48

Restored Teeth: Occlusal facet - 37, 36.

Faulty Restoration : Absent.

Pathologic Migration: ∈ 37

Drifting : Absent

Proximal Contacts : Tight contacts.

Food Impaction : Absent.

Occlusion : Class I.

Fremitus Test : Present [Trauma from occlusion present].

Teeth Deposits : **Plaque :** + **Calculus** ++ **Stains** +

Hypersensitivity: Present.

Etiological Factors :

Local :

Primary : Plaque

Secondary : Calculus, Faulty brushing Technique.

Systemic : Absent.

Investigations :

Laboratory : CBC, BTCT, PTINR, PTT, BSL.

Radiographic :

IOPA ☐ 38, 48, 35, 15

Diagnosis :

Chronic Localized periodontitis ☐ 6 | 1 | 12

Prognosis :

18/1/23

Overall:

Good

Individual:

Good.

Treatment Plan

Preliminary/ Emergency Treatment ;

Non- surgical.

Phase I : 1] Full mouth scaling advised.

2] Improve brushing technique - Modified stillman's technique.

3] Mechanical plaque control - Flossing advised.

4] Chemical plaque control - 0.2% chlorhexidine

5] Proper orthodontic treatment.

Phase II : Surgical phase

1] Root coverage procedure c̄ 6 / 1 | 12

2] Extraction c̄ 38, 48.

Phase III:

Restorative phase

Restoration c̄ 35, 15, 37, 26.

Phase IV:

Maintenance Phase

Class B - 3-4 months.

CASE HISTORY

Sr. No.: 3

Patient's Name : Mr. Kunal Barne

Age : 21 years.

Sex : Male.

Address: Kohegaon, Pune.

Year :

O.P.D. No.: 115140

Date : 14/1/23

Occupation : student.

Income: -

Chief Complaint : Patient complains of uncleaned teeth since 5-6 months.

History of present illness :

Patient was apparently asymptomatic 5-6 months back when he started experiencing white soft deposits on tooth surface that gradually increased over 6 months. Patient has a history of smoking khaikan occasionally (2-3 times a day).

Past Dental History :

No relevant history.

Past Medical History :

No relevant history

Family History :

No Relevant history.

Diet - Mixed Diet.

Personal History:

Oral hygiene habits:
① Uses Toothbrush and Toothpaste.
② Brushes once a day in morning.
③ Technique - Horizontal, circular.

Other habits :
Hukah (2 - 3 times a week) → occasionally.
Alcohol consumption → occasionally.

Extra Oral Examination :

Symmetry of face :
No gross asymmetry detected.

Lips: Competent.

Lymph Nodes :
Non-palpable, Non- Tender.

T.M.Joint: Clicking sound heard.
No Deviation seen.

Intra Oral Examination :

Halitosis:
No Relevant history.

Oral Mucous Membrane :
No abnormality Detected.

Tongeue:
No abnormality detected.

Palate:
No abnormality detected.

Gingiva :

	Region	Colour	Contour	Consistency	Surface Texture	Size	Bleeding On Probing	Exudation
MAXILLARY	Anterior	Pink with pigmentation	Scalloped and knife edged.	Firm and resilient.	Stippling present	Normal.	Absent	Absent.
	Posterior	Pink with pigmentation.	Scalloped and knife edged.	Firm and resilient	Stippling present	Normal.	Absent	Absent.
MANDIBULAR	Anterior	Reddish Pink with pigmentation	Scalloped and knife edged.	Soft and edematous	Stippling present	Normal.	Present	Absent
	Posterior	Pink with pigmentation.	Scalloped and knife edged	Firm and resilient	Stippling present	Normal.	Absent	Absent.

Mucogingival Problems : Absent.

Frenal Attachment :

Upper : Gingival

Lower : Gingival

Width of attached Gingiva : **Adequate/Inadequate** ✓

Tension Test Negative

Periodontal Pockets : No abnormality detected.

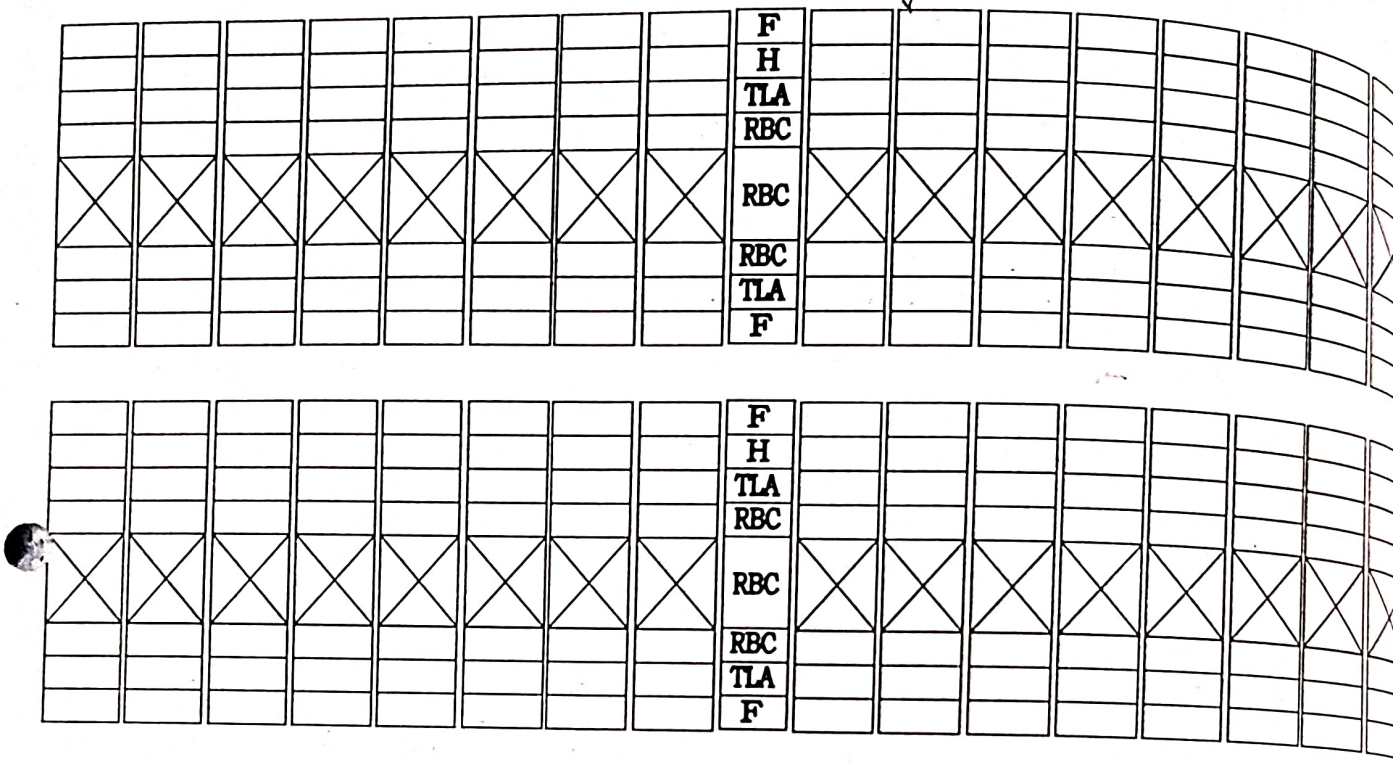

F- Furcation Involvement,

M- Mobility

TLA- Total loss of attachment,

REC- Recession,

PKT-Pocket

Examination of Teeth :

Teeth Present ;

7 6 5 4 3 2 1	1 2 3 4 5 6 7 8
8 7 6 5 4 3 2 1	1 2 3 4 5 6 7 8

Wasting Diseases : **Attrition / Abrasion /Erosion**

Carious Teeth :
① Pit and fissure caries c̄ 28, 45, 47, 17.
② Buccal pit caries c̄ 36, 37, 47

Restored Teeth: Absent.

Faulty Restoration : Absent.

Pathologic Migration: Absent.

Drifting : Absent

Proximal Contacts : Tight.

Food Impaction : Absent.

Occlusion : Class I Malocclusion [Anterior crowding present in maxillary and mandibular arch]

Fremitus Test : Positive

Teeth Deposits : **Plaque :** + **Calculus** ++ **Stains** +

Hypersensitivity: Absent.

Etiological Factors :

Local :

Primary : Plaque

Secondary : Calculus, Faulty Tooth Brushing Technique

Systemic :

Absent.

Investigations : –

Laboratory :

–

Radiographic : OPG

Diagnosis :

Chronic localized marginal gingivitis $\bar{c}$ $\frac{}{321|123}$

Prognosis :

Overall:

Good

Individual:

Good.

Treatment Plan

Preliminary/ Emergency Treatment ;

Phase I :

① Full Mouth scaling Advised.
② Improved Brushing Technique - Modified Bass Technique.
③ Mechanical Plaque control - Flossing advised.
④ Chemical Plaque control - 0.2% Chlorhexidine Mouthwash.
⑤ Excavation of caries and Restoration ☐ 28, 45, 47, 17, 36, 37, 47.
⑥ Suggest orthodontic treatment.

Phase II :

–

Phase III:

–

Phase IV:

Class B - 3-4 months

INDICES

1. Simplified Oral Hygiene Index (Greene & Vermillion 1964):

DI-S

16	11	26
1	0	1
1	0	1
46	31	36

CI-S

16	11	26
1	2	1
1	2	1
46	31	36

OHIS Score Per Person:

DI-S = 0.66

CI-S = 1.99.

Oral Hygiene Status : Good / Fair / Poor

2. Plaque Index (Turesky- Gilmore Glickman, 1970)

☒☒☒☒☒☒☒☒ ☒☒☒☒☒☒☒☒
☒☒☒☒☒☒☒☒ ☒☒☒☒☒☒☒☒

Plaque Score Per Person :

3. Gingival Index (Loe and Silness 1963)

☒☒☒☒☒☒☒☒ ☒☒☒☒☒☒☒☒
☒☒☒☒☒☒☒☒ ☒☒☒☒☒☒☒☒

Gingival Score Per Person :

CASE HISTORY

Sr. No.: 4

Year : 2022-23, Final Year.

Patient's Name : Miss Nikita Chowdhari.

O.P.D. No.: 116400

Age : 20 years.

Date : 14/1/23.

Sex : Female

Occupation : Student.

Address: Charholi Bk, Pune.

Income: -

Chief Complaint : Patient complains of uncleaned teeth since 3-4 months.

History of present illness : Patient was apparently asymptomatic 2-3 months back when she started experiencing whitish yellow hard deposits on tooth surface that gradually increased over 3 months.

Past Dental History :

No relevant history.

Past Medical History :

No relevant history.

Family History :

No relevant history.

Personal History:

Mixed Diet.

Oral hygiene habits: ① Uses Toothbrush and Toothpaste
② Brushes are a day in the morning.
③ Technique - Horizontal.

Other habits :

Bruxism.

Extra Oral Examination :

Symmetry of face :

No gross asymmetry detected.

Lips:

Competent.

Lymph Nodes :

Non-palpable, Non-tender

T.M.Joint: No clicking sound.
No deviation seen.

Intra Oral Examination :

Halitosis:

No abnormality detected.

Oral Mucous Membrane :

No abnormality detected.

Tongeue:

No abnormality detected.

Palate:

No abnormality detected.

Gingiva :

	Region	Colour	Contour	Consistency	Surface Texture	Size	Bleeding On Probing	Exudation
MAXILLARY	Anterior	Pink with pigmentation	Scalloped & knife edged.	Firm and resilient	Stippling present.	Normal	Present	Absent.
	Posterior	Pink with melanin pigmentation	Scalloped & knife edged	Firm and resilient	Stippling present.	Normal	Present	Absent.
MANDIBULAR	Anterior	Pink with pigmentation	Scalloped & knife edged.	Firm and resilient	stippling present	Normal	Present	Absent.
	Posterior	Pink with pigmentation	Scalloped & knife edged	Firm and resilient.	Stippling present	Normal	Present	Absent.

Mucogingival Problems : Absent.

Frenal Attachment :

Upper : Gingival

Lower : Gingival

Width of attached Gingiva : **Adequate/Inadequate** ✓

Tension Test Positive

Periodontal Pockets :

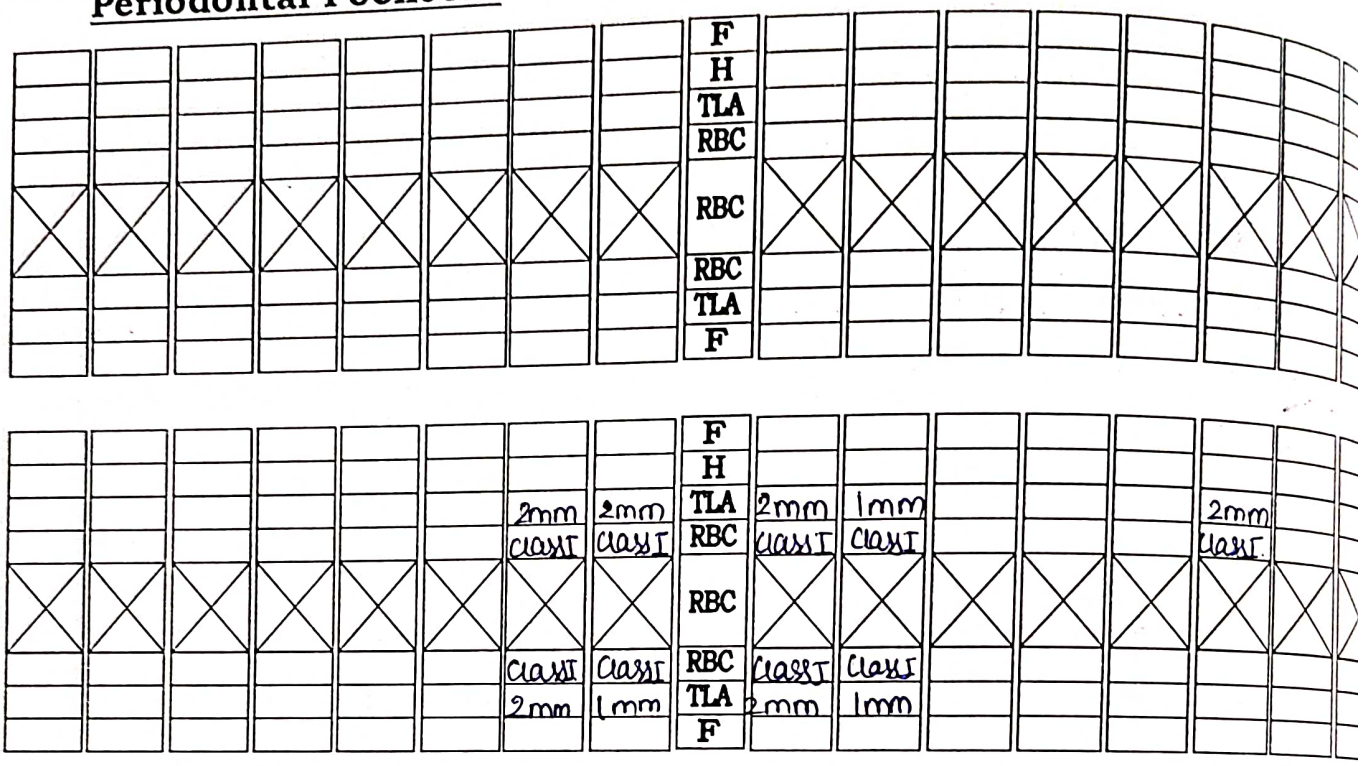

F- Furcation Involvement,

M- Mobility

TLA- Total loss of attachment,

REC- Recession,

PKT-Pocket

Examination of Teeth :

Teeth Present ; 7 6 5 4 3 2 1 | 1 2 3 4 5 6 7
8 7 5 4 3 2 1 | 1 2 3 4 5 6 7

Wasting Diseases : **Attrition** / **Abrasion** /**Erosion**

(3 / 321 \ 13 / 123) ( ) ( )

Carious Teeth : ① Pit and fissure caries ⊂ 47, 48, 17.
② Deep occlusal caries ⊂ 36 [TOP +ve]

Restored Teeth: Absent

Faulty Restoration : Absent

Pathologic Migration: Absent.

Drifting : Absent

Proximal Contacts : Tight

Food Impaction : Absent

Occlusion : class I

Fremitus Test : Negative

Teeth Deposits : **Plaque :** + **Calculus** ++ **Stains**

Hypersensitivity: Present

Etiological Factors :

Local :

Primary : Plaque

Secondary : Calculus, Faulty Brushing Technique.

Systemic : Absent.

Investigations :

Laboratory :

BT, CT, PT-INR, PTT

Radiographic :

JOPA $\overline{c}$ 36

CBCT $\overline{c}$ $\frac{}{6|}$

Diagnosis :

Chronic generalized marginal gingivitis with chronic localized periodontitis $\overline{c}$ $\frac{|}{21|126}$

Prognosis :

Overall:

Fair

Individual:

Fair.

Treatment Plan

Preliminary/ Emergency Treatment ;

Phase I :

① Diet counselling - Reduce sugar intake
② Full mouth scaling advised and root planing.
③ Improved Brushing Technique - Modified stillman's technique.
④ Mechanical Plaque control - Flossing advised.
⑤ chemical Plaque control - 0.2% Chlorhexidine
⑥ Orthodontic Treatment Night guard.
⑦ Amalgam Restoration $\overline{C}\,\frac{7|}{87}$
⑧ Desensitizing toothpaste advised.

Phase II :

① Implant surgery $\overline{C}\,\frac{}{6|}$
② Root Coverage Procedure.

Phase III:

RCT $\overline{C}\,\frac{}{|6}$, followed by prosthesis [S.S. Crown]

Phase IV:

Class B - 3-4 months.

INDICES

1. Simplified Oral Hygiene Index (Greene & Vermillion 1964):

DI-S

16	11	26
2	1	2
2	1	2
46	31	36

CI-S

16	11	26
3	2	3
3	2	3
46	31	36

OHIS Score Per Person:

1.66 + 2.66

= 4.66.

Oral Hygiene Status : Good / Fair / ✓ Poor

2. Plaque Index (Turesky- Gilmore Glickman, 1970)

☒☒☒☒☒☒☒☒ ☒☒☒☒☒☒☒☒
☒☒☒☒☒☒☒☒ ☒☒☒☒☒☒☒☒

Plaque Score Per Person :

3. Gingival Index (Loe and Silness 1963)

☒☒☒☒☒☒☒☒ ☒☒☒☒☒☒☒☒
☒☒☒☒☒☒☒☒ ☒☒☒☒☒☒☒☒

Gingival Score Per Person :

3rd IInd.

CASE HISTORY

Sr. No.: 5

Year : 2022 -23.

Patient's Name : Mr. Krishna Sambhaji Padule.

O.P.D. No.: 117053.

Age : 21 year.

Date : 21/1/23.

Sex : Male.

Occupation : Student.

Address: Nimbalkar Nagar, Lohegaon.

Income: –

Chief Complaint :

Patient complains of unclean teeth since 5-6 months.

History of present illness :

Patient was apparently asymptomatic 5-6 months ago when he started experiencing white hard deposits on the teeth which increased gradually.

Past Dental History :

No relevant history.

Past Medical History :

No relevant history

Family History :

No relevant history

Personal History:

Vegetarian diet.

Oral hygiene habits: ① Toothbrush and Toothpaste
② Morning only
③ Horizontal brushing

Other habits :

No relevant history

Extra Oral Examination :

Symmetry of face : No gross asymmetry detected.

Lips: Competent

Lymph Nodes : } No abnormality detected.

T.M.Joint:

Intra Oral Examination :

Halitosis: } No abnormality detected

Oral Mucous Membrane :

Tongeue:

Palate:

Gingiva :

	Region	Colour	Contour	Consistency	Surface Texture	Size	Bleeding On Probing	Exudation
MAXILLARY	Anterior	Pink with pigmentation	Scalloped and knife edged.	Firm and resilient	Stippling present	Normal	Absent	Absent
	Posterior	Pink with pigmentation	Scalloped and knife edged.	Firm and resilient	Stippling present	Normal	Absent	Absent
MANDIBULAR	Anterior	Pink with pigmentation	Scalloped and knife edged.	Firm and resilient	Stippling present	Normal	Present	Absent
	Posterior	Pink with pigmentation	Scalloped & knife edged.	Firm and resilient.	Stippling present	Normal.	Absent	Absent.

Mucogingival Problems :

-

Frenal Attachment :

Upper : Gingival

Lower : Gingival

Width of attached Gingiva : ✓ **Adequate/Inadequate**

Tension Test Negative

Periodontal Pockets :

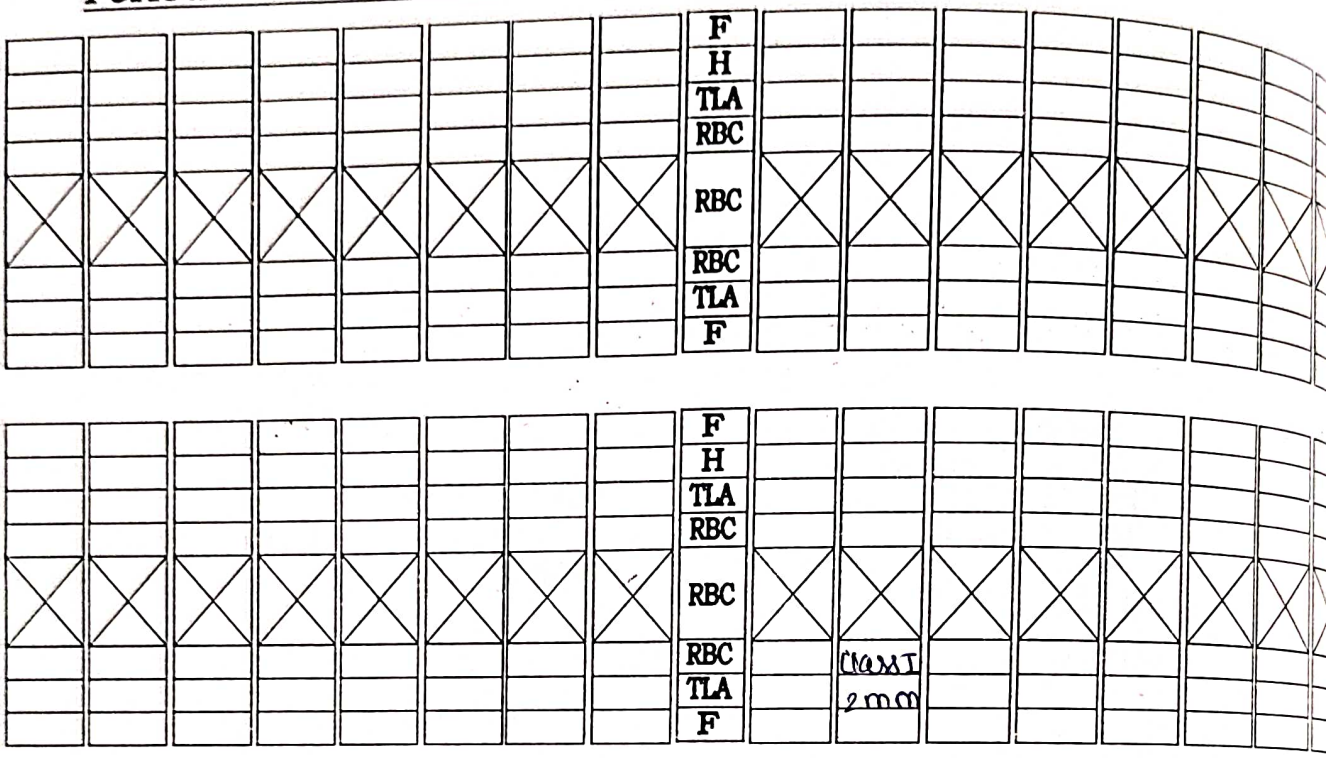

F- Furcation Involvement,

M- Mobility

TLA- Total loss of attachment,

REC- Recession,

PKT-Pocket

Examination of Teeth :

Teeth Present ;

8 7 6 5 4 3 2 1	1 2 3 4 5 6 7
8 7 6 5 4 3 2 1	1 2 3 4 5 6 7 8

Wasting Diseases : **Attrition / Abrasion /Erosion**

(+/-) (-) (-)

Carious Teeth : Absent.

Restored Teeth: Absent.

Faulty Restoration : Absent.

Pathologic Migration: Absent

Drifting : Absent.

Proximal Contacts : Present.

Food Impaction : Absent.

Occlusion : Angle's Class I malocclusion.

Fremitus Test : Positive.

Teeth Deposits : **Plaque :** + **Calculus** ++ **Stains** +

Hypersensitivity: Absent

Etiological Factors :

Local :

Primary : Plaque.

Secondary : Calculus, Faulty tooth brushing.

Systemic : Absent.

Investigations :

Laboratory :

→

Radiographic :

IOPA $\bar{c}$ 76

Diagnosis :

Chronic localized periodontitis $\bar{c}$ 2.

Prognosis :

Overall:

Good

Individual:

Good

Treatment Plan

Preliminary/ Emergency Treatment ;

Phase I : Non-Surgical

1) Scaling and root planing
2) Mechanical aids
   Improve brushing technique - Modified stillman's technique.
3) Chemical aids - Mouthwas 0.12% chlorhexidine.
4) Occlusal reshaping - Orthodontic treatment [Trauma from occlusion is present]

Phase II :

Surgical

Root coverage procedure $\overline{c}$ $\frac{+}{2}$

Phase III:

Restorative

Composite restoration $\overline{c}$ $\frac{+}{76 \mid 67}$

Phase IV:

Maintenance

class A - 6months.

INDICES

1. Simplified Oral Hygiene Index (Greene & Vermillion 1964):

DI-S		

CI-S		

OHIS Score Per Person:

Oral Hygiene Status : Good / Fair / Poor

2. Plaque Index (Turesky- Gilmore Glickman, 1970)

☒☒☒☒☒☒☒☒ ☒☒☒☒☒☒☒☒
☒☒☒☒☒☒☒☒ ☒☒☒☒☒☒☒☒

Plaque Score Per Person :

3. Gingival Index (Loe and Silness 1963)

☒☒☒☒☒☒☒☒ ☒☒☒☒☒☒☒☒
☒☒☒☒☒☒☒☒ ☒☒☒☒☒☒☒☒

Gingival Score Per Person :

4th 1st.

CASE HISTORY

Sr. No.: 6. **Year :** 2022-23.

Patient's Name : Mr. Vipul Chavan. **O.P.D. No.:** 11188

Age : 18 years. **Date :** 24/1/23.

Sex : Male **Occupation :** Student.

Address: Dios living, Kohegaon, Pune. **Income:** —

Chief Complaint :

Patient complains of unclean teeth since 1 year.

History of present illness :

Patient was apparently asymptomatic 1 year ago. Then the patient started experiencing white hard deposits which gradually increased over a year.

Past Dental History :

No relevant history

Past Medical History :

Asthma since birth. Use asthma pump [salbutamol inhalation]

Family History :

Patient's father has the history of diabetes and blood pressure/ hypertension since 5 years.

Personal History:

Diet - Mixed diet.

Oral hygiene habits: ① Toothpaste and Toothbrush.
② Vertical and horizontal brushing
③ Once in the morning.

Other habits :

No relevant history.

Extra Oral Examination :

Symmetry of face : No gross asymmetry detected.

Lips:

Lymph Nodes : } No abnormality detected.

T.M.Joint:

Intra Oral Examination :

Halitosis: Morning physiological halitosis present and when the patient's mouth is kept close for a longer duration.

Oral Mucous Membrane :

Tongeue: } No abnormality detected.

Palate:

Gingiva :

	Region	Colour	Contour	Consistency	Surface Texture	Size	Bleeding On Probing	Exudation
MAXILLARY	Anterior	Pink with melanin pigment-ation	Scalloped and knife edged	Firm and resilient	Stippling present	Nor-mal	Present	Absent
	Posterior	Pink with melanin pigmen-tation	Scalloped and knife edged	Firm and resilient	Stippling present	Nor-mal	Present	Absent
MANDIBULAR	Anterior	Pink with melanin pigmen-tation	Scalloped and knife edged	Firm and resilient	Stippling present	Nor-mal	Present	Absent
	Posterior	Pink with melanin pigmen-tation.	Scalloped and knife edged.	Firm and resilient	Stippling present	Nor-mal	Present	Absent

Mucogingival Problems :

—

Frenal Attachment :

Upper : Gingival

Lower : Gingival

Width of attached Gingiva : ✓ **Adequate/Inadequate**

Tension Test Positive [man]

Periodontal Pockets :

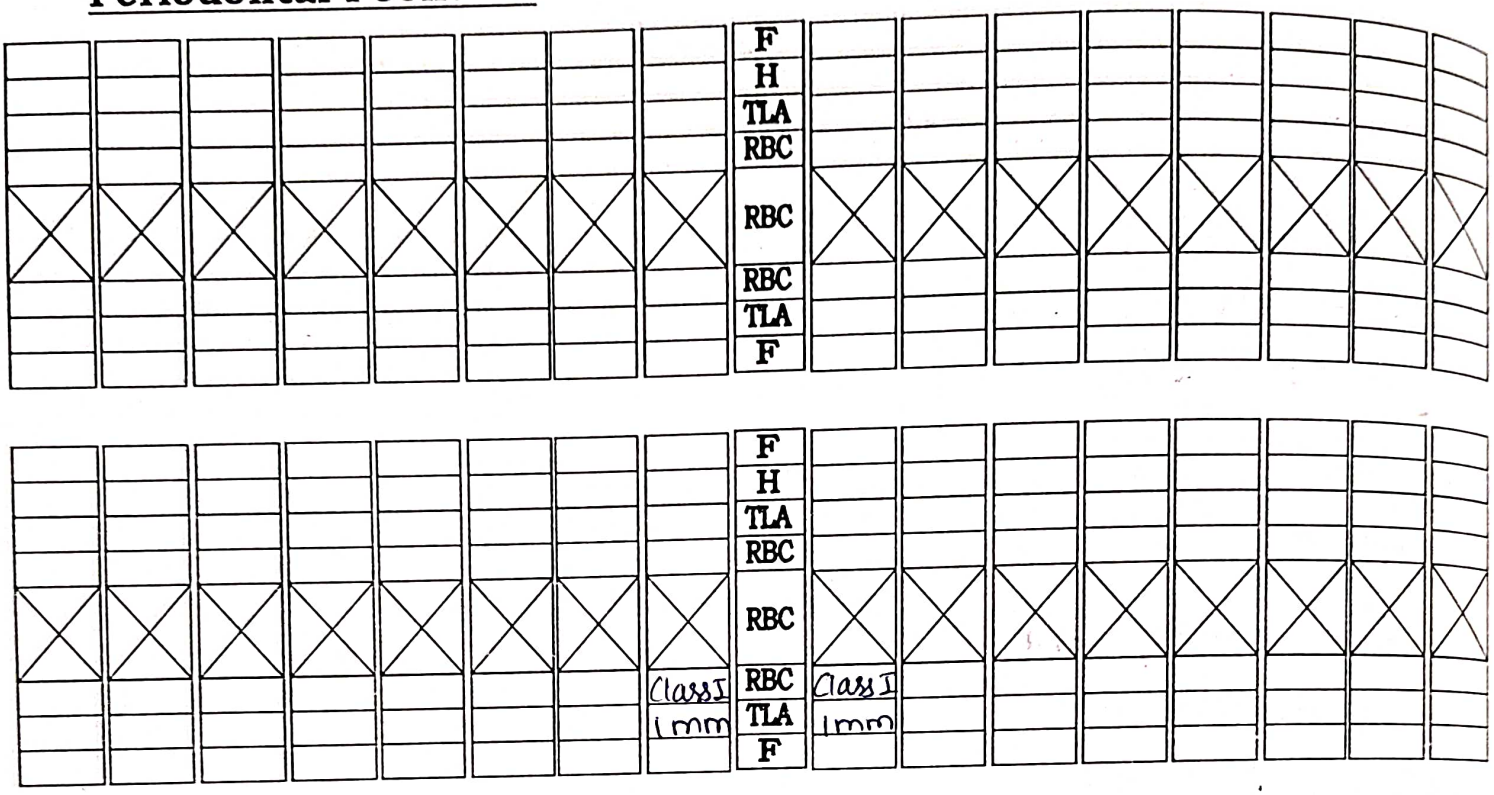

F- Furcation Involvement,

M- Mobility

TLA- Total loss of attachment,

REC- Recession,

PKT-Pocket

Examination of Teeth :

Teeth Present ;

7 6 5 4 3 2 1	1 2 3 4 5 6 7
7 6 5 4 3 2 1	1 2 3 4 5 6 7

Wasting Diseases : **Attrition** / **Abrasion** /**Erosion**

(31, 32) (-) (-)

Carious Teeth : Absent

Restored Teeth: Absent

Faulty Restoration : Absent.

Pathologic Migration: Absent

Drifting : Absent

Proximal Contacts : Tight

Food Impaction : Absent.

Occlusion : Angle's class I malocclusion [left and right side] Crowding with posterior maxillary region.

Fremitus Test : Positive.

Teeth Deposits : **Plaque :** + **Calculus** ++ **Stains** +

Hypersensitivity: Present.

Etiological Factors :

Local :

Primary : Plaque.

Secondary : Calculus, Faulty Tooth brushing

Systemic :

Asthma.

Investigations :

Laboratory :

Allergies towards medications / dust.

Radiographic :

OPG

Diagnosis :

Chronic generalized marginal gingivitis with chronic localized periodontitis $\bar{c}$

Prognosis :

Overall:

Good.

Individual:

Good.

Treatment Plan

Preliminary/ Emergency Treatment ;

Non - surgical

Phase I : 1] Ask patient to carry inhalor whenever he comes for treatment.

2] Scaling and root planing.

3] Mechanical aids - ① Thermo seal ~~tooth~~ paste - To treat hypersensitivity

② Improve tooth brushing - Modified stillman's technique.

③ Flossing advised.

4] chemical aids - 0.2% chlorhexidine Mouthwash advised.

5] Orthodontic treatment required.

Phase II :

surgical

① Root coverage procedure c̄ 1|1

② Frenectomy (mandibular arch]

Phase III:

Restorative.

Phase IV:

Class A - 6 months later.

INDICES

1. Simplified Oral Hygiene Index (Greene & Vermillion 1964):

DI-S		

CI-S		

OHIS Score Per Person:

Oral Hygiene Status : Good / Fair / Poor

2. Plaque Index (Turesky- Gilmore Glickman, 1970)

☒☒☒☒☒☒☒☒ ☒☒☒☒☒☒☒☒
☒☒☒☒☒☒☒☒ ☒☒☒☒☒☒☒☒

Plaque Score Per Person :

3. Gingival Index (Loe and Silness 1963)

☒☒☒☒☒☒☒☒ ☒☒☒☒☒☒☒☒
☒☒☒☒☒☒☒☒ ☒☒☒☒☒☒☒☒

Gingival Score Per Person :

CASE HISTORY

Sr. No.: 7.

Year :

Patient's Name : Mrs Nirmala Gaikwad

O.P.D. No.: 108584

Age : 33 years.

Date : 10/5/23

Sex : Female.

Occupation : Housewife.

Address: Kalwad wasti, Pune.

Income: –

Chief Complaint : Patient complains of uncleaned teeth since last 6-7 months.

History of present illness : Patient was apparently asymptomatic 6-7 months back when she started experiencing white soft deposits on tooth surface that gradually increased over 7 months

Past Dental History :

No relevant history

Past Medical History :

No relevant history.

Family History :

No relevant history

Personal History:

Mixed diet.

Oral hygiene habits:

① Uses toothbrush and toothpaste
② Brushes once a day in morning
③ Technique → Horizontal circular

Other habits :

No relevant history

Extra Oral Examination :

Symmetry of face : No gross asymmetry detected.

Lips:

Competent.

Lymph Nodes :

Non-palpable, Non-Tender

T.M.Joint:

No deviation is seen.

Intra Oral Examination :

Halitosis:

No relevant history.

Oral Mucous Membrane :

Tongeue:

Palate:

No abnormality detected.

Gingiva :

	Region	Colour	Contour	Consistency	Surface Texture	Size	Bleeding On Probing	Exudation
MAXILLARY	Anterior	Pink with melanin pigmentation	Scalloped and knife edged.	Firm and resilient	Stippling present	Normal	Present	Absent
	Posterior	Pink with melanin pigmentation	Scalloped & knife edged.	Firm and resilient	Stippling present	Normal	Present	Absent
MANDIBULAR	Anterior	Pink with melanin pigmentation	Scalloped and knife edged	Firm and resilient	Stippling present	Normal	Present	Absent
	Posterior	Pink with melanin pigmentation	Scalloped and knife edged.	Firm and resilient	Stippling present.	Normal.	Present	Absent.

Mucogingival Problems :

–

Frenal Attachment :

Upper : Gingival

Lower : Gingival

Width of attached Gingiva : ✓ **Adequate/Inadequate**

Tension Test Negative.

Periodontal Pockets : No abnormality detected.

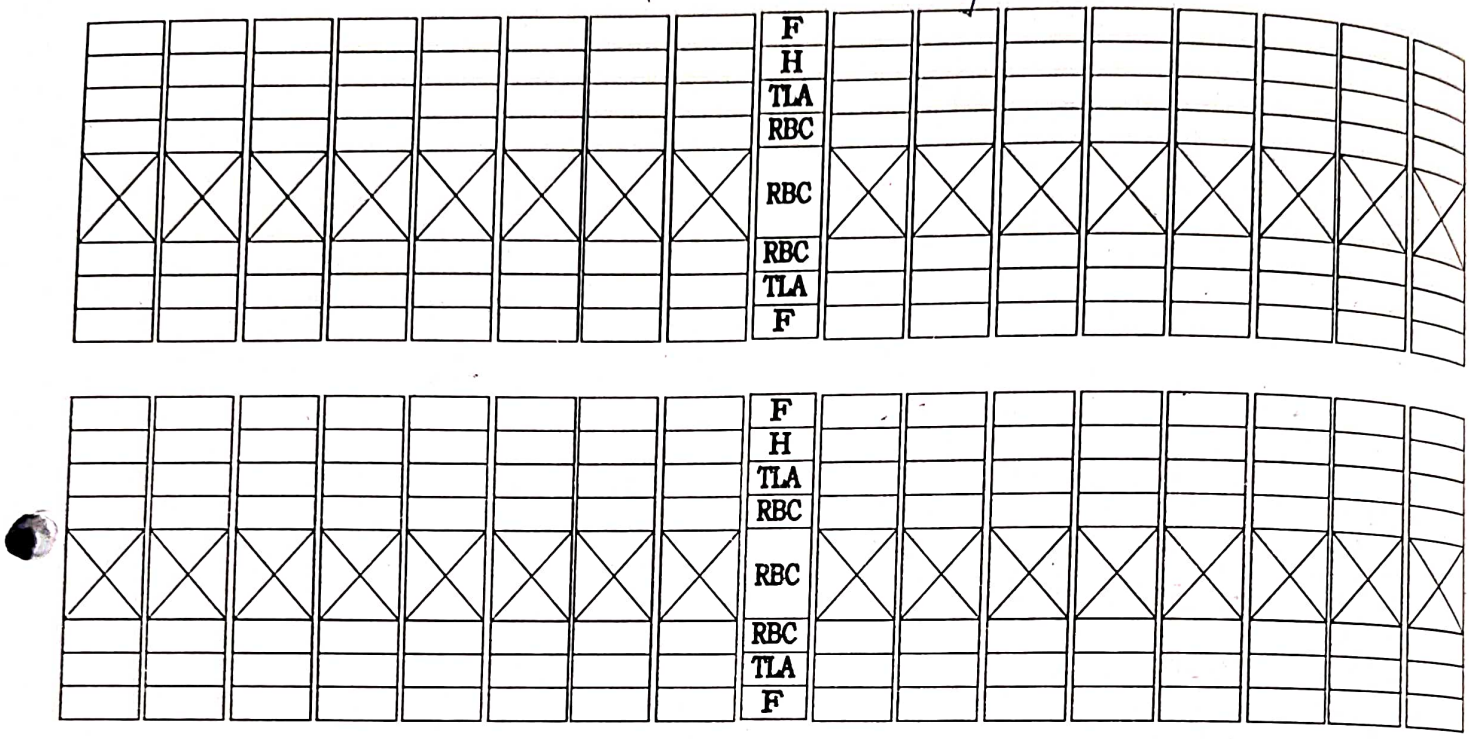

F- Furcation Involvement,

M- Mobility

TLA- Total loss of attachment,

REC- Recession,

PKT-Pocket

Examination of Teeth :

Teeth Present ; 7 6 5 4 3 2 1 | 1 2 3 4 5 6 7
7 6 5 4 3 2 1 | 1 2 3 4 5 6 7

Wasting Diseases : **Attrition** / **Abrasion** /**Erosion**

(–) (–) (–)

Carious Teeth : Absent

Restored Teeth: Absent

Faulty Restoration : Absent

Pathologic Migration: Absent

Drifting : Absent

Proximal Contacts : Tight

Food Impaction : Absent

Occlusion : Class I malocclusion [Anterior crowding present in maxillary and mandibular arch].

Fremitus Test :

Teeth Deposits : **Plaque :** + **Calculus** + **Stains** +

Hypersensitivity: Absent.

Etiological Factors :

Local :

Primary : Plaque

Secondary : Calculus, faulty tooth brushing technique

Systemic : Absent

Investigations :

—

Laboratory :

—

Radiographic :

—

Diagnosis :

Chronic generalized marginal gingivitis

Prognosis :

Overall:

Fair

Individual:

Fair.

Treatment Plan

Preliminary/ Emergency Treatment ;

Phase I :

1. Full mouth scaling advised
2. Improved brushing technique - Modified bass technique.
3. Mechanical plaque control - Flossing advised.
4. Chemical plaque control - 0.2% Chlorhexidine mouthwash
5. Suggest orthodontic treatment.

Phase II :

–

Phase III:

–

Phase IV:

–

INDICES

1. Simplified Oral Hygiene Index (Greene & Vermillion 1964):

DI-S		

CI-S		

OHIS Score Per Person:

Oral Hygiene Status : Good / Fair / Poor

2. Plaque Index (Turesky- Gilmore Glickman, 1970)

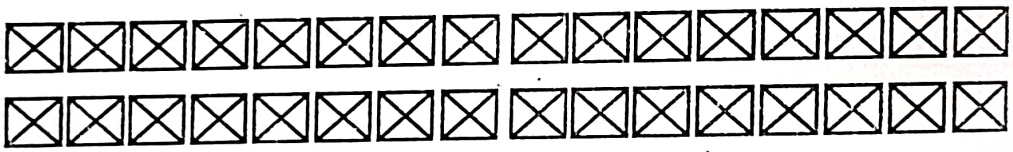

Plaque Score Per Person :

3. Gingival Index (Loe and Silness 1963)

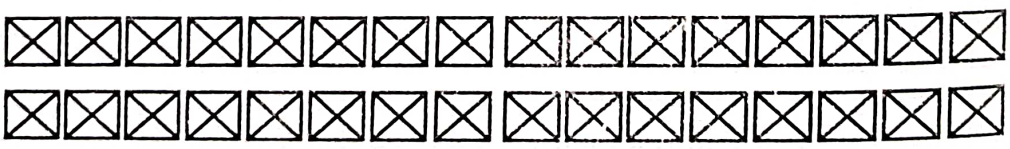

Gingival Score Per Person :

CASE HISTORY

Sr. No.: 8

Year :

Patient's Name : Mr. Janak Pawar.

O.P.D. No.: 126596

Age : 27 years

Date : 13/5/23.

Sex : Male

Occupation : Service

Address: Pune.

Income: 3-4 lakh.

Chief Complaint :

Patient complains of uncleaned teeth 2-3 months.

History of present illness :

Patient was apparently asymptomatic ~~2-3~~ months ago. Later he started experiencing brown discoloration of teeth and white soft deposits on tooth surface that gradually increases over 4 months.

Past Dental History :

No relevant history

Past Medical History :

No relevant history

Family History :

No relevant history

Personal History:

Mixed diet

Oral hygiene habits: [hard] [colgate]

① Uses tooth brush and tooth paste
② Brushes once a day in morning.
③ Technique - Horizontal.

Other habits :

No relevant history.

Extra Oral Examination :

No abnormality detected.

Symmetry of face :

No gross asymmetry detected.

Lips:

Competent

Lymph Nodes :

Non-palpable, non-tender.

T.M.Joint:

No clicking sound.
No deviation is seen.

Intra Oral Examination :

Halitosis:

No abnormality detected.

Oral Mucous Membrane :

Tongeue: } No abnormality detected.

Palate:

Gingiva :

	Region	Colour	Contour	Consistency	Surface Texture	Size	Bleeding On Probing	Exudation
MAXILLARY	Anterior	Pink with melanin pigmentation	Scalloped & knife edged	Firm and resilient	Stippling present	Normal	Absent	Absent
	Posterior	Pink with melanin pigmentation.	Scalloped & knife edged	Firm and resilient	Stippling present	Normal	Absent	Absent
MANDIBULAR	Anterior	Pink with melanin pigmentation	Scalloped & knife edged	Firm and resilient	Stippling present	Normal	Absent	Absent
	Posterior	Pink with melanin pigmentation	Scalloped & knife edged.	Firm and resilient.	Stippling present	Normal	Absent	Absent.

Mucogingival Problems :

–

Frenal Attachment :

Upper : Gingival

Lower : Gingival.

Width of attached Gingiva : **Adequate/Inadequate** ✓

Tension Test Negative

Periodontal Pockets :

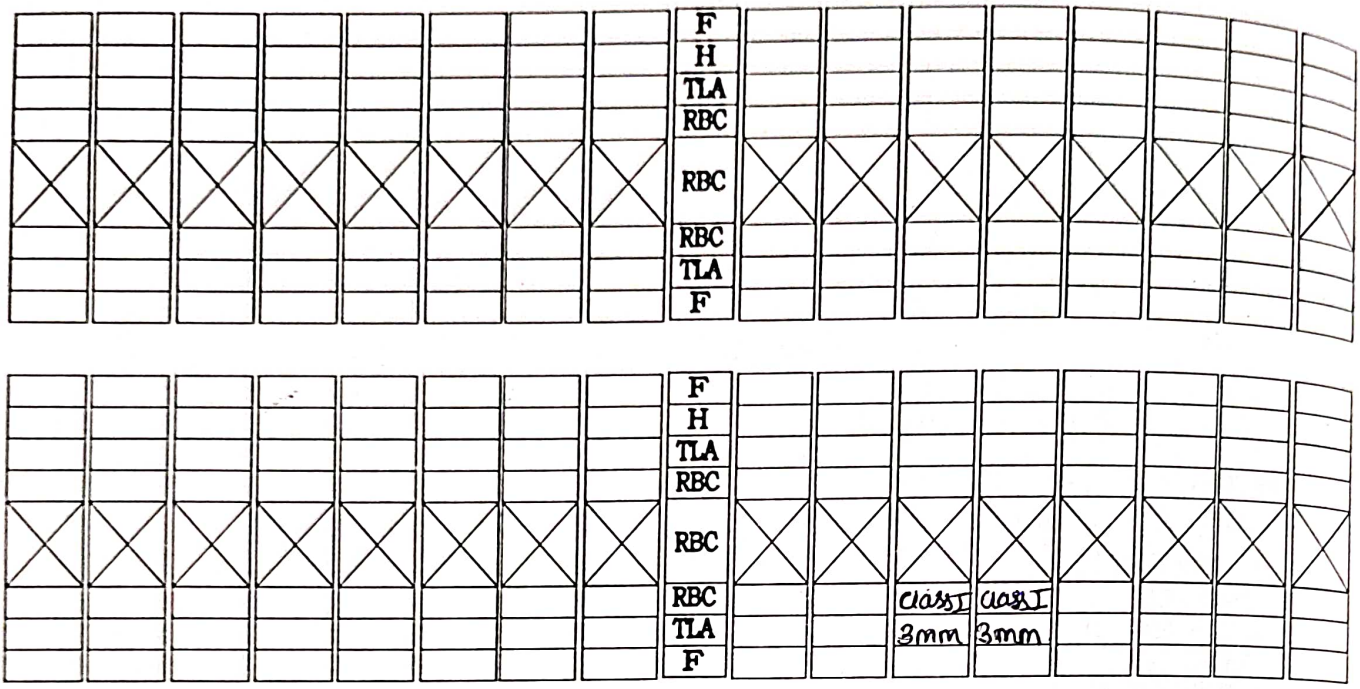

F- Furcation Involvement,

M- Mobility

TLA- Total loss of attachment,

REC- Recession,

PKT-Pocket

Examination of Teeth :

Teeth Present ;

76 54 3 21	12 34 567
7654 3 21	1234 567

Wasting Diseases : **Attrition** / **Abrasion** /**Erosion**

(-) (-) (-)

Carious Teeth : Pit and fissure caries ∈ 46 , 16.

Restored Teeth: Absent

Faulty Restoration : Absent

Pathologic Migration: Absent

Drifting : Absent

Proximal Contacts : Tight

Food Impaction : Absent

Occlusion : Class I malocclusion.

Fremitus Test : Absent

Teeth Deposits : **Plaque :** + **Calculus** + **Stains** +

Hypersensitivity: Absent

Etiological Factors :

Local :

Primary :

Plaque

Secondary :

stains, calculus

Systemic :

Absent

Investigations :

-

Laboratory :

-

Radiographic :

-

Diagnosis :

Chronic localized periodontitis $\bar{c}$ $\frac{1}{34}$.

Prognosis :

15/5/23

Overall:

Good

Individual:

Good.

Treatment Plan

Preliminary/ Emergency Treatment ;

Phase I : Non-Surgical. phase

1. Diet counselling
2. Full mouth scaling advised.
3. Improved. brushing technique - Modified stillman technique.
4. Mechanical plaque control - 0.2 % chlorhexidine.

Phase II :

Surgical phase

Root coverage procedure $\bar{c}$ $\frac{|}{34}$.

Phase III:

Restorative. phase

Composite restoration $\bar{c}$ 46, 16.

Phase IV:

Maintenance phase

Class B - 3-4 months.

INDICES

1. Simplified Oral Hygiene Index (Greene & Vermillion 1964):

DI-S

16	11	26
1	0	1
1	0	1
46	31	36

CI-S

16	11	26
0	1	0
0	1	0
46	31	36

OHIS Score Per Person: DI-S + CI-S

0,6 + 0,3 = 0,9

Oral Hygiene Status : Good ✓ / Fair / Poor

2. Plaque Index (Turesky- Gilmore Glickman, 1970)

☒☒☒☒☒☒☒☒☒☒☒☒☒☒☒☒

☒☒☒☒☒☒☒☒☒☒☒☒☒☒☒☒

Plaque Score Per Person :

3. Gingival Index (Loe and Silness 1963)

☒☒☒☒☒☒☒☒☒☒☒☒☒☒☒☒

☒☒☒☒☒☒☒☒☒☒☒☒☒☒☒☒

Gingival Score Per Person :

CASE HISTORY

Sr. No.: 9

Patient's Name : Miss Priya Ukirde

Age : 21 years.

Sex : Female

Address: Kohegaon, Pune.

Year :

O.P.D. No.: 11345

Date : 13/5/23.

Occupation : Student

Income: –

Chief Complaint :

Patient complains of undean teeth since 3-4 months.

History of present illness :

Patient was apparently asymptomatic 3-4 months ago. Later patient started experiencing white hard deposits on the tooth surface which gradually increased over time.

Past Dental History :

No relevant history.

Past Medical History :

No relevant history

Family History :

No relevant history.

13/05/23

Personal History:

Mixed diet.

Oral hygiene habits:

1 time brushing → Morning [Horizontal]

Other habits :

No relevant history.

Extra Oral Examination :

Symmetry of face :

No gross asymmetry detected.

Lips:

Competent

Lymph Nodes :

T.M.Joint:

} No abnormality detected.

Intra Oral Examination :

Halitosis:

Present - Physiological.

Oral Mucous Membrane :

Tongeue:

Palate:

} No abnormality detected

Gingiva :

	Region	Colour	Contour	Consistency	Surface Texture	Size	Bleeding On Probing	Exudation
MAXILLARY	Anterior	Pink with brownish black pigmentation.	Scalloped and knife edged	Firm and resilient	Stippling present	Normal	Absent	Absent
	Posterior	Pink with brownish black pigmentation	Scalloped and knife edged	Firm and resilient	Stippling present	Normal	Absent	Absent
MANDIBULAR	Anterior	Pink with brownish black pigmentation	Scalloped & knife edged	Firm and resilient	Stippling present	Normal	Present	Absent
	Posterior	Pink with brownish black pigmentation.	Scalloped and knife edged.	Firm and resilient	Stippling present	Normal.	Absent.	Absent

Mucogingival Problems :

Absent

Frenal Attachment :

Upper : Gingival

Lower : Gingival

Width of attached Gingiva : ✓ **Adequate/Inadequate**

Tension Test Negative.

Periodontal Pockets :

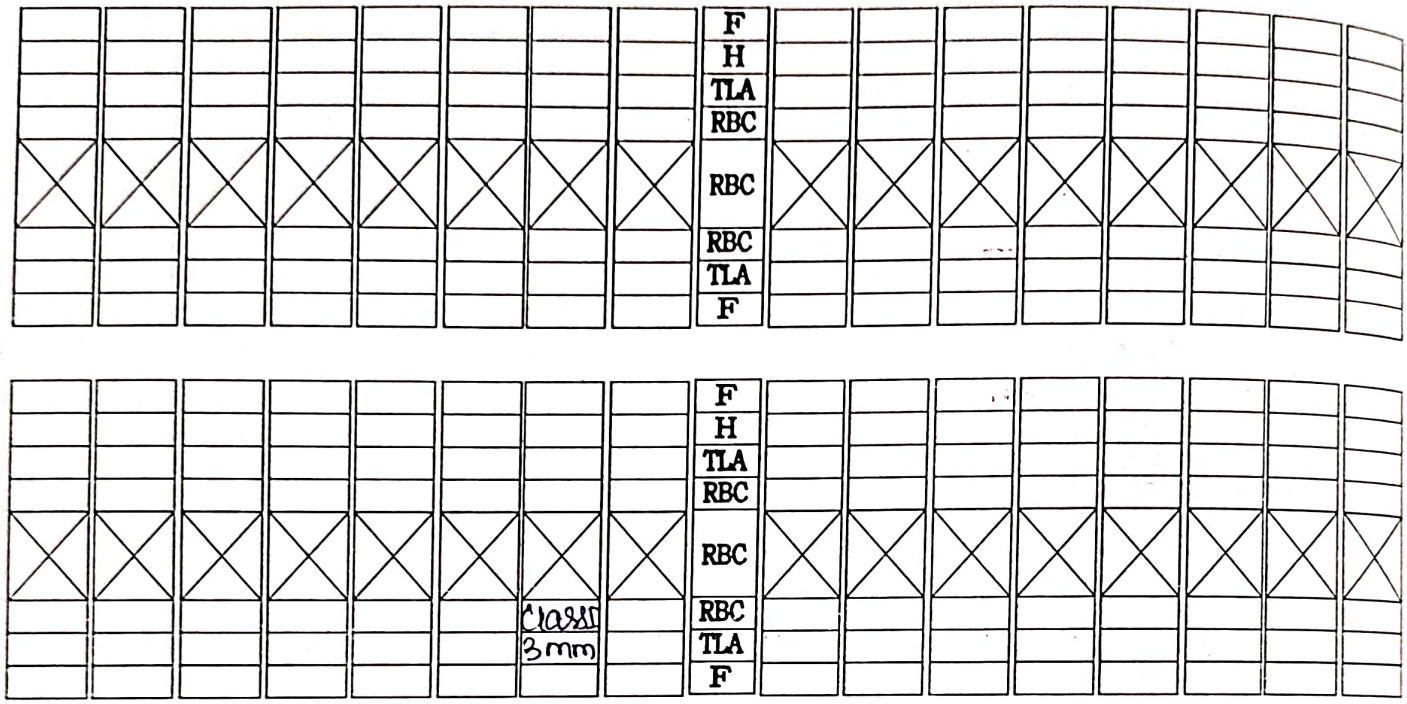

F- Furcation Involvement,

M- Mobility

TLA- Total loss of attachment,

REC- Recession,

PKT-Pocket

Examination of Teeth :

Teeth Present ;

7 6 5 4 3 2 1	1 2 3 4 5 6 7
7 6 5 4 3 2 1	1 2 3 4 5 6 7

Wasting Diseases : **Attrition / Abrasion /Erosion**

(321 \| 123) ( ) ( )

Carious Teeth : ① Deep occlusal caries ⊼ 36
② Pit and fissure caries ⊼ 46, 47, 17.

Restored Teeth: ③ Occlusal facet ⊼ 46, 16.

Faulty Restoration : Absent.

Pathologic Migration: Absent

Drifting : Absent

Proximal Contacts : Tight.

Food Impaction : Absent

Occlusion : Angle's class I malocclusion ⊼ left and right.

Fremitus Test : Positive. [Trauma from occlusion is present].

Teeth Deposits : **Plaque :** + **Calculus** ++ **Stains** +

Hypersensitivity: Absent.

Etiological Factors :

Local :

Primary : Plaque

Secondary : Stains, calculus, Faulty brushing

Systemic :

Absent.

Investigations :

Laboratory :

—

Radiographic :

IOPA ⏜ 36

Diagnosis :

Chronic generalized marginal gingivitis ⏜
Chronic localized periodontitis ⏜ 2/

Prognosis :

Overall:

Poor

Individual:

Poor

Treatment Plan

Preliminary/ Emergency Treatment ;

Phase I : Non-surgical

1] Diet education.
2] Full mouth scaling and root planing advised.
3] Improve brushing technique - Modified stillman's technique.
4] Mechanical Plaque control - Flossing advised.
5] Chemical Plaque control - 0.12% chlorhexidine.
6] Caries excavation and restoration ☐ 46, 47, 17
7] Orthodontic treatment suggested [Trauma from occlusion is present]

Phase II : 8] Desensitizing toothpaste advised

Surgical

RCT ☐ 36 followed by crown placement.
Root coverage procedure ☐ ⏚

Phase III:

Restorative

Composite restoration ☐ 46, 16.

Phase IV:

Maintenance

Class B - 3-4 months.

INDICES

1. Simplified Oral Hygiene Index (Greene & Vermillion 1964):

DI-S

16	11	26
2	1	3
3	2	3
46	31	36

CI-S

16	11	26
2	2	3
2	3	3
46	31	36

OHIS Score Per Person: DI-S + CI-S

= 2.33 + 2.5

= 4.83

Oral Hygiene Status : Good / Fair / ✓ Poor

2. Plaque Index (Turesky- Gilmore Glickman, 1970)

☒☒☒☒☒☒☒☒ ☒☒☒☒☒☒☒☒

☒☒☒☒☒☒☒☒ ☒☒☒☒☒☒☒☒

Plaque Score Per Person :

3. Gingival Index (Loe and Silness 1963)

☒☒☒☒☒☒☒☒ ☒☒☒☒☒☒☒☒

☒☒☒☒☒☒☒☒ ☒☒☒☒☒☒☒☒

Gingival Score Per Person :

CASE HISTORY

4th IInd.

Sr. No.: 10.

Year :

Patient's Name : Mrs Pooja Sanjay Lohar.

O.P.D. No.:

Age : 22 years.

Date : 20/5/23.

Sex : Female.

Occupation : Housewife.

Address: Charoli, Pune.

Income: —

Chief Complaint :

Patient complains of unclean teeth since 1 month.

History of present illness :

Patient was apparently asymptomatic 1 month ago. Later patient started experiencing white hard deposits on lingual surfaces of teeth which gradually increased over time.

Past Dental History :

Ultrasonic scaling done 6 months back.
No complications occured.

Past Medical History :

No relevant history

Family History :

Patients Mother-In-Law has diabetes and is on medication for the same.

Personal History:

Diet - Vegetarian diet.

Oral hygiene habits:

No relevant history

Other habits : Tooth brush [Soft] and Toothpaste [Colgate]
2 times a day
Horizontal Brushing.

Extra Oral Examination :

Symmetry of face : No gross asymmetry detected.

Lips: Competent.

TMJ Joint :
No clicking heard, No deviation seen.

Lymph Nodes:
Not paypable.

Intra Oral Examination :

Halitosis:

Oral Mucous Membrane :

Tongeue:

Palate:

} No abnormality detected.

Gingiva :

	Region	Colour	Contour	Consistency	Surface Texture	Size	Bleeding On Probing	Exudation
MAXILLARY	Anterior	Pink with melanin pigmentation	Scalloped and knife edged	Firm and resilient	Present	Normal	Absent	Absent
	Posterior	Pink with melanin pigmentation	Scalloped and knife edged	Firm and resilient.	Present	Normal	Absent	Absent
MANDIBULAR	Anterior	Pink with melanin pigmentation	Scalloped and knife edged	Firm and resilient	Present	Normal	Absent	Absent
	Posterior	Pink with melanin Pigmentation.	Scalloped & knife edged.	Firm and resilient.	Present	Normal	Absent	Absent.

Mucogingival Problems :

Absent.

Frenal Attachment :

Upper : Gingival

Lower : Gingival.

Width of attached Gingiva : ✓ **Adequate/Inadequate**

Tension Test Negative

Periodontal Pockets : No abnormality detected.

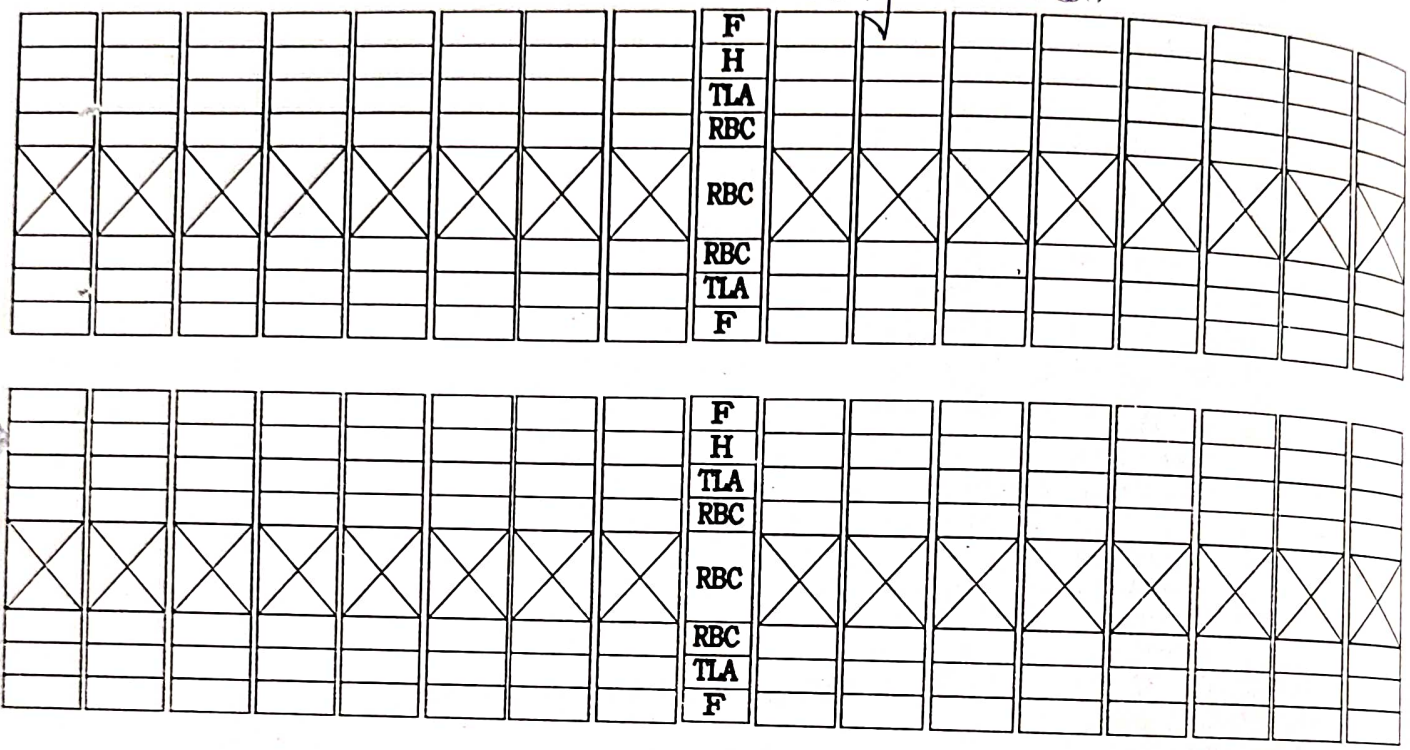

F- Furcation Involvement,

M- Mobility

TLA- Total loss of attachment,

REC- Recession,

PKT-Pocket

Examination of Teeth :

Teeth Present ; 7 6 5 4 3 2 1 | 1 2 3 4 5 6 7
8 7 6 5 4 3 2 1 | 1 2 3 4 5 6 7 8

Wasting Diseases : **Attrition / Abrasion /Erosion**

(31, 32, 41, 42) (-) (-)

Carious Teeth : ① Deep occlusal caries $\frac{c}{6}$
② Pit and fissure caries $\frac{c}{6}$ $\frac{6}{8}$

Restored Teeth: ① Temporary restoration $\frac{c}{6}$

Faulty Restoration : Absent

Pathologic Migration: Absent

Drifting : Absent

Proximal Contacts : Tight contacts

Food Impaction : Absent

Occlusion : Class I Angle's malocclusion seen on right and left side with anterior crown in mandibular arch.

Fremitus Test : - present.
↳ Positive

Teeth Deposits : **Plaque :** + **Calculus** + **Stains** .

Hypersensitivity: Absent.

Etiological Factors :

Local : —

Primary : Plaque.

Secondary : Calculus, Faulty tooth brushing

Systemic : —

Investigations :

Not required.

Laboratory :

—

Radiographic :

IOPA ⊼ $\frac{6|}{6|}$ [Deep occlusal caries]

and

⊼ 8| [Impacted 3rd molar]

Diagnosis :

Chronic generalized marginal gingivitis

Prognosis :

29/3/23

Overall:

Good

Individual:

Good.

Treatment Plan

Preliminary/ Emergency Treatment ;

Non-surgical phase.

Phase I : ① Diet counselling
② Scaling advised.
③ Mechanical aids – Improve toothbrushing – Modified Bass Technique.
④ Chemical aids – Mouthwash – 0.2% Chlorhexidine.
⑤ Occlusal reshaping – Immediate treatment – selective grinding / coronoplasty. Delayed treatment – Correction of occlusion by orthodontic treatment.

Phase II :

Surgical phase

RCT $\bar{c}\ \frac{6|}{6}$

Extraction $\bar{c}\ \cancel{8}|$

Phase III:

Restorative phase.

Composite restoration $\bar{c}\ 6|$

Phase IV:

Maintenance phase.

Class A – 6 months.

INDICES

1. Simplified Oral Hygiene Index (Greene & Vermillion 1964):

DI-S		

CI-S		

OHIS Score Per Person:

Oral Hygiene Status : Good / Fair / Poor

2. Plaque Index (Turesky- Gilmore Glickman, 1970)

☒☒☒☒☒☒☒☒ ☒☒☒☒☒☒☒☒
☒☒☒☒☒☒☒☒ ☒☒☒☒☒☒☒☒

Plaque Score Per Person :

3. Gingival Index (Loe and Silness 1963)

☒☒☒☒☒☒☒☒ ☒☒☒☒☒☒☒☒
☒☒☒☒☒☒☒☒ ☒☒☒☒☒☒☒☒

Gingival Score Per Person :

CASE HISTORY

Sr. No.: 11.

Year : 2022-23.

Patient's Name : Mr. Vaibhav Patel.

O.P.D. No.: 126916.

Age : 43 years

Date : 17/5/23.

Sex : Male.

Occupation : Rickshaw Driver

Address: Lohegaon, Pune

Income: 30,000 Rs/Month.

Chief Complaint :

Patient complains of pain in lower right back region of jaw since 1 week.

History of present illness :

Patient was apparently asymptomatic 3-4 months back, when he started experiencing while soft deposits on tooth surface that gradually increased over 3 months.

Past Dental History :

Stainless steel crown $\bar{c}\,\frac{6}{}$ [4 years ago]

Amalgam Restoration $\bar{c}\,\frac{8}{}$ [4 years ago].

Past Medical History :

No relevant history.

Family History :

No relevant history.

29/05/23

Personal History: Mixed Diet.

Oral hygiene habits: ① Brushing once a day.
② Toothbrush and Toothpaste used for brushing
Other habits : ③ Horizontal
Gutka Chewing, 2-3 times a day Last 4-5 years.

Extra Oral Examination :

Symmetry of face : No Gross Asymmetry detected

Lips: Competent

Lymph Nodes : Non-palpable
Non-Tender.

T.M.Joint: No clicking sound.
No deviation is seen.

Intra Oral Examination :

Halitosis: No relevant history

Oral Mucous Membrane :

Tongeue: } No abnormality detected.

Palate:

Gingiva :

	Region	Colour	Contour	Consistency	Surface Texture	Size	Bleeding On Probing	Exudation
MAXILLARY	Anterior	Pink with melanin pigmentation.	Scalloped & knife edged.	Firm and resilient	stippling present	Normal	Absent	Absent
	Posterior	Pink with melanin pigmentation	scalloped & knife edged.	Firm and resilient	stippling present	Normal	Absent	Absent
MANDIBULAR	Anterior	Reddish	Round	soft and oedematous	Absent	Normal	Present	Absent
	Posterior	Pink with melanin pigmentation	scalloped & knife edged.	Firm and resilient.	stippling present.	Normal	Absent	Absent.

Mucogingival Problems :

Absent.

Frenal Attachment :

Upper : Mucosal

Lower : Mucosal

Width of attached Gingiva : Negative ✓ **Adequate/Inadequate**

- tension test

Tension Test Negative.

Periodontal Pockets :

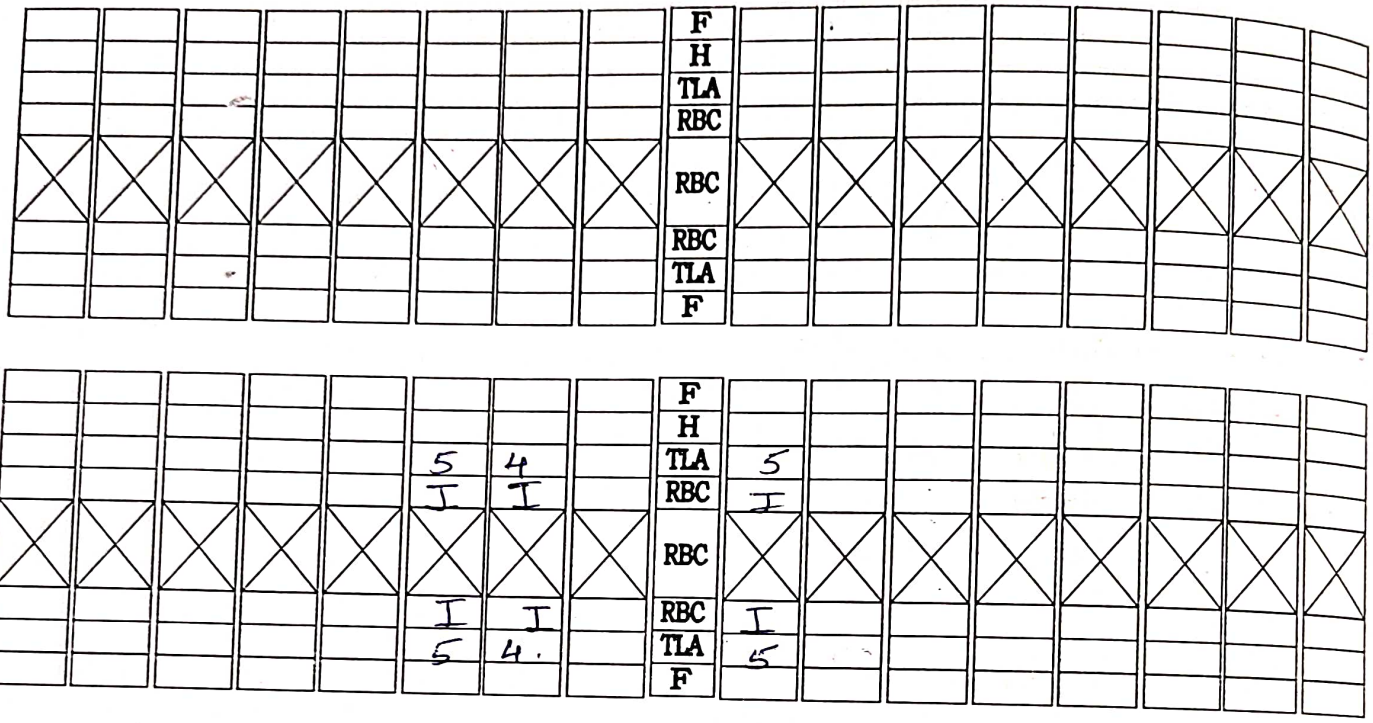

F- Furcation Involvement,

M- Mobility

TLA- Total loss of attachment,

REC- Recession,

PKT-Pocket

Examination of Teeth :

Teeth Present ; 8 7 6 5 4 3 2 1 | 1 2 3 4 5 6 7 8
7 6 5 4 3 2 1 | 1 2 3 4 5 6 7 8

Wasting Diseases : **Attrition / Abrasion /Erosion**

(-) (-) (-)

Carious Teeth : ⑥ Distoproximal Caries = 6

Restored Teeth: Amalgam Restoration = 8

Faulty Restoration : Absent

Pathologic Migration: Absent.

Drifting : Absent

Proximal Contacts : Tight.

Food Impaction : Absent

Occlusion : Class I Malocclusion

Fremitus Test : Negative.

Teeth Deposits : **Plaque :** + **Calculus** ++ **Stains** +

Hypersensitivity: Absent.

Etiological Factors :

Local :

Primary : Plaque.

Secondary :

Calculus, Faulty Tooth brushing

Systemic :

Absent.

Investigations :

Laboratory : CBC, BT-CT, PTT, BSL

Radiographic :

IOPA ⊂ 46.

Diagnosis :

Chronic Localized Periodontitis ⊂ $\frac{|}{32|1}$

Prognosis :

Overall: Fair

Individual:

Fair.

Emergency Access Opening $\bar{c}\,\frac{|}{6|+}$

Treatment Plan Amoxicillin (500mg) TID for 5 days.
Zerodol SP BID for 5 days.

Preliminary/ Emergency Treatment ;

Non-surgical phase

Phase I : ① Full Mouth Scaling Advised.
② Improved Brushing Technique - Stillman's Technique.
③ Chemical Plaque control - 0.2% Chlorhexidine mouthwash.
④ Mechanical Plaque Control - Flossing advised.

Phase II : surgical phase.

1] Root coverage procedure $\bar{c}\,\frac{|}{32|1}$

2] Root canal treatment $\bar{c}\,\frac{|}{6|+}$

Phase III: Restorative phase.

Stainless Steel Crown placement $\bar{c}\,\frac{|}{6|+}$

Phase IV: Maintenance phase.

Class C- 1-3 months.

1000 / 1645

Treatment Plan

Emergency Access Opening $\bar{c}$ $\frac{|}{6}$

Amoxicillin (500mg) TID for 5 days.

Zerodol sp BID for 5 days.

Preliminary/ Emergency Treatment ;

Non-surgical phase

Phase I :

1. Full Mouth scaling Advised.
2. Improved Brushing Technique - Stillman's Technique.
3. Chemical Plaque control - 0.2% Chlorhexidine mouthwash.
4. Mechanical Plaque Control - Flossing advised.

Phase II : surgical phase.

1] Root coverage procedure $\bar{c}$ $\frac{|}{32|1}$

2] Root canal treatment $\bar{c}$ $\frac{|}{6}$

Phase III: Restorative phase.

Stainless Steel Crown placement $\bar{c}$ $\frac{|}{6}$

Phase IV: Maintenance phase.

Class C- 1-3 months.

INDICES

1. Simplified Oral Hygiene Index (Greene & Vermillion 1964):

DI-S

16	11	26
1	1	1
1	1	1
46	31	36

CI-S

16	11	26
1	2	1
1	2	1
46	31	36

OHIS Score Per Person:

DI-S = 1

CI-S = 1.99

Oral Hygiene Status : **Good /** **Fair** ✓ **/** Poor

2. Plaque Index (Turesky- Gilmore Glickman, 1970)

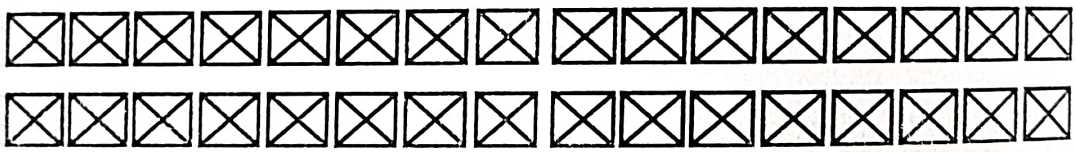

Plaque Score Per Person :

3. Gingival Index (Loe and Silness 1963)

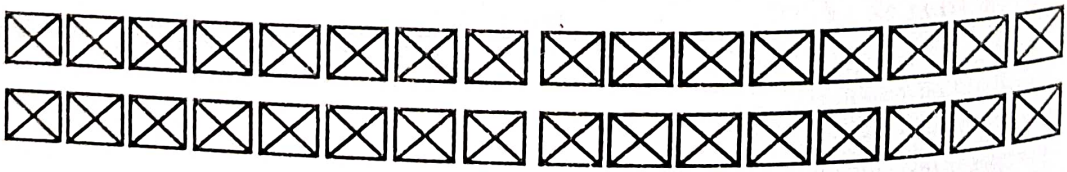

Gingival Score Per Person :

CASE HISTORY

Prelims.

Sr. No.: 12.

Year : 2023.

Patient's Name : Mr. Vijaylaxman Gavahan.

O.P.D. No.:

Age : 42years.

Date : 9/6/23.

Sex : Male.

Occupation : Job.

Address: Manjri, Budruk, Hadapsar.

Income: –

Chief Complaint :

Patient complains of unclean teeth since 1 to 1 1/2 months.

History of present illness :

Patient was apparently asymptomatic 2 months ago. Later patient started experiencing white soft deposits on teeth which gradually increased over time. Patient also complains of recession.

Past Dental History :

Extraction $\bar{c}$ 4 years ago. No complications occured.

Past Medical History :

No relevant history.

Family History :

No relevant history.

Personal History:

Diet - Mixed diet.

Oral hygiene habits:

Brushing - 2 times a day. [medium hard] toothbrush and toothpaste - [Colgate]

Horizontal brushing technique with

Other habits :

No relevant history.

Extra Oral Examination :

Symmetry of face : No gross asymmetry detected.

Lips: Competent.

Lymph Nodes : Not palpable

T.M.Joint: Clicking, popping heard. No deviation seen.

Intra Oral Examination :

Halitosis: No abnormality detected.

Oral Mucous Membrane :

Tongeue: } No abnormality detected.

Palate:

Gingiva :

	Region	Colour	Contour	Consistency	Surface Texture	Size	Bleeding On Probing	Exudation
MAXILLARY	Anterior	Pink with melanin pigmentation.	Scalloped and knife edged	Firm and resilient	Present	Normal	Absent	Absent
	Posterior	Pink with melanin pigmentation.	Scalloped and knife edged.	Firm and resilient	Present	Normal	Absent	Absent.
MANDIBULAR	Anterior	Pink with melanin pigmentation.	Scalloped and knife edged.	Firm and resilient	Present	Normal	Absent	Absent.
	Posterior	Pink with melanin pigmentation.	Scalloped and knife edged.	Firm and resilient	Present	Normal	Absent	Absent.

Mucogingival Problems :

Absent.

Frenal Attachment :

Upper : Mucosal.

Lower :

Adequate/Inadequate ✓

Width of attached Gingiva :

Adequate

Tension Test

Periodontal Pockets :

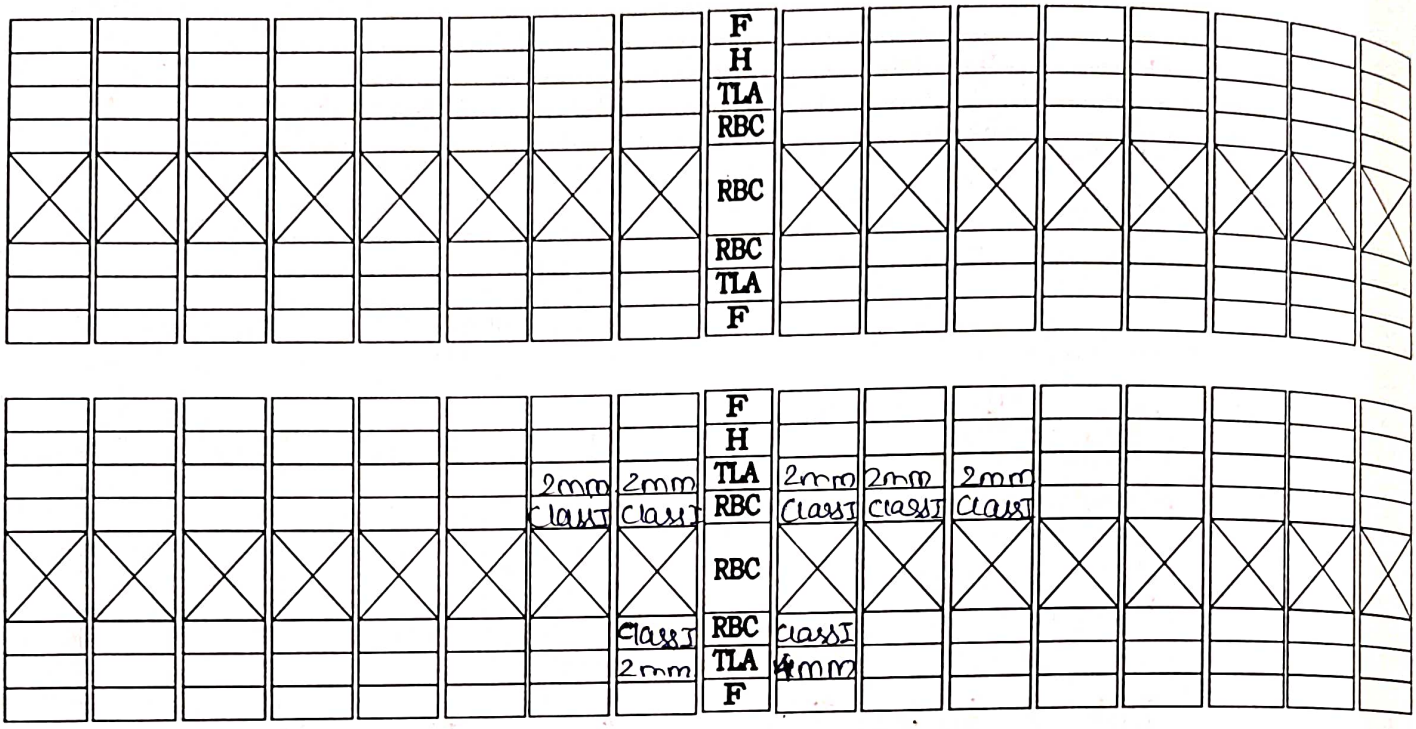

F- Furcation Involvement,

M- Mobility

TLA- Total loss of attachment,

REC- Recession,

PKT-Pocket

Examination of Teeth :

Teeth Present ; 31 c̄ $\frac{87654321 \mid 12345678}{87654321 \mid 12345678}$

Wasting Diseases : **Attrition** / **Abrasion** /**Erosion**

$(\frac{321 \mid 123}{321 \mid 123})$ (—) (—)

Carious Teeth : - ① Pit and fissure caries c̄ $\frac{76}{6}$

② Deep occlusal caries c̄ $\frac{8}{}$

Restored Teeth: ↳ c̄ $\frac{}{6 \mid 6}$

Faulty Restoration : Absent.

Pathologic Migration: Absent

Drifting : Absent.

Proximal Contacts : Present

Food Impaction : Absent

Occlusion : Angle's class I malocclusion with left and right side.

Fremitus Test : Positive

Teeth Deposits : **Plaque :** + **Calculus** + **Stains** Absent.

Hypersensitivity: Absent.

Etiological Factors :

Local :

Primary : Plaque.

Secondary : Calculus, Faulty tooth brushing

Systemic : Absent

Investigations :

Laboratory :

Not applicable

Radiographic :

IOPA ⏜ 8|

Diagnosis :

Chronic generalized marginal gingivitis
⏜ Chronic localized periodontitis ⏜ 21|123

Prognosis :

Overall:

Good

Individual:

Good.

Treatment Plan

Preliminary/ Emergency Treatment ; Not applicable.

Phase I : Non- surgical.

1. Diet counselling
2. Improve brushing technique - Modified Stillman's technique.
3. chemical aids - 0.12% chlorhexidine mouthwash Suggested.
4. Occlusion correction [To treat trauma from occlusion].

Phase II : 5. Immediate - Coronoplasty.
Long term - Orthodontic correction.

Surgical Phase.

1. Root coverage procedure $\overline{c}\,\frac{|}{21|123}$
2. Extraction $\overline{c}\,\frac{8|}{|}$

Phase III:

Restoration Phase.

Restoration $\overline{c}\,\frac{76|}{6|}$

Phase IV:

Class B - 3-4 months

PERIODONTAL PROBES

Tutorials

1] Periodontal probes are used to measure the depth of the pockets and to determine their configuration.

2] The typical probe is tapered, rod like instrument calibrated in millimeters, with round and blunt tip.

Types of periodontal Probes.

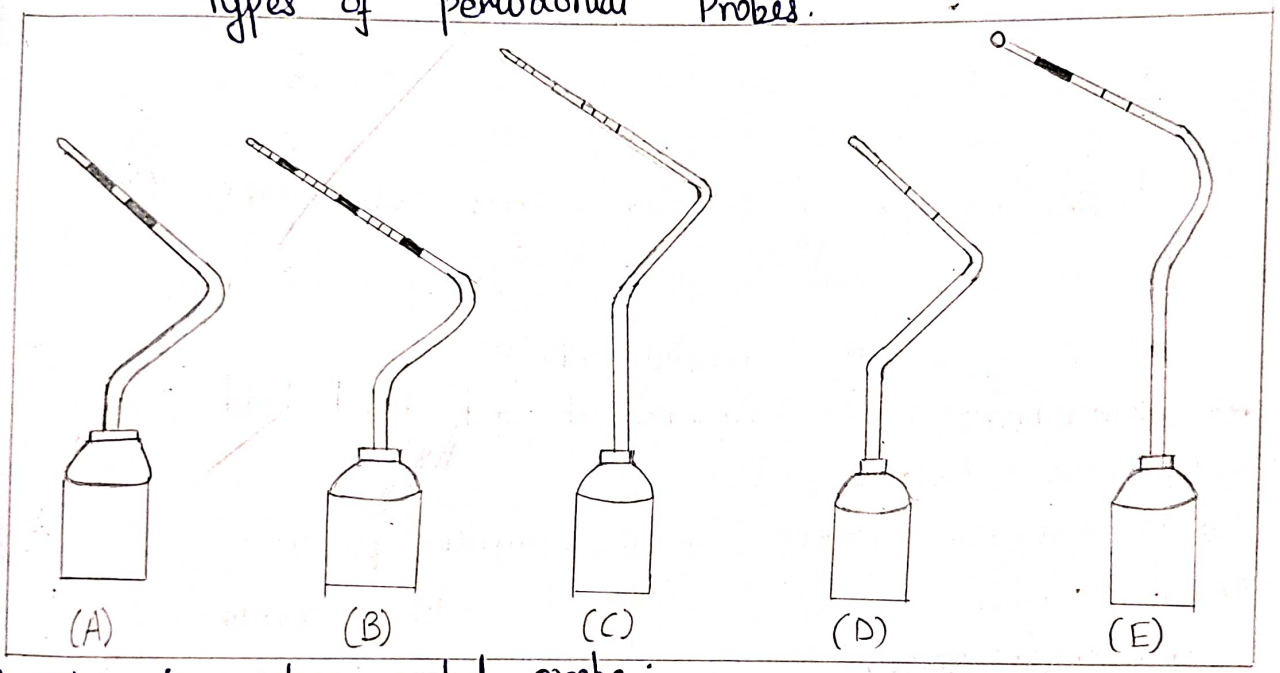

A] Marquis color coded probe:
Calibrations are in 3mm sections

B] University of North Carolina - 15 probe.
a. 15mm long probe with millimeter markings at each millimeter and color codings at the 5, 10 and 15 mm

C] University of Michigan "O" probe with-
Williams markings at 1, 2, 3, 5, 7, 8, 9 and 10mm

D] Michigan "O" probe with markings at 3, 6 and 8mm.

E] WHO probe- It has 0.5 mm ball at the tip and millimeter markings at 3.5, 8.5 and 11.5 mm and color coding from 3.5 to 5.5mm.

Tutorials

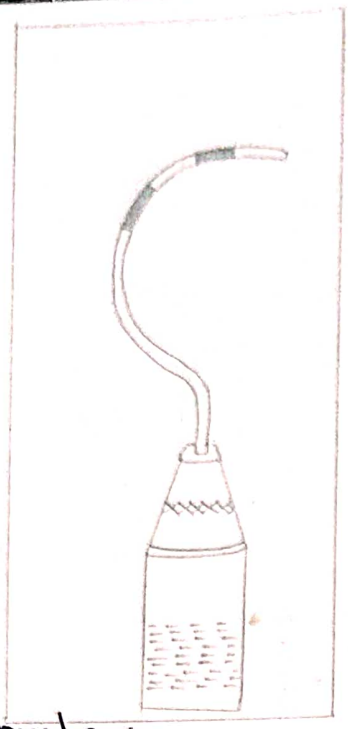

Naber's probe :
For detection of furcation areas with color coded markings at 3, 6, 9 and 12 mm.

Classification of probes [Generations]:

1] First generation probes : Conventional and hand held probes [WHO probe ; Naber's probe].
2] Second generation probes : Pressure - sensitive probes.
3] Third generation probes : Computerized probes - [Florida probe, Foster Miller probe]
4] Fourth generation probes : Three dimensional probes.
5] Fifth generation probes : Ultrasonographic probes [Ultra sonographic US probes]

CLASSIFICATION OF PERIODONTAL INSTRUMENTS

Introduction : Periodontal instruments are designed for specific purposes such as removing calculus, planing root surfaces, curetting the gingiva and removing diseased tissue.

CLASSIFICATION OF PERIODONTAL INSTRUMENTS

1] Periodontal probes [to locate, measure, mark pockets)
2] Explorers [to locate calculus deposits and caries]

3] Scaling, root planing and curettage instruments these are classified as - a) Sickle scalers b) Curettes c) Hoe chisels, file scalers d) Ultrasonic and sonic instruments.

4] Periodontal endoscopes.

5] cleansing and polishing instruments.

Tutorials

PARTS OF INSTRUMENT



Periodontal instrument is composed of : 1] Blade 2] shank 3] Handle.

- **Mouth Mirror**

It is a diagnostic instrument with a reflection mirrored surface on the working end.

Uses : 1] Indirect vision : To view a tooth surface or intra-oral structure that cannot be seen directly

2] Retraction : Use of mirror head to hold the patient's cheek, lip or tongue for better viewed structures.

3]. Indirect illumination : To reflect light onto the tooth surface where it is needed.

4] Transillumination : Technique of directing light off the mirror surface through the anterior.

→ classification of mouth mirror:

(According to types of surfaces)

a] Front surface: Reflecting surface is an front of glass that produces clear image with no distortion and good image quality. It can be easily damaged and expensive.

b] Plane [flat surface]: Reflecting surface is of back surface of mirror lens and produces double [ghost] images which can be distracting.

c] Concave surface: Reflecting surfaces is of concave front surface mirror that shows magnified image - May lead to distortion.

I] PERIODONTAL PROBES :

- Periodontal probes are used to locate, measure and mark pockets, as well as determine their course on individual tooth surfaces.

• A typical probe is a tapered, rod like instrument callibrated in millimeters with a blunt rounded tip.
• When measuring a pocket, the probe is inserted with a fine, gentle pressure to the bottom of the pocket.
• The shank should be aligned with the long axis of tooth.

Tutorials



II] EXPLORERS

1] Explorers are used to locate calculus deposits, caries.
2] Also used to locate subgingival deposits and check the smoothness of root surfaces after root planing.
3] Explorers are designed with different shapes and angles for a variety of use according to its needs.

III] SCALING, ROOT PLANING AND CURETTAGE INSTRUMENT.

1] Used for removal of biofilm and calcified debris from the crown, root of tooth, removal of altered cementum from the subgingival root surface and debridement of the soft tissue lining the pocket.
2] They are classified as below:
i) Sickle scalers: -Have a flat surface and two cutting edges and converge in a sharply pointed tip.
• It is primarily used to remove supragingival calculus.
ii) Curettes: - . These are fine instruments used for subgingival scaling, root planing and removal of soft tissue lining the pocket.
iii) Hoe, chisel and file scalers: 1] Used to remove tenacious subgingival calculus and attached cementum. 2] Their use is limited compared with that of curettes. 3] Hoe scalers are used for scaling of ledges or rings of calculus. 4] Chisel scalers are designed for the proximal surfaces of teeth. 5] Files are used to fracture/ crush calculus.
iv) Ultrasonic and sonic instruments: Used for scaling and cleaning of tooth surfaces and curettage the soft tissue

The five basic scaling instruments.

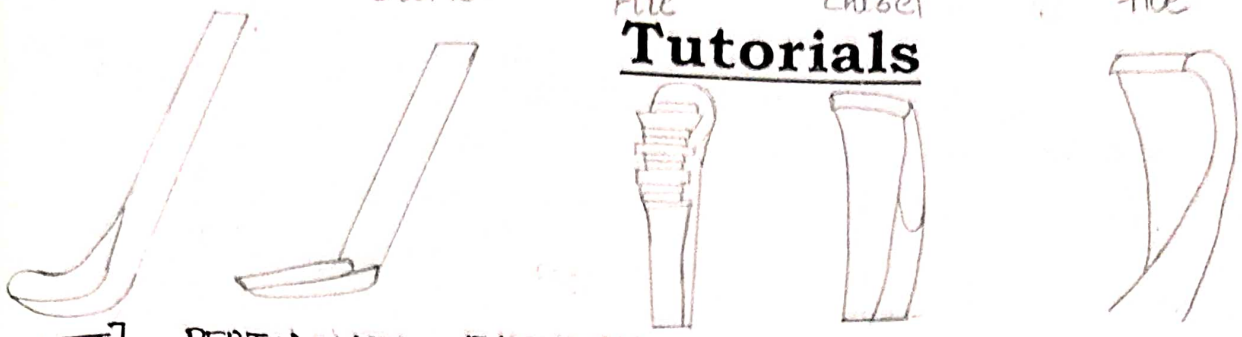

Tutorials

IV]. PERIODONTAL ENDOSCOPES.

- A dental endoscope has been introduced for use subgingivally in the diagnosis and treatment of periodontal disease.
- This device allows clear visualization, deeply into subgingival pockets and furcation.
- It permits operators to detect subgingival deposits and guides them in thorough removal of these deposits.

V]. CLEANSING AND POLISHING INSTRUMENTS:

These instruments category consists of - a) Rubber cusps: They consist of a rubber shell with or without webbed configuration in hollow interior.

b) They are attached to the handpiece and a good cleansing and polishing paste that contains. Fluoride is used to keep the rubber cusps moist and minimize frictional heat.

b] Bristle brushes: - There are available in wheel and cup shapes - Since the bristles are stiff, the brush should be confined to the crown to avoid injury to the cementum.

c] Dental tape: It is used with polishing paste. Used to polish proximal surfaces that are inaccessible to other polishing instruments.

d] Air-power polishing: A specially designed handpiece is used to deliver an air powered slurry of water and sodium bicarbonate for polishing. It is effective in removing extrinsic stains.

VI]. SURGICAL INSTRUMENTS:

1] Periodontal surgery is accomplished by various instruments.

a) Excisional and incisional instruments eg. Periodontal knives, interdental knives, surgical blades.

b] Surgical curettes and sickles.

c] Periosteal elevators

d] Surgical chisels.

CURETTES

Tutorials

- The curette is the instrument of choice for removing deep subgingival calculus, root planing altered cementum and removing the soft tissue lining the periodontal pocket.
- Each working end has a cutting edge on both sides and a rounded toe.
- The curette is finer than sickle scalers and than does not have any sharp points or corners other than cutting edges of the blade.
- Therefore, curettes can be adapted and provide good access to deep pockets, with minimal soft tissue trauma.

There are 2 types of curettes: —1] Universal 2] Area specific

1] Universal curettes - Universal curettes have cutting edges that may be inserted in most areas of the dentition by altering and adapting the finger rest, fulcrum and hand position of the operator.

The blade size and the angle and length for the shank may vary, but the face of blade of every universal curette is at 90° angle [Perpendicular] to the lower shank when seen in cross section from the tip.

Examples - 1] The Barbart curettes # 1-2 and 5-6.
2] Columbia Curettes # 13-14, 2R-2L, 4R-4L.
3] Younger Good #7-8, McCalls # 17-18.
4] Indiana University # 17-18.

Basic characteristics of a curette: Spoon shaped blade and rounded tip:

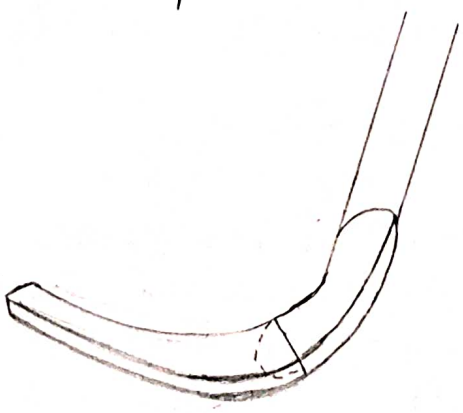

Basic characteristics of curette.

Tutorials

Specifications	Gracey curette	Universal curette.
Area of use	Set of many curettes designed for specific areas and surfaces.	One curette designed for all areas and surfaces.
Cutting edge use.	One cutting edge used, works with outer edge only.	Both cutting edges used, work with either outer or inner edge.
Curvature.	Curved in two planes blades curves up and to the side.	Curved in 1 plane. Blade curves up not to the side.
Blade angle.	Offset blade, face of blade beveled at 60° to shank.	Blade not offset face of blade beveled at 90° to shank.

Diagrams:

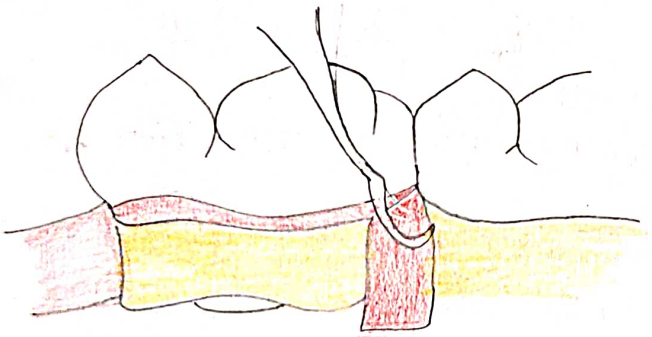

Curette inserted in pocket in a position of the base of a pocket on the distal surface of mandibular molar.

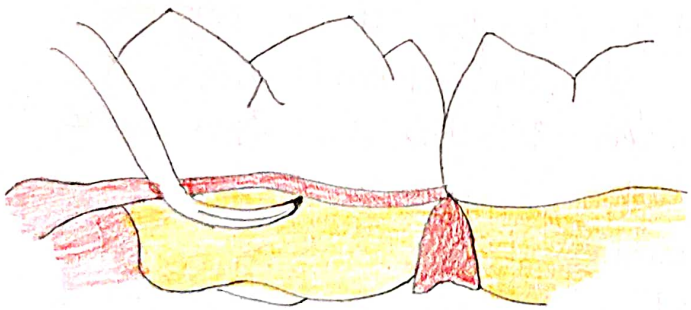

Curette inserted in a pocket with the tip directed apically.

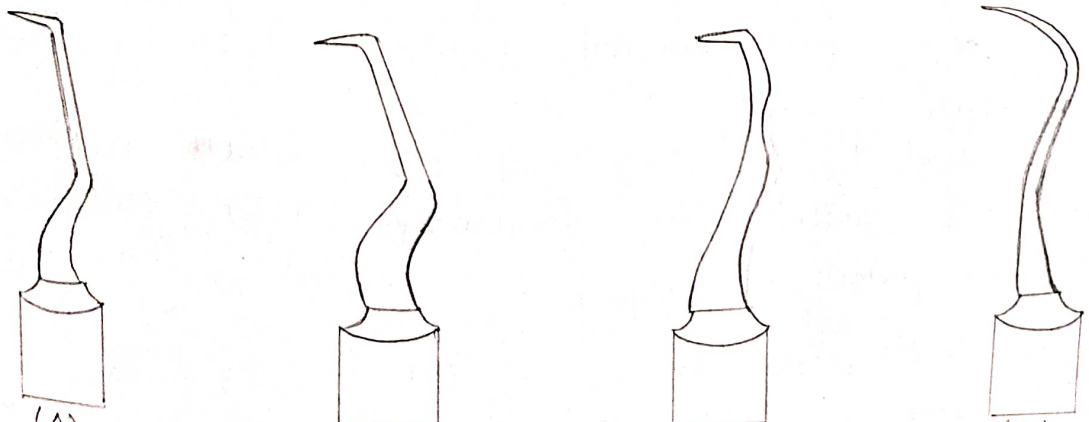

Micro Mini 4 Gracey Curettes

(A) # 1-2

(B) # 7-8

(C) # 11-12

(D) # 13-14



Tutorials

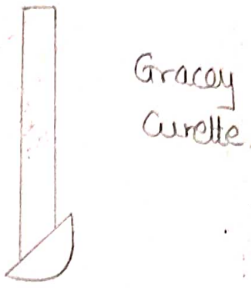

Modifications of curettes:

1]. Extended shank curettes [After five curettes] - The terminal shank is 3mm longer allowing extension in deeper periodontal pockets of 5mm or more.
- Rigid design: For heavy calculus removal.
- Finishing design - light scaling or deplaquing.

2] Mini bladed curettes (mini five)
- The blades are half of the length of standard curettes.
- The short blade allows easier insertion a adaptation in deep, narrow pockets, furcations developmental grooves, line angles and deep tight pockets.

3] Micro mini five Gracey curettes:
- Their blades are 20% thinner and smaller than mini five curettes.
- These are smallest of all curettes and provide exceptional access and adaptation to tight, deep or narrow pockets.

4] Gracey curettes [set of 4 minibladed curettes]
- The blade length is 50% shorter than conventional Gracey curettes and blade is curved slightly upward.
- This curvature allows Gracey curettes to adopt more closely to tooth surface than any other curette.

5] Periodontal maintenance curette [most recent → Nov 2015]
The blade is 1mm shorter and 20% thinner, and face of the blade is offset from terminal shanks at 60° [other Gracey designs offset at 70°)
These are used for patients with tight tissues, recessions and residual pocket depth following initial periodontal therapy or periodontal surgery.

6] Longer and mini longer curettes [Set of 3]:
- The universal blade is honed at 90° angle rather than offset blade of Gracey curette.

- This marriage of Gracey and universal curette designs allows the advantages of area specific shank to be combined with the versatality of the universal curette blade.

Tutorials

PRINCIPLES OF INSTRUMENTATION

Effective instrumentation is governed by a no. of general principles that are common. The basic principles of instrumentation are - ① Accessibility ② Visibility, Illumination, Retraction,
③ Conditioning and sharpness of instruments
④ Maintenance of clean field.
⑤ Instrument stabilization — Instrument grasp.
Finger rest.
⑥ Instrument - Activation, Adaptation, Angulation, Lateral pressure, Strokes.

1] Accessibility :

Accessibility facilitates thoroughness of instrumentation The position of the patient and the operator should provide maximum accessibility to the area of operation.
Neutral seated position for the clinician - i) Forearm parallel to the floor ii) Weight evenly balanced
iii) Resting elbow should be at the level of oval cavity.
Thighs parallel to the floor.
Back straight and head erect.
Avoid positioning your legs under the back of patient chin. Four basic positions -
70° clock, 90° clock, 10-11 o'clock, 12 o'clock.
Patient position - For maxillary arch - chin up
For mandibular arch - chin down.

2] Visibility, Illumination and Retraction

1] The operator should preferably operate on the patient with direct illumination
2] The light beam of dental chair lamp should be oriented parallel to the viewing direction in order to obtain shadow from lighting.

5]. Dental mirror is used for viewing the tooth surface that cannot be seen by direct vision.

4] Transillumination : A mirror is used for transillumination. It is effective only with anterior teeth because they are thin enough to allow light to pass through them.

Retraction :- Mouth mirror is used to retract the lips and cheeks while retracting cheek with mouth mirror the index finger on non-operating hand should be used to retract the lips and protect angle of mouth.

3] Conditioning and sharpness of instruments:
The working ends of the pointed or bladed instrument must be sharp to be effective.

- Methods to check instrument sharpness-

a) Glare test - A sharp cutting edge does not reflect but a dull instrument does.

b) Acrylic test
c) Clinical performance
d) Comparing with new instrument

- Advantages of sharp instrument-
  - Easier calculus removal
  - Improved stroke control
  - Reduced no. of strokes
  - Increased patient comfort
  - Reduced clinician fatigue

4] Maintaining clean, dry field:

Adequate suction is essential and can be achieved with saliva ejector or an aspirator.
Blood and debris can be removed using a suction by wiping and blotting with gauze squares.
Compressed air and gauze can be used to facilitate visual inspection of tooth surfaces just below gingival margins during instrument.

Tutorials

5]. Instrument stabilization:

Stability of the instrument and hand is primary requisite for controlled and effective instrumentation and avoidance of injury to the patient or clinician.

Tutorials

Two factors that promote stability are :-

Instrument grasp:

Modified pen grasp: Most effective and stable.

Modification of standard pen grasp, ensures contact in performing instrument procedures. The thumb, index finger and middle finger is positioned so that side of pad next to finger nail is resting on instrument. The side of pad next to finger nail is resting on instrument shank. The index finger is bent at second joint from the finger tip and is placed midway between middle finger and index finger This creates Tripod effect. It enhances control and tactile sensitivity.

Palm and thumb grasp: Used for stabilizing instrument during sharpening and for manipulating air and water syringes.

Finger rests:

Finger rest serves to stabilize the hand and the instrument by providing a fulcrum as movements are made to activate the instrument.

Classification - 1] Intraoral finger rests.
2] Extraoral finger rests.

Modified pen grasp:

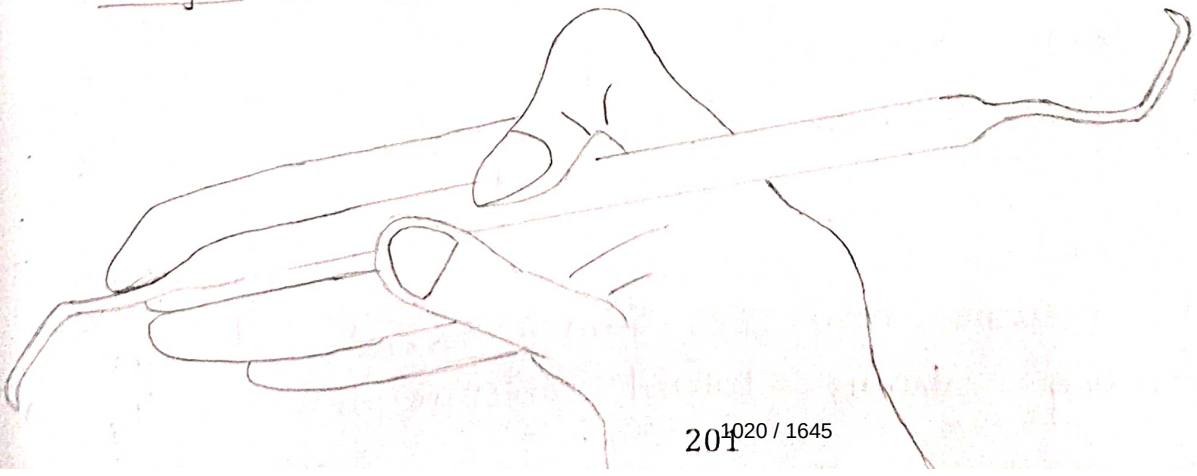

1020 / 1645

Variations of intra-oral finger rests-

- Conventional adjacent teeth.
- Cross arch - rest on other side of same arch.
- Opposite arch.
- Finger on Finger - The fingers rest is stabilizing the tooth surface by index finger or thumb of non-operating hand.

Tutorials

Extra-oral fulcrums-

- Palm up
- Palm down.

Both intra-oral and extra-oral fulcrums may be reinforced by applying the index finger or thumb of non-operating hand to the handle of instrument for added control and pressure against tooth.

6] Instrument activation :

• Adaptation : It refers to manner in which the working end of a periodontal instrument is placed against surface of tooth.

Objective of adaptation is to make the working end of the instrument conform to the contours of tooth surface.

If an instrument is adapted so that only the tip is in contact, the soft tissue can be compressed by working end also causing trauma and discomfort.

Angulation :-

Refers to an angle between the face of bladed instrument and tooth surface. It may also be called the tooth blade relationship.

For subgingival insertion, angulation should be close to 0°.

Lateral pressure :-

Lateral pressure may be firm, moderate or light often removing calculus. Lateral pressure is initially

applied firmly diminished until light Lateral pressure is applied for final root planing.

Strokes - 3 basic types of strokes.

1] Exploratory stroke
2] Scaling stroke
3] Root planing stroke.

Exploratory stroke - It is a stroke that is used with probes and explorers to evaluate and dimensions of pockets and to detect calculus and irregularities of tooth surface.

Scaling stroke : It is a short powerful pull stroke that is used with bladed instrument for the removal of both supra and subgingival calculus. The muscles of finger and hands are tensed to establish a secure grasp and lateral pressure is established against tooth surface. The wrist and forearm motion, pivoting in an arc on finger rest produces a more powerful strokes and is therefore preferred for scaling.

Root planing strokes - It is moderate to light pull stroke that is used for final smoothening and planing of root surface.

Tutorials

For Scaling and root planing

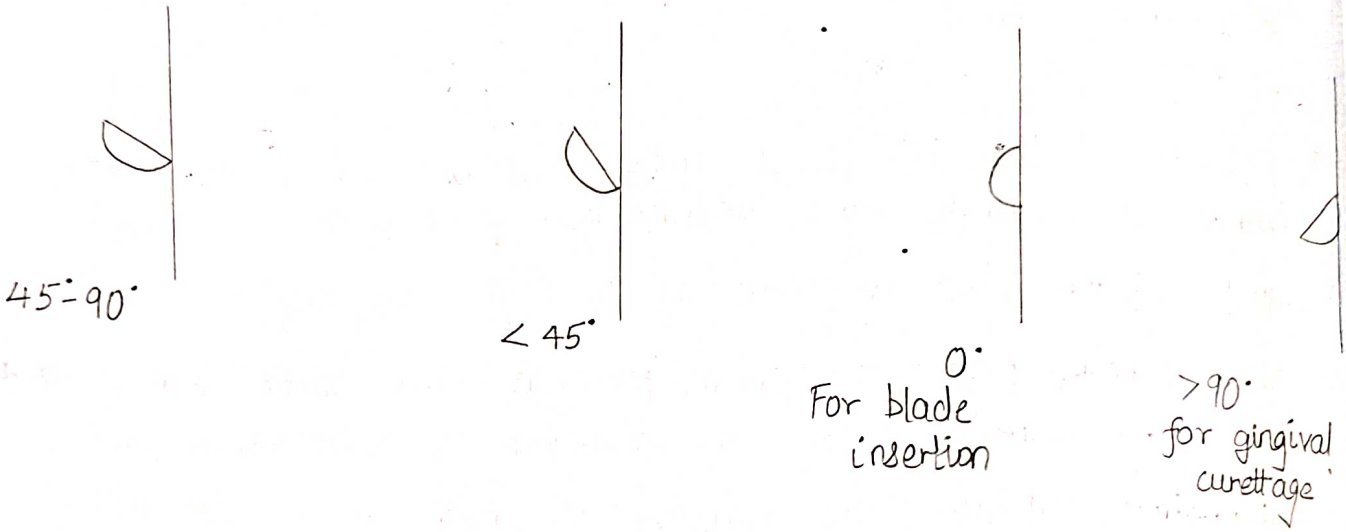

Blade angulations

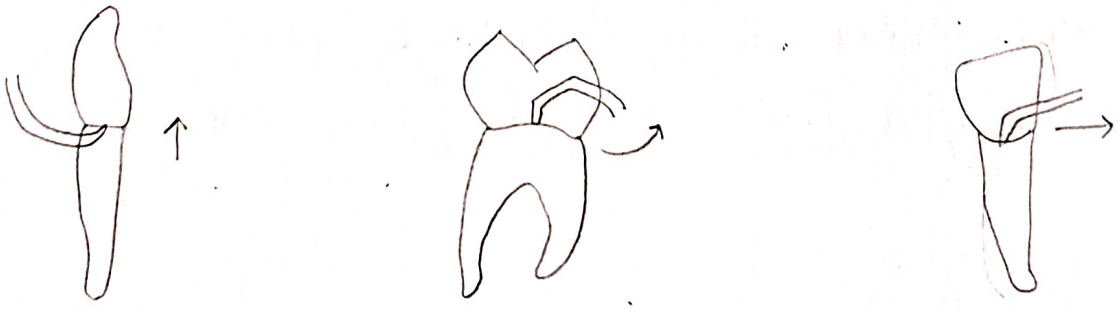

Vertical Oblique Horizontal

Blade Stroke direction

MECHANICAL PLAQUE CONTROL

Tutorials

Plaque control is the regular removal of microbial plaque and preservation of its accumulation on the teeth and adjacent gingival surfaces. It is also called as oral physiotherapy

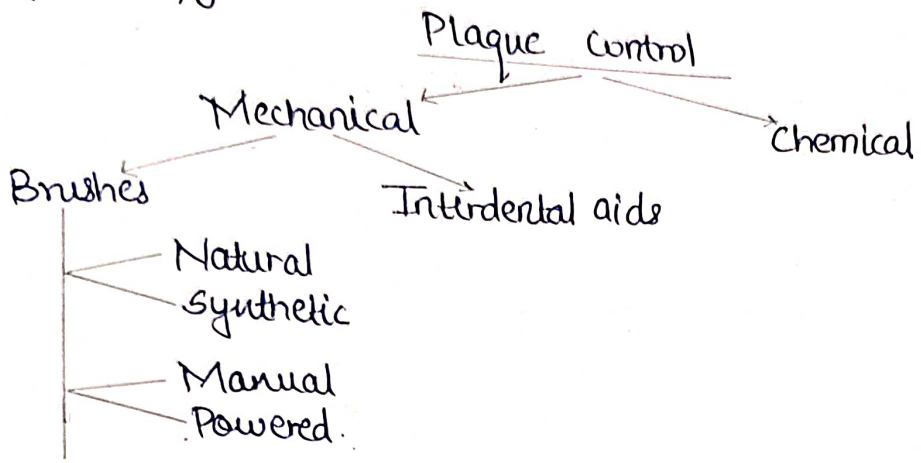

Toothbrushes :

The first toothbrush was made by William Addis in England 1780. The handle was carved from bone and brush from swine bristles.

- Toothbrushing design , ADA specification - 119.
  Width - 3/8 - 5/16 inches.
  Length - 1 - 1 1/4 inches.
  5-12 rows of tufts.
  80 - 86 tufts per bristle
  Group of bristles is called tufts.
  Diameter of toothbrush -
  0.07 inches for soft bristles.
  0.012 inches for medium bristles.
  0.014 inches for hard bristles.

Bristle hardness is directly proportional to square of diameter and inversely proportional to square of bristle length.

Powered toothbrushes - 205

1st created in Switzerland 1937

These have oscillating and rotating motion.
Low frequency acoustic energy to enhance clearing ability.

Tutorials

Most commonly used in - Hospitalized patients. Children with physical and mental disabilities, patients with fixed orthodontic appliances.

Dentifices -

These aid in clearing and polishing tooth surfaces. Dentifices ingredients help in reducing calculus, plaque, gingivitis, stains.

Component	Composition		Material	Purpose
	Paste	Powder		
Abrasive	20-55%	90-95%	- Calcium carbonate - Dibasic Ca - Silica.	Removes plaque and stains, polishes tooth surface.
Detergents	1-2%	1-6%	Sodium lauryl sulfate	Aids in debris removal by decreasing surface tension.
Colourants	1-2%	1-2%	Food colours TiO_2, Mica.	Used for coloured appearance
Flavouring agents	1-2%	1-2%	Oil of menthol Sorbitol Peppermint.	Provides flavours.
Humectants	20-30%	0	Sorbitol, Glycerine	Moisture.
Water	3%	0		Acts as suspension
Binder	3%	0	Xantham gum Synthetic cellulose 206 - Sodium	Maintains viscosity Prevents caries

Fluorides Therapeutic agents Tartar control	0-1%	0	Trisodium Pyrophosphate	Inhibits formation of calculus.

Toothbrushing Methods:-

Horizontal Scrub Technique
Vertical - Leonard Technique
Circular - Fones technique
Horizontal and Vibratory - Stillman's, Charter and Bass technique.

Modified Bass technique -

Also called as sulcus cleaning technique.

Indications - As a routine oral hygiene method.
Intrasulcular cleaning.

Technique -

The toothbrush is held in such a way that the bristles are at 45° to the gingiva.
Bristles are gently vibrated by moving the brush back and forth. The bristle are then moved over the side of tooth towards their occlusal surfaces in a single motion in vertical direction.

Advantages -

Excellent, sulcus cleaning.
Good interproximal and gingival cleaning.
Good gingival stimulation.

Disadvantage - Dexterity of wrist is required.

Modified Stillman's technique-

Indications: For massaging the gingiva in cases of gingival recession, dental plaque removal from below the height of contour of the enamel and from exposed proximal surfaces.

Technique-
The bristles are pointed apically with an oblique angle to the long axis of tooth.
The bristles are positioned partly on the adjacent gingiva.
The bristles are activated by short back and forth motion are simultaneously moved in coronal direction.
Following 20 strokes the procedure is repeated systematically on adjacent teeth.

Disadvantage: Time consuming.
Improper brushing can damage epithelial attachment.

Charter's method-
Indications - Periodontal surgeries to promote healing and massaging.
Individual having open interdental spaces.
Technique - Soft multitufted toothbrush is indicated for this technique. Bristles are pointed occlusally and are activated by mild vibratory strokes.
Advantage - Massage and stimulation for marginal and interdental gingiva.
Disadvantage - Brush ends do not engage the gingival sulcus to remove subgingival bacterial accumulation.

Interdental cleaning aids -
Classification - Based on types of embrasures:
Type I: Embrasure with no interdental gingival recession are adequately cleaned using a dental floss.
Type II: Longer surface with rounded interdental papillae and requires use of inter proximal brushes.

Type III - Excessive recessed gingiva i.e. In diastema or exposed root furcation, single / unitufted brushes are used.
eg. Proxa brush.

Tutorials

Dental floss: Any toothbrush, regardless of the brushing method does not completely remove plaque Biofilms. Hence, interdental aids are necessary.
Types:- a) Monofilament or multifilament.
b) Waxed, unwaxed.
c) Twisted, non-twisted.

Interdental brushes - Concave root surface such as mesial aspect of the maxillary first premolar and furcation or if in periodontal patients there is significant attachment loss and recession are not cleaned by the floss.

Classification-
1] Conical cylindrical 2] Tapered Rounded 3] Single Tufted.

Oral irrigation-
Aqua flosses are dental water jet has shown to significantly reduce gingivitis, bleeding on probing and periodontal pathogens.
Either water or antimicrobial agents are used.
MOA - It works on basis of hydrokinetic energy.
Impact zone on which the solution initially comes in contact with the tooth surfaces.
Flushing zone - In which the solution reaches the subgingival sulcus and cleans it.
Clinical outcomes - Improved removal of plaque biofilm and reduction in calculus, gingivitis and bleeding on probing.

CHEMICAL PLAQUE CONTROL

Tutorials

Chemical plaque control is an adjunct to and not a substitute for mechanical plaque control.
An ideal chemical plaque control agent should have properties like-

1] Substantivity - Ability to bind to tissue surface and released over time.
2] Penetrability - Ability to penetrate deeply into biofilm.
3] Selectivity - Ability to affect a specific bacteria in mixed population.

Factors affecting to deliver clearance of plaque control agents from the oral cavity

1) Stability of active agent.
2) Solubility in oral cavity.
3) Bio-availability
4) Accessibility to site of action.
5) Interaction between agent receptor site

- Chemical plaque control agents are grouped as-

a) Ist generation

1) Phenolic compounds
   - Phenol
   - Thymol
   - Triclosan
   - Listerine
   - Ethyl resorcinol
2) Quaternary ammonium compounds:
   Ethyl pyridium fluoride
   Benzothonium chloride
3) Antibiotics
   Vancomycin
   Kanamycin

b) IInd generation

1] Bisbiguanide
   - chlorhexidine
   - Alexidine
2] Bisyridine
   Detehidiene hydrochloride
3] Chlorhexidine

c) 3rd generation
   Delmopinol

d) 4th generation
   probiotics.

Halogens
- Iodine

Metallic ions.
- Zinc
- Copper
- Tin
- Silver
- Mercury
- Herbal extracts.

Antiplaque enzymes
- Mucinase
- Mutanase
- Dextranase

Oxidizing Fluoride

3] Chlorhexidine rinse:-

This agent has shown most positive antibacterial results prescribed as twice a day with 10 ml of 0.2% aqueous solution of chlorhexidine digluconate. It has completely inhibited dental plaque, calculus, gingivitis. It has a broad antimicrobial spectrum.

Mechanism of action:

At low concentration it causes leakage of intracellular potassium and reduction in bacterial acid production. Bacteristatic.

At high concentration it causes bacterial cell wall disruption and coagulation of cytoplasmic constituents.

It has also inhibited enzymes involved in bacterial adhesion bacterial growth and metabolism.

Tutorials

Side effects :-

It has reversible side effects. The teeth, tongue and silicate and resin restoration.

Impairment of taste.

It has low systemic toxicity.

Anti-Plaque action of chlorhexidine:

Preventing pellicle formation by blocking acid group on salivary glycoproteins.

Preventing adsorption of bacterial cell wall to the tooth surface.

Preventing binding of plaque by precipitation agglutination factors.

25/05/23

D Y PATIL GROUP

D Y PATIL DENTAL SCHOOL

Dr. D. Y. Patil Knowledge City, Charholi (BK) Via - Lohegaon, Pune - 412105

DEPARTMENT OF PERIODONTOLOGY

AND

ORAL IMPLANTOLOGY

Year : 2023 winter

Name : Vaishnavi Joshi

Roll No. : 05

Univ. Examination No.: 40612

Date 21/10/23 Signature of In -Charge

Signature of HOD

Scanned by Scanner Go

INDEX

1. Do's and Don'ts for students.
2. List of Instruments for III B.D.S. and IV B.D.S. Clinics.
3. Clinical Quota.
4. Demonstrations.
5. Work Done.
6. Case History Sheets.
7. Tutorials.
8. Books for Reference .

Scanned by Scanner Go

INDEX

1. Do's and Don'ts for students.
2. List of Instruments for III B.D.S. and IV B.D.S. Clinics.
3. Clinical Quota.
4. Demonstrations.
5. Work Done.
6. Case History Sheets.
7. Tutorials.
8. Books for Reference .

Scanned by Scanner Go

Do's and Don'ts for Students

1. Students should be punctual to clinics and works sincerely.
2. Each student should wear a clean apron and strictly follow- Formal dress code with Name plate.
3. No Slippers or sports shoes allowed **formal shoesto be worn compulsory.**
4. Equipments in clinics should be **handled** with utmost care. Students shall be fined for any damage/loss.
5. No page from journal should be torn, nor any remark to be rubbed off.
6. Use of **Sterilized instruments,** Face **Mask, Head camp, Hand gloves** and **eye protector** is mandatory while working on a patient.
7. **Mobile Phones** are strictly not allowed in clinics. Any misbehavior in this regard shall lead to the mobiles being confiscated.
8. Students should pay attention to their personal hygiene, such as- nails should be trimmed and without nail polish.
9. Each student should carry the **Journal** daily for clinics.
10. Each student should make **Entries** in the work done and appointment register every day after treatment.
11. Students must take **signature** on case history and work done on the same day of treatment.
12. Students cannot leave the Department without permission.
13. Students shall be given demonstration of various procedures during the course of the postings, hence attendance is considered of utmost importance. Students who remain absent have to justify their absence appropriately.

Scanned by Scanner Go

List of Instruments for III B.D.S. and IV B.D.S. Clinics

1. Mouth Mask
2. Surgical Gloves
3. Head Cap
4. Eye Protector
5. Drape
6. Mouth Mirror
7. Explorer
8. Straight Probe
9. Willams Granduated Periodontal Probe.
10. Tweezer
11. Cotton Holder
12. Cotton Receiver
13. Disposable Glasses
14. Dappen Dish – 02
15. Kidney Tray – 01
16. Supragingival Scalers (Set of 8)
17. Subgingival Scalers (Set of 7)
18. Universal Curettes 2R/2L,4R/4L
19. Contra- angle Micromotor Handpiece
20. Polishing Cup -02
21. Polishing Brush -02
22. Green Cloth (3) and Instrument Pouch (2)
23. Oral Hygiene Demostration Kit
    (Tooth Brush
    Floss
    Small Face Mirror
    Study Cast- Upper & Lower)

(Note :- All the above instruments are mandatory during posting and should be in working condition.)

Scanned by Scanner Go

Clinical Quota

THIRD B.D.S

Sr. No.	NATURE OF WORK	No.
1.	Demostations.	5
2.	Case History And Clinical Examination	5
3.	Seminars.	1
4.	Supragingival /Subgingival Scaling	20

Final B.D.S.

Sr. No.	NATURE OF WORK	No.
1.	Demostations.	5
2.	Case History And Clinical Examination.	20
3.	Supragingival /Subgingival Scaling and Root Paining	30
4.	Curettage/Surgical Assistance.	1
5.	Seminars.	1

Scanned by Scanner Go

Demonstrations

III B.D.S.

Sr. No.	Date	Topic	Staff Signature
1.	9/5/22	Principle of instrumentation	
2.	10/5/22	Principle of instrumentation	
3.	11/5/22	Instruments	
4.	12/5/22	Probe	
5.	17/5/22	chemical plaque control	

III B.D.S.

Sr. No.	Date	Topic	Staff Signature
1.	5/9/22	Instrument revision	
2.	6/9/22	Principle of instrumentation revision	
3.	7/9/22	mechanical plaque control	
4.	8/9/22	chemical plaque control	
5.			

Scanned by Scanner Go

Demonstrations

IV B.D.S.

Sr. No.	Date	Topic	Staff Signature
1.	15/3/23	case History discussion page 2	
2.	18/3/23	case History discussion page 3	
3.	23/3/23	case History discussion page 4	
4.	25/3/23	case History discussion page 5	
5.			

IV B.D.S.

Sr. No.	Date	Topic	Staff Signature
1.			
2.			
3.			
4.			
5.			

Scanned by Scanner Go

WORK DONE

Sr.No	Date	O.P.D.No	Name of work Done	Grade	Staff Signature
1	15/9/22	105039	~~ramdas~~ Full mouth		
			Scaling done		

Sr.No	Date	O.P.D.No	Name of work Done	Grade	Staff Signature
2	6/9/22	104658	Anterior		
			Scaling done		

Sr.No	Date	O.P.D.No	Name of work Done	Grade	Staff Signature
3	16/3/23	121819	Hand Scaling done		

Scanned by Scanner Go

WORK DONE

Sr.No	Date	O.P.D.No	Name of work Done	Grade	Staff Signature
4	18/3/23	112557	Anterior		
			scaling		
			done		

Sr.No	Date	O.P.D.No	Name of work Done	Grade	Staff Signature
5	21/3/23	122274	Anterior		
			scaling		
			done		

Sr.No	Date	O.P.D.No	Name of work Done	Grade	Staff Signature
6	24/3/23	122400	Full mouth		
			scaling		
			done		

Scanned by Scanner Go

WORK DONE

Sr.No	Date	O.P.D.No	Name of work Done	Grade	Staff Signature
7	2/8/23	134066	full mouth		
			hand scaling		
			done		

Sr.No	Date	O.P.D.No	Name of work Done	Grade	Staff Signature
8	5/8/23	82209	full mouth		
			hand scaling		
			done		

Sr.No	Date	O.P.D.No	Name of work Done	Grade	Staff Signature
9	7/8/23	134084	Anterior		
			Hand scaling		
			done		

Scanned by Scanner Go

WORK DONE

Sr.No	Date	O.P.D.No	Name of work Done	Grade	Staff Signature
10	5/8/23	134498	Full mouth		
			Hand scaling done		

Sr.No	Date	O.P.D.No	Name of work Done	Grade	Staff Signatur
11	9/8/23	134741	Anterior		
			Hand scaling done		

Sr.No	Date	O.P.D.No	Name of work Done	Grade	Staff Signatur
12	18/8/23	105465	Full mouth		
			Hand scaling done		

Scanned by Scanner Go

WORK DONE

Sr.No	Date	O.P.D.No	Name of work Done	Grade	Staff Signature
13	19/8/23	135733	Full mouth		
			hand scaling		
			done		

Sr.No	Date	O.P.D.No	Name of work Done	Grade	Staff Signature
14	19/8/23	135784	Full mouth		
			Hand scaling		
			done		

Sr.No	Date	O.P.D.No	Name of work Done	Grade	Staff Signature
15	21/8/23	135289	Full mouth		
			Hand scaling		
			done		

Scanned by Scanner Go

WORK DONE

Sr.No	Date	O.P.D.No	Name of work Done	Grade	Staff Signatur
16	22/8/23	135750	Full mouth		
			Hand scaling done		

Sr.No	Date	O.P.D.No	Name of work Done	Grade	Staff Signatur
17	24/8/23	102152	Full mouth		
			Hand scaling done		

Sr.No	Date	O.P.D.No	Name of work Done	Grade	Staff Signatu

Scanned by Scanner Go

CASE HISTORY

Sr. No.: **Year :**

Patient's Name : chetan jain **O.P.D. No.:** 2023/133357

Age : 39 yr **Date :** 12/8/23

Sex : male ~~pune~~ **Occupation :** job

Address: pune **Income:**

Chief Complaint :

patient complains of uncleaned teeth since 3-4 months

History of present illness :

patient was apparently asymptomatic 6 months back then started noticing yellowish discolouration of teeth & deposition on teeth. deposition increasing with time.

Past Dental History :

NRH

Past Medical History :

~~Presense~~ of renal calculus 1yr back Now relived on ~~its~~ own medication

Family History :

—

12/8/23

Scanned by Scanner Go

Personal History:

Oral hygiene habits:

1) brushes once a day
2) fluoridated tooth paste
3) No use of interdental aids
4) changes toothbrush every 2

Other habits :

NRH

Extra Oral Examination :

Symmetry of face : bilaterally symmetrical

Lips: competant

Lymph Nodes : non-palpable non tender

T.M.Joint: No deviation
No cliking sound

Intra Oral Examination :

Halitosis: present

Oral Mucous Membrane : Normal

Tongeue: Normal

Palate: Normal

Scanned by Scanner Go

Gingiva :

	Region	Colour	Contour	Consistency	Surface Texture	Size	Bleeding On Probing	Exudation
MAXILLARY	Anterior	Pale Pigment	Scalloped	Soft & oedematous	stippling Ab	Normal	Present	Ab
	Posterior	Pale pigmented	scalloped	firm & resilient	Present	Normal	Ab	Ab
MANDIBULAR	Anterior	Pale pigmented	scalloped	soft & oedematous	Ab	Normal	Present	Ab
	Posterior	Pale pigmented	Scalloped	firm & resilient	Present	Normal	Ab	Ab

Mucogingival Problems :

Absent

Frenal Attachment :

Upper : attached gingiva

Lower : mucosa

Width of attached Gingiva : **Adequate/Inadequate**

Tension Test -ve

Scanned by Scanner Go

Periodontal Pockets :

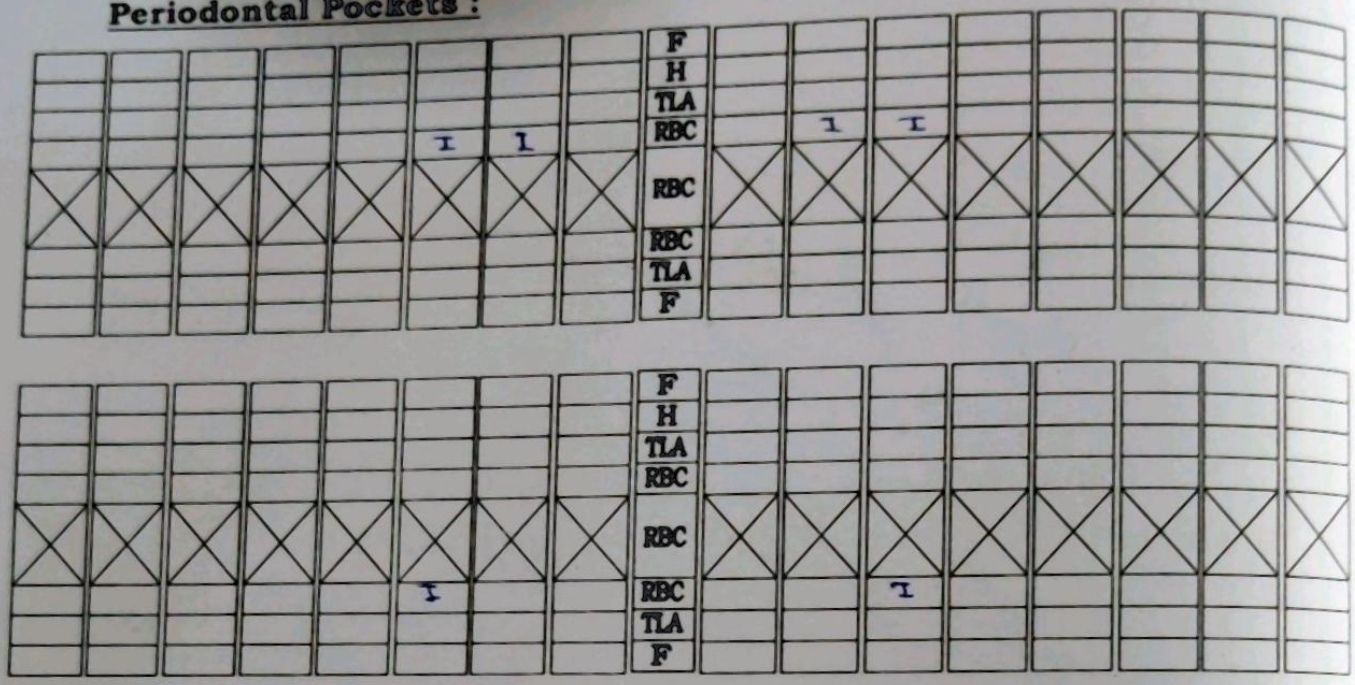

F- Furcation Involvement,

M- Mobility

TLA- Total loss of attachment,

REC- Recession, $\frac{\bar{C}\ 3\ 2 \mid 2\ 3}{3 \mid 3}$

PKT-Pocket

Scanned by Scanner Go

Examination of Teeth :

Teeth Present ; 7 6 5 4 3 2 1 | 1 2 3 4 5 6 7 8 / 8 7 6 5 4 3 2 1 | 1 2 3 4 5 6 7 8

Wasting Diseases : **Attrition** / **Abrasion** /**Erosion**

(Ab) (Ab) (Ab)

Carious Teeth : Ab

Restored Teeth: Ab

Faulty Restoration : Ab

Pathologic Migration: Ab

Drifting : Ab

Proximal Contacts : right

Food Impaction : Ab

Occlusion : class I malocclusion

Fremitus Test :

Teeth Deposits : **Plaque :** + **Calculus** ++ **Stains** ++

Hypersensitivity: Ab

Etiological Factors :

Local : -

Primary : plaque

Secondary : calculus, faulty brushing technique

Systemic : Ab

Scanned by Scanner Go

Investigations :

Laboratory :

Radiographic :

Diagnosis : chronic generalized diffused gingivitis

chronic localized mild periodontitis
C 12, 13, 22, 23 33 43

Prognosis :

Overall: good
as - NO systemic involvement
- Adquate maintainance posible

Individual:

Scanned by Scanner Go

Treatment Plan

Preliminary/ Emergency Treatment ;

Phase I :

1) Removal of calculus & Root planing
2) plaque control
3) oral Hygiene maintainance
4) use of interdental Aids

Phase II :

root coverage procedure

$\overline{C}$ 12, 13, 22, 23, 33 43

Phase III:

–

Phase IV: Recall after 3 months

Scanned by Scanner Go

INDICES

1. **Simplified Oral Hygiene Index (Greene & Vermillion 1964):**

DI-S		

CI-S		

OHIS Score Per Person:

Oral Hygiene Status : Good / Fair / Poor

2. **Plaque Index (Turesky- Gilmore Glickman, 1970)**

☒☒☒☒☒☒☒☒☒☒☒☒☒☒☒☒

☒☒☒☒☒☒☒☒☒☒☒☒☒☒☒☒

Plaque Score Per Person :

3. **Gingival Index (Loe and Silness 1963)**

☒☒☒☒☒☒☒☒☒☒☒☒☒☒☒☒

☒☒☒☒☒☒☒☒☒☒☒☒☒☒☒☒

Gingival Score Per Person :

Scanned by Scanner Go

CASE HISTORY

Sr. No.: **Year :**

Patient's Name : Abhishek das **O.P.D. No.:** 82209

Age : 36 yr **Date :** 5/8/23

Sex : male **Occupation :** Job

Address: lohegon pune **Income:** –

Chief Complaint : patient complains of ~~pain~~ uncleaned teeth since 3-4 months

History of present illness : patient was asymptomatic 3 months back then started noticing yellowing of teeth & deposits

Past Dental History :

NRH

Past Medical History : theatment taken for vitiligo (steroid)

- ongoing medication - calcium supplements

Family History :

NRH

Scanned by Scanner Go

Personal History:

NRH

Oral hygiene habits: Brushes once a day using toothb
Fluoridated paste
Changes brush every 23 months

Other habits :

NRH

Extra Oral Examination :

Symmetry of face : Bilaterally symmetrical

Lips: Competent

Lymph Nodes : non tender

T.M.Joint: No clicking sound

Intra Oral Examination :

Halitosis: Present

Oral Mucous Membrane : No Abnormality detected

Tongeue: NAD

Palate: NAD

Scanned by Scanner Go

Gingiva :

	Region	Colour	Contour	Consistency	Surface Texture	Size	Bleeding On Probing	Exudation
MAXILLARY	Anterior	Pale pink pigmented	scalloped	Firm & resilient	Stippling Present	normal	Ab	Ab
	Posterior	Pale Pink	scalloped	firm & resilient	Present	normal	Ab	Ab
MANDIBULAR	Anterior	Pale pink pigmented	scalloped	firm & resilient	Present	normal	Ab	Ab
	Posterior	Pale pink	scalloped	Firm & resilient	Present	normal	Ab	Ab

Mucogingival Problems :

Frenal Attachment :

Upper : mucosal

Lower : mucosal

Width of attached Gingiva : ✓ **Adequate/Inadequate**

Tension Test -ve

Scanned by Scanner Go

Periodontal Pockets :

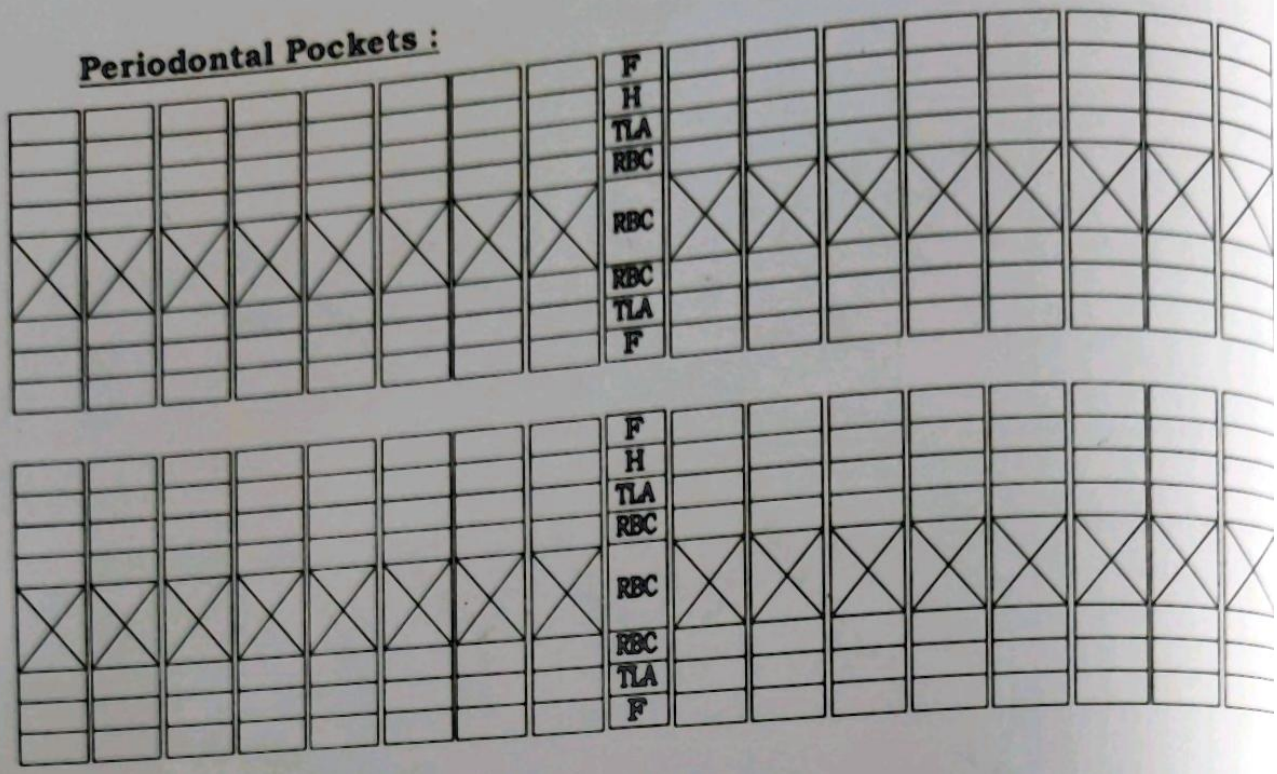

F- Furcation Involvement,

M- Mobility

TLA- Total loss of attachment,

REC- Recession,

PKT-Pocket

Scanned by Scanner Go

Examination of Teeth :

Teeth Present ;

Wasting Diseases : **Attrition / Abrasion /Erosion**

(Ab) (Ab) (Ab)

Carious Teeth : $\bar{C}$ 8 | 8 / 8

Restored Teeth: Ab

Faulty Restoration : –

Pathologic Migration: –

Drifting : –

Proximal Contacts : Altered contact $\bar{C}$ mandibular Anterior

Food Impaction : Ab

Occlusion : Class I malocclusion

Fremitus Test : –

Teeth Deposits : **Plaque :** + **Calculus** + **Stains** +

Hypersensitivity: present

Etiological Factors :

Local :

Primary : primary

Secondary : calculus, crowded teeth

Systemic :

–

Scanned by Scanner Go

Investigations :

Laboratory :

Radiographic : IOPA $\bar{C}$ $\frac{8}{8}$ | $\frac{8}{}$

Diagnosis : Chronic localized marginal gingivitis

Prognosis :

Overall: good as
as adequate maintainance poss
No systemic involvment

Individual: Hopeless $\bar{C}$ —|8
grossly decayed
cannot be restored

Scanned by Scanner Go

Treatment Plan

Preliminary/ Emergency Treatment ; extraction $\bar{c}$ 

Phase I : Removal of calculus & root planing
Temp restoration $\bar{c}$ 
minor ortho movement

Phase II :
(surgical)

—

Phase III:

final restration $\bar{c}$ 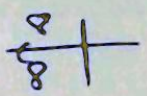

Phase IV: Recall after 6 months.

Scanned by Scanner Go

INDICES

1. **Simplified Oral Hygiene Index (Greene & Vermillion 1964):**

DI-S		

CI-S		

OHIS Score Per Person:

Oral Hygiene Status : **Good /** **Fair** **/** **Poor**

2. **Plaque Index (Turesky- Gilmore Glickman, 1970)**

☒☒☒☒☒☒☒☒☒☒☒☒☒☒☒☒

☒☒☒☒☒☒☒☒☒☒☒☒☒☒☒☒

Plaque Score Per Person :

3. **Gingival Index (Loe and Silness 1963)**

☒☒☒☒☒☒☒☒☒☒☒☒☒☒☒☒

☒☒☒☒☒☒☒☒☒☒☒☒☒☒☒☒

Gingival Score Per Person :

Scanned by Scanner Go

CASE HISTORY

Sr. No.: **Year :** 2023

Patient's Name : Harish prasad **O.P.D. No.:** 2023/ 135097

Age : 23 **Date :** 18/8/23

Sex : M **Occupation :** family business

Address: Bopkhel, pune **Income:**

Chief Complaint :
Patient complains of uncleaned teeth since 6 months

History of present illness :
patient was apparently asymptomatic 6 months back then started noticing yellowish discolouration of tooth & deposite on teeth

Past Dental History :
extraction done $\bar{c}$ 14

Past Medical History :
NRH

Family History :
NRH

Scanned by Scanner Go

Personal History:

Oral hygiene habits:

1) brushes once a day
2) use of Fluoridated toothpaste
3) use of mouth wash
4) change brush every 1 mont

Other habits :

↳ smoking since 3 yrs (30-40 a day)

Extra Oral Examination :

Symmetry of face : Bilaterally symmtrical

Lips: competant

Lymph Nodes : non palpable

T.M.Joint: No deviation present
No diking sound

Intra Oral Examination :

Halitosis: Present

Oral Mucous Membrane : Normal

Tongeue: Normal

Palate: Smoker's palate present

Scanned by Scanner Go

Gingiva :

	Region	Colour	Contour	Consistency	Surface Texture	Size	Bleeding On Probing	Exudation
MAXILLARY	Anterior	pink pigmented	Scalloped	firm & resilient	stippling present	Normal	Present	Ab
	Posterior	Pink pigmented	Scalloped	Firm & resilient	Present	Normal	Present	Ab
MANDIBULAR	Anterior	Pink pigmented	Scalloped	soft	Ab	Normal	Present	Ab
	Posterior	Pink pigmented	Scalloped	Firm & resilient	Present	Normal	Present	Ab

Mucogingival Problems :

Frenal Attachment :

Upper : mucosal

Lower : mucosal

Width of attached Gingiva : ✓ **Adequate/Inadequate**

Tension Test -ve

Scanned by Scanner Go

Periodontal Pockets :

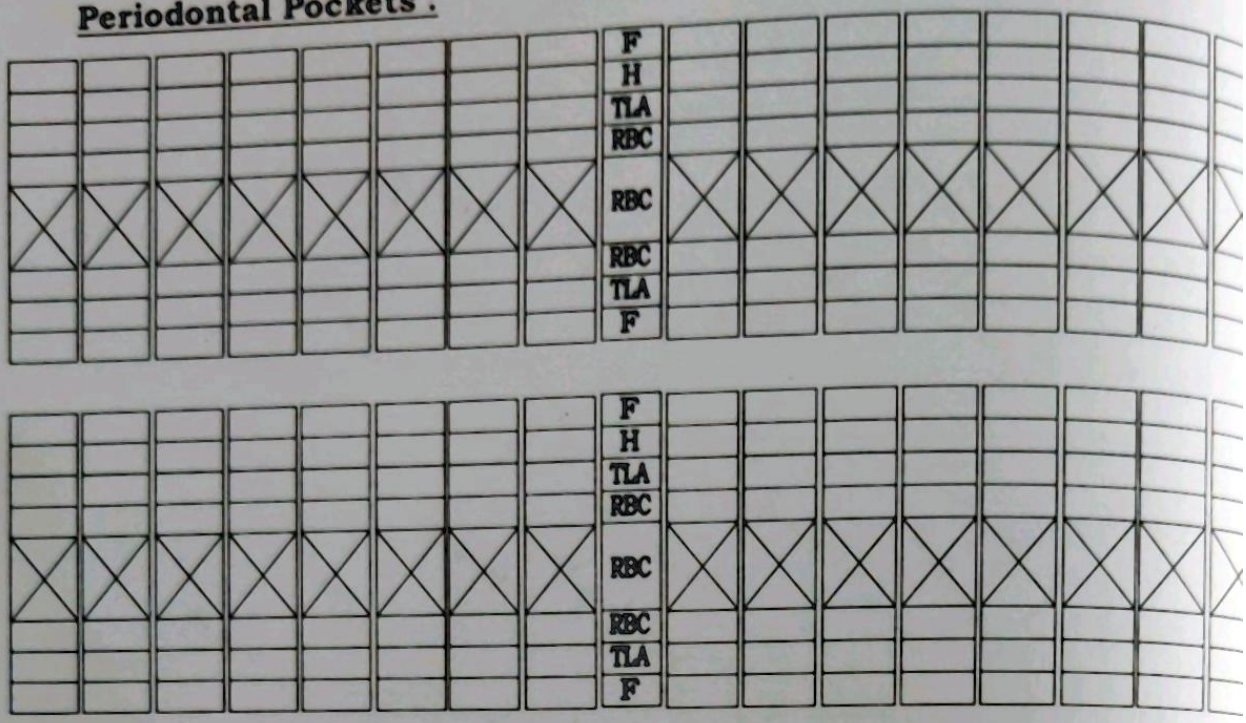

F- Furcation Involvement,

M- Mobility

TLA- Total loss of attachment,

REC- Recession,

PKT-Pocket

Scanned by Scanner Go

Examination of Teeth :

Teeth Present ;

7 6 5 3 2 1	1 2 3 4 5 6 7
7 6 5 4 3 2 1	1 2 3 4 5 6 7

Wasting Diseases : **Attrition** / **Abrasion** / **Erosion**

( ) ( ) ( )

Carious Teeth : Pit caries $\bar{c}$ 17, 26, 27

Restored Teeth: deep occlusal caries $\bar{c}$ 36
Cervical caries $\bar{c}$ 42

Faulty Restoration : Ab

Pathologic Migration: Ab

Drifting : Ab

Proximal Contacts : tight

Food Impaction : Ab

Occlusion : class I malocclusion

Fremitus Test : NO vibration

Teeth Deposits : **Plaque :** ++ **Calculus** + **Stains** +

Hypersensitivity:

Etiological Factors :

Local :

Primary : plaque

Secondary : - Calculus
- Faulty brushing technique
- caries

Systemic :

Ab

Scanned by Scanner Go

Investigations :

Laboratory :

Radiographic :

Diagnosis :

Prognosis :

Overall:

Individual:

Scanned by Scanner Go

Treatment Plan

Preliminary/ Emergency Treatment ;

Phase I :
- scaling, ~~root~~ plaing
- Plaque control
- modified bass method tooth brushing
- stoppage of smoking
- caries excavation $\overline{C}$ 17 26 27 42

Phase II :

endodontic therapy $\bar{C}$ 36

Phase III:

Final restoration $\bar{C}$ 36

Restoration $\bar{C}$ 17 26 27 42

Phase IV: Recall after 3 months

Scanned by Scanner Go

INDICES

1. **Simplified Oral Hygiene Index (Greene & Vermillion 1964):**

DI-S		

CI-S		

OHIS Score Per Person:

Oral Hygiene Status : Good / Fair / Poor

2. **Plaque Index (Turesky- Gilmore Glickman, 1970)**

☒☒☒☒☒☒☒☒☒☒☒☒☒☒☒☒
☒☒☒☒☒☒☒☒☒☒☒☒☒☒☒☒

Plaque Score Per Person :

3. **Gingival Index (Loe and Silness 1963)**

☒☒☒☒☒☒☒☒☒☒☒☒☒☒☒☒
☒☒☒☒☒☒☒☒☒☒☒☒☒☒☒☒

Gingival Score Per Person :

Scanned by Scanner Go

CASE HISTORY

Sr. No.: **Year :**

Patient's Name : Harshwardhan Pawar **O.P.D. No.:**

Age : 48 **Date :**

Sex : M **Occupation :** farmer

Address: lohegaon **Income:**

Chief Complaint : patient complains of uncleaned teeth since 2-3 months.

History of present illness : patient was asymptomatic 2-3 months back then started noticing yellowish deposition on teeth surface also noticed presence of Hard substance

Past Dental History :

NRH

Past Medical History :

NRH

Family History :

NRH

20/10/23.

Scanned by Scanner Go

Personal History:

Oral hygiene habits:

1) brushes once a day
2) use of Flouridated toothpa
3) changes toothbrush every 3 months

Other habits :

↳ smoking since 15-20 yrs once week. alcohol occasionally

Extra Oral Examination :

Symmetry of face : bilatally symmtrical

Lips: competant

Lymph Nodes : TN on palpable

T.M.Joint: No cliking sound

Intra Oral Examination :

Halitosis: ~~Bb~~ present

Oral Mucous Membrane : Normal

Tongeue: Normal

Palate: Normal

Scanned by Scanner Go

Gingiva :

	Region	Colour	Contour	Consistency	Surface Texture	Size	Bleeding On Probing	Exudation
MAXILLARY	Anterior	Pink	Scalloped	Firm & resilient	Normal stipling present	~~Hyper~~ normal	Ab	Ab
	Posterior	Pink	scalloped	Firm & resilient	Normal stipling present	Normal	Ab	Ab
MANDIBULAR	Anterior	Reddish Pink	scalloped	Firm & resilient	Normal stipling present	Normal	Ab	Ab
	Posterior	Pink	scalloped	Firm & resilient	Normal stipling present	Normal	Ab	Ab

Mucogingival Problems :

Ab

Frenal Attachment :

Upper : Mucosal

Lower : Attached

Width of attached Gingiva : ✓ **Adequate/Inadequate**

Tension Test -ve

Scanned by Scanner Go

Periodontal Pockets :

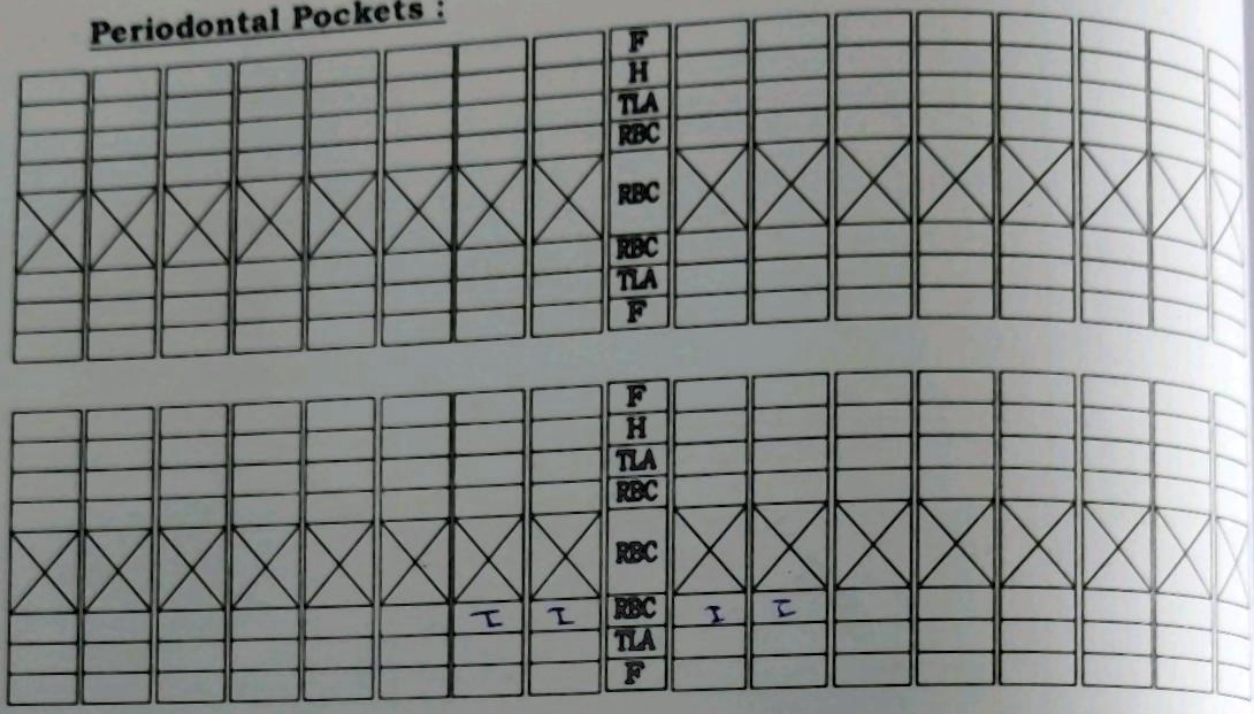

F- Furcation Involvement,

M- Mobility

TLA- Total loss of attachment,

REC- Recession, $\frac{\bar{C}}{29 \mid 12}$

PKT-Pocket

Scanned by Scanner Go

Examination of Teeth : 8 7 6 5 6 3 2 1 | 1 2 3 6 5 6 7 8
8 7 6 5 4 3 2 1 | 1 2 3 4 5 6 7 8

Teeth Present ;

Wasting Diseases : **Attrition** / **Abrasion** / **Erosion**

(Ab) (Ab) (Ab)

Carious Teeth : Occlusal fercet C 27

Restored Teeth: Ab

Faulty Restoration : Ab

Pathologic Migration: Ab

Drifting : Ab

Proximal Contacts : loose

Food Impaction : Ab

Occlusion : class I

Fremitus Test :

Teeth Deposits : **Plaque :** + **Calculus** ++ **Stains** +

Hypersensitivity:

Etiological Factors :

Local :

Primary : plaque

Secondary : calculus
Wrong tooth brushing Method

Systemic :

Ab

Scanned by Scanner Go

Investigations :

Laboratory :

Radiographic : EOPA $\overline{C}$ 4

Diagnosis : chronic generalized marginal gingi
Chronic localized mild Periodontitis
$\overline{C}$ 31, 32, 41, 42

Prognosis :

Overall: good
as- - No systemic involvme
- co-operative patient
- No pocket
- oral Hygiene maintain possible.

Individual: - No furcatn involvmet

Scanned by Scanner Go

Treatment Plan

Preliminary/ Emergency Treatment ;

Phase I :

- Oral Hygiene maintainance
- restoration ⊂ 17
- Plaque control
- modified bass toothbrushing.

Phase II :

Root coverage procedure

$\overline{C}$ 31, 32, 41, 42

Phase III:

—

Phase IV:

Recall after 3 month.

Scanned by Scanner Go

INDICES

1. **Simplified Oral Hygiene Index (Greene & Vermillion 1964):**

DI-S		

CI-S		

OHIS Score Per Person:

Oral Hygiene Status : **Good /** **Fair** **/** **Poor**

2. **Plaque Index (Turesky- Gilmore Glickman, 1970)**



Plaque Score Per Person :

3. **Gingival Index (Loe and Silness 1963)**



Gingival Score Per Person :

Scanned by Scanner Go

CASE HISTORY

Sr. No.:

Year :

Patient's Name : prajwal gawade

O.P.D. No.:

Age : 24

Date : 26/8/23

Sex : M

Occupation : Job

Address: dhanori

Income:

Chief Complaint : patient complains of bad breath since 2-3 months

History of present illness :

Patient was apparently asymptomatic 4 months back then started experiensing bad breath. while talking & in morning

Past Dental History :

~~NRH~~ extraction c̄ 6 | 6

Past Medical History :

NRH

Family History : NRH

26/8/23

Scanned by Scanner Go

Personal History:

Oral hygiene habits:

- brushes twice a day
- non-flouridated tooth paste
- changes brush every 1.5 month
- No use of interdetal Aid

Other habits :

LNRH

Extra Oral Examination :

Symmetry of face : bilotrally symmtrical

Lips: competant

Lymph Nodes : non palpable

T.M.Joint: No cliking sound, No deviation

Intra Oral Examination :

Halitosis: present

Oral Mucous Membrane : Normal

Tongeue: Normal

Palate: Normal

Scanned by Scanner Go

Gingiva :

	Region	Colour	Contour	Consistency	Surface Texture	Size	Bleeding On Probing	Exudation
MAXILLARY	Anterior	Reddish Pink	scalloped (rolled out marginal gingiva)	firm & resilient	stippling present	normal	present	Ab
	Posterior	pink	scalloped	firm & resilient	present	normal	Ab	Ab
MANDIBULAR	Anterior	Reddish Pink	scalloped (rolled out m. gingiva)	firm & resilient	present	normal	present	Ab
	Posterior	pink	scalloped	firm & resilient	present	normal	Ab	Ab.

Mucogingival Problems : Ab

Frenal Attachment :

Upper : attached gingiva

Lower : attached gingiva

Width of attached Gingiva : adequate

Adequate/Inadequate ✓

Tension Test -ve

Scanned by Scanner Go

Periodontal Pockets :

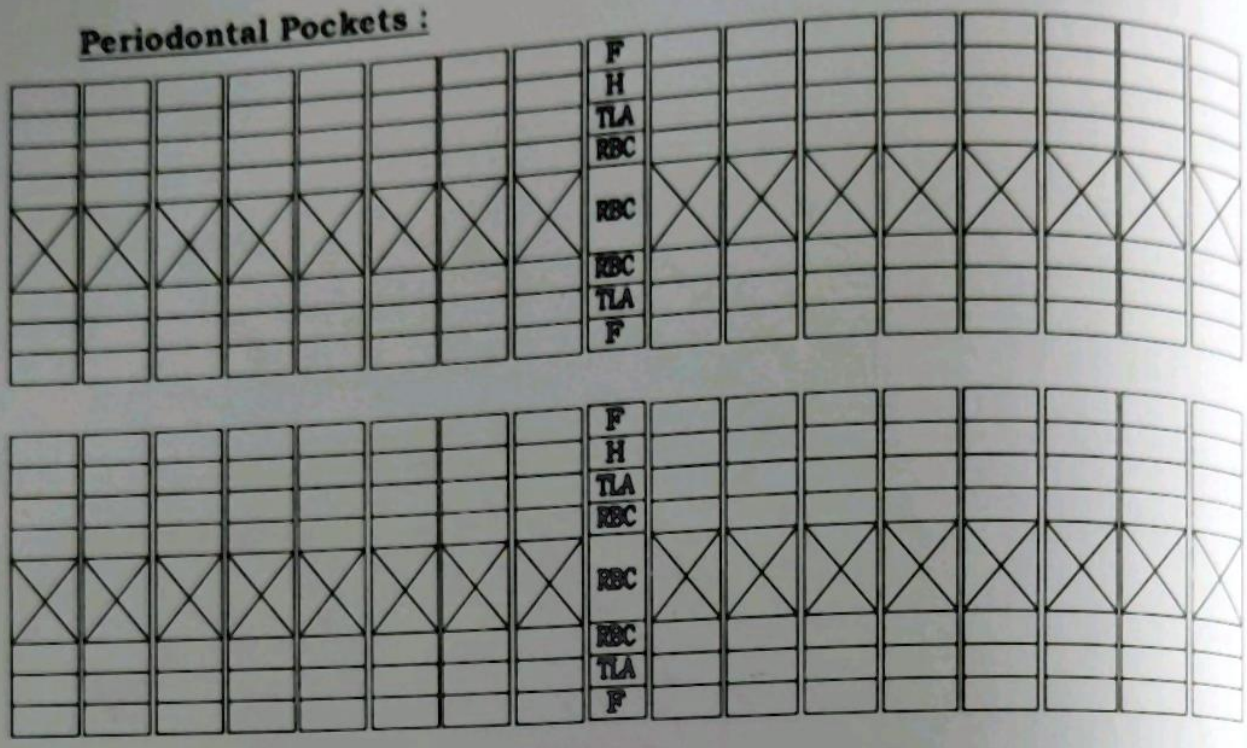

F- Furcation Involvement,

M- Mobility

TLA- Total loss of attachment,

REC- Recession,

PKT-Pocket

Scanned by Scanner Go

Examination of Teeth : 7 6 5 4 3 2 1 | 1 2 3 4 5 6 7
7 5 4 3 2 1 | 1 2 3 4 5 7

Teeth Present ;

Wasting Diseases : **Attrition** **/ Abrasion** **/Erosion**

(Ab) (Ab) (Ab)

Carious Teeth : Ab

Restored Teeth: Ab

Faulty Restoration : Ab

Pathologic Migration: Ab

Drifting : Ab

Proximal Contacts : open in maxillary Ant region

Food Impaction : –

Occlusion : class I

Fremitus Test : mild vibration

Teeth Deposits : **Plaque :** + **Calculus** + **Stains** +

Hypersensitivity:

Etiological Factors :

Local :

Primary : Plaque

Secondary : calculus, wrong brushing tech.

Systemic :

Ab.

Scanned by Scanner Go

Investigations :

Laboratory :

Radiographic :

Diagnosis : chronic generalized maegine gingivitis

Prognosis :

Overall: good

- No systemic involvment
- young age
- No CAL
- Adequate maintain posibl

Individual:

Scanned by Scanner Go

Treatment Plan

Preliminary/ Emergency Treatment ;

Phase I: - Oral prophylaxis
- Plaque control
- use of Interdental Aids
- use of mouthwash
- modified bass technique

Phase II :

Surgical

Implant $\bar{c}$ 

Phase III:

Implant $\bar{c}$ 

or

bridge $\bar{c}$ 

Phase IV:

Recall after 3 months.

Scanned by Scanner Go

Tutorials

Principles of Instrumentations

- effective instrumentation is governed by a no. of general principles of instrumentation that are common
- The basic principles of instrumentation are -

1) accessibility
2) visibility, illumination, retraction
3) conditioning and sharpness of instruments
4) maintainence of clean field
5) instrument stabilization → instrument grasp
   → finger rest.
6) Instrument → activation
   → adaptation
   → Angulation
   → lateral pressure
   → strokes.

1) Accessibility :-

- accessibility facilitates throughness of instruments
- The position of patient and operator should provide maximum accessibility to the area.

a) Neutral seated position for clinician :-
i) forearm parallel to floor ii) weight evenly balanced iii) Resting elbow should be at level of oval cavity iv) Thighs parallel to floor v) back straight and Head erect v) avoid positioning your legs under back of patient chin vi) four basic positions - 7'o clock, 9'o clock, 10-11'o dock 12'o clock.

b) patient position :-
for maxillary arch - chin up
for mandibular arch - chin down

2) visibility, illumination and retraction :-

- operator should preferably operation on patient with direct illumination.

Scanned by Scanner Go

Tutorials

- The light beam of dental chair lamp should be oriented parallel to viewing direction in order to obtain shadow form lighting.
- dental mirror is used for viewing tooth surface That cannot be seen by direct vision.
- Transillumination :- A mirror used for transillumination effective only with anterior because they are thin enough to allow light to pass through them
- Retraction :- mouth mirror is used to retract lips & cheeks while retracting cheeck with mirror The index finger of non operating hand should be used to protect angle of mouth.

3) Conditioning & sharpness of instrument :-
→ The working ends of pointed or bladed instrument must be sharp to be effective
→ methods to check instrument sharpness
a) glare test : sharp cutting edge does not reflect light but dull edge reflects light.
b) acrylic test :
c) clinincal performance :
d) comparing with new instruments :
→ Advantage of sharp instrument :-
- easier calculus removal
- improved stroke control
- Reduced no. of stroke
- increased patient comfort
- Reduced clinical fatigue.

4) Maintaining clean, dry Field :-
- adequate suction is essential & can be achieved with saliva ejecter or an aspirator.
- blood and debries can be removed using suction by wiping and blotting with guare square.
- compressed air & ~~guage~~ guare can be used to facilitate visual inspection of tooth surfaces just below gingival margins during instrumentation.

Scanned by Scanner Go

Tutorials

5) Instrument stabilization :—

- Stability of instrument & hand is primary requisite for controlled and effective instrumentation and avoidance of injury to patient or clinician.

a) Instrument grasp :—

i) modified pen grasp - most effective and stable modification of standard pen grasp, ensures contact in performing instruments procedure, The thumb, index finger & middle finger is positioned so that side of pad next to finger nail is resting on instruments shank The index finger is bent at second joint from finger tip and is placed midway between middle finger & index finger. which creates tripod effect. it enhances control and tactile sensitivity.

ii) palm & Thumb grasp - used for stabilizing instrument during sharpening and for manipulating air water syringe.

b) Finger rests :—

Finger rest serves to stabilize hand and instrument by providing a fulcrum as movements are made to activate the instrument

classification → intra oral finger rests
→ extra oral finger rests.

Modified pen grasp : —

??

Scanned by Scanner Go

Tutorials

① intra-oral finger rest :—
- i) conventional - adjecent teeth
- ii) cross arch - rest on other side of same arch
- iii) opposite arch
- iv) finger on finger - stabilizing the finger on index finger or thumb of non-operating hand.

② Extra-oral :—
- palm up
- palm down

- Both intraoral and extraoral fulcrums may be reinforced by applying index finger or thumb of non-operating hand to the handle of istrument for added control & pressure against

6) Instrument Activation :—

A) adaptation :—
- it refers to manner in which working end of periodontal instrument is placed against surface of tooth.

objective of adaptation is to make working end of instrument conform to the contours of tooth surface. if an instrument is adapted so that only tip is in contact. the soft tissue can be compressed by working end also causing trauma & discomfort

B) Angulation :—
Refers to an angle between face of bladed instrument and the tooth surface it may also be called tooth blade relationship
- for subgingival insertion, angulation should be close to 0°

C) lateral pressure :— it may be firm, moderate or light often removing calculus lateral pressure is initially applied firmly or moderately and is progressively diminished until light lateral Pressure is applied for final root planing.

D) strokes :—
- i) exploratory
- ii) Scaling
- iii) Root planing.

Scanned by Scanner Go

Tutorials

i) exploratory stroke :- it is light stroke that is used with probes & explorers to evaluate and dimension of packts and to detect calculus & irregularities of tooth surface.

ii) scaling stroke :- Short powerfull pull stroke i.e used with bladed instruments for the removal of both supra and subgingival calculus. The muscles of finger and hand are tensed to establish a secure grasp and lateral presure establish against tooth surface.

iii) Root planing stroke :- moderate to light pull stroke that is used for final smoothning and planing of root surface.

Scanned by Scanner Go

Tutorials

Mechanical Plaque Control

- plaque control is the regular removal of microbial plaque and preservation of its accumul on teeth and adjecent gingival surface. it is also called as oral physiotherapy

plaque control
- mechanical
  - Brushes
    1. Natural
    2. synthetic
    - manual
    - powered
  - Interdental Aids
- chemical

① Toothbrushes :—

The first toothbrush was made by william Addis in england 1780. The handle was carved from bone and brush from sesume bristles

- Toothbrush design :—

ADA specification - 11g

- width - 3/8 or 5/16 inches
- length - 1 - 1 1/4 inches
- 5-12 rows of tufts
- 80-86 ~~tufts per~~ bristle per tuft
- Diameter
  - 0.07 inches - soft
  - 0.012 inches - medium
  - 0.014 inches - hard

Bristle hardness is directly proportional to square of diameter and inversly proportional to square of bristle length.

* Powered toothbrushes :—

- 1st created in switzerland 1937
- These have oscillating and rotating motion low frequency acoustic energy to enhance cleaning ability
- most commonly used in Hosptilaried patients children & physically & mentally disabilities patient with ortho 1961 treatment. appliances.

Scanned by Scanner Go

(2) Dentrifrices :—
- aids in cleaning and polishing tooth surface dentrifrices ingredient helps in reducing calculus plaque, gingivitis, stains.

component	composition		material	purpose
	paste	powder		
Abrasive	20-25%	90-95%	- calcium carbonate dibasic ca silica	Remove plaque, stains, polishes tooth surface
detergent	1-2%	1-6%	- sodium lacryl swphate	Aids in debries removal by ↓ surface tension
colourants	1-2%	1-2%	Food colour TiO_2, Mica	used for coloured apparence.
Flavouring agents	1-2%	1-2%	Oil of menthol sorbitol, papermint	provides, flavours
tants	20-30%	0	sorbitol, glycecin	moisture
ret	3%	0		act as suspension
Binder	3%	0	xantham gum synthetic cellulose	maintain viscocity
Flourides			sodium flouride	Prevents caries
Theruputic agents				
Tartar control	0-1%	0	Trisodium pyrophosphate	inhibit formn of calculus.

Toothbrushing Methods :—
1. Horizontal - Scrub technique
2. vertical - leonard technique
3. circular - fones technique
4. Horizontal & vibratory — stillman's, charter, & bass tech.

• Modified bass technique :—
- also called as sulcus cleaning tech.
Indication - intrasulcular cleaning or routine oral Hygiene method.
Technique - Toothbrush is held in such a way that bristles are at 45° to gingiva Bristles are gently vibrated by moving the brush back & forth

Scanned by Scanner Go

The bristles are then moved over side of tooth towards their occlusal surfaces in single motion in vertical direction.

Advantage → excellent sulcus cleaning
good interproximal and gingival cleaning
good gingival stimulation

disadvantage → dexterity of wrist is required

* Modified stillman's technique :-

Indication → For massaging gingiva in cases of gingival recession, dental plaque removal from below Height of contour of enamel & from exposed proximal surfaces.

Technique :- bristles are pointed apically with an oblique angle to the long axis of tooth bristles are positioned partly on adjecent gingiva activated by short back & forth motion & simultaneously moved in coronal direction. 20 strokes

disadvantage : Time consuming
improper brushing can damage epi. attachment.

* charter's method :

Indication → periodontal surgeries to promote Healing & massaging
Indivisual having open interdental spaces
Technique - soft multitufted toothbrush is indicated for this technique
Advantage - massage & stimulation for marginal & interdental gingiva.

Interdental cleaning Aids :-

classification :
based on type of embrasures

Type I → embrassure with no interdental gingival recession are adequetly cleaned using floss
Type II → longer surface with rounded interdental papillae and requires use of interproximal brushes
Type III → excessive recessed gingiva i.e. in diastema or exposed root furcation. Unitufted brush are used

Dental Floss - any toothbrush regardless of method does not completely remove plaque biofilm
Hence interdental aids necessory
a) monofilament or multifildment
b) waxed or unwaxed
c) Twisted or non-twisted.

Scanned by Scanner Go

Tutorials

Oral irrigation :- aqua flosses are dental water jet has shown to significantly reduce gingivitis, BOP and periodontal pathogens
- either water or antimicrobial agents are used
MOA - works on basis of Hydro kinetic energy
Impact zone on which solution initially comes in contact with tooth surface
Flushing zone in which soln reaches subgingival sulcus & cleans it.
clinical outcome - improved removal of plaque biofilm and reduction in calculus, gingivitis & BOP.

19/1/24

Chemical plaque control

- it is an adjunct to and not a substitute to mechanical plaque control

an ideal chemical plaque control agent should have properties like
① substantivity - ability to bind to tissue surface - relesed over time.
② penetrability - ability to penetrate deeply into biofilm.
③ selectivity - Ability to affect spefic bacteria in mixed popul

factor affecting to delievet clearence of plaque control agents from oral cavity.
1) stability of active agents
2) Bio avalibility
3) accessibility of site of action
4) Interaction between agent receptor site.

Classification :

A) 1st generation
i) phenolic compound
- phenol
- Thymol
- Triclosan
- Listerine
- ethyl resorcinol
ii) quaternary ammonium c.
- ethyl pyridinium fluoride
- Benzothonium chloride
iii) Antibiotic
- vancomycin
- kanomycin

B) 2nd generation
i) Bis-biguinides
- chlorohexidine
- Alexidine
ii) Hydrochlorides
iii) chlorhexidine

C) 3rd generation
- delmopinol

D) 4th generation
- probiotics

Scanned by Scanner Go

Halogens -
- Iodine
Metallic ions -
- zinc
- copper
- Tin
- silver
- mercury
Antiplaque enzyme
- mucinase
- mutanase
- dextranase
oxidising Fluorides

3) chlorhexidine rinse :—
- This agent has shown most positive antibacterial results prescribed as twice a day with 10 ml of 0.2 % aqueous solution of chlorhexidine digluconate It has completely inhibited dental plaque. calculus, gingivitis, it has a broad antimicrobial spectrum.

mechanism of action :—
at low concentration it causes leackage of intracellular potassium and reduction in bacterial Add production. Bacteriostatic at High concentration it causes bacterial cell wall disruption and coagulation of cytoplasmic constituents
It has also inhibited enzymes involved in bacterial adhesion, bacterial growth & metabolism

Side effects :—
-it has reversible side effects, the teeth, tongue & silicate resin restoration.
Impairement of tastes -
it has low systemic toxicity
anti plaque action of chlorhexidine
preventing pellicle formation by blocking Acid group on salivary glycoprotein
Preventing adsorption of bacterial cell wall to tooth surface
Preventing binding of plaque by precipitation agglutination factors.

Scanned by Scanner Go

Tutorials

Periodontal Probes.

- periodontal probes are used to measure depth of pockets and determine their configuration
- typical probe is tapered, rod like instrument caliberated in milimeters, with round, blunt end

* Types of periodontal probe :—

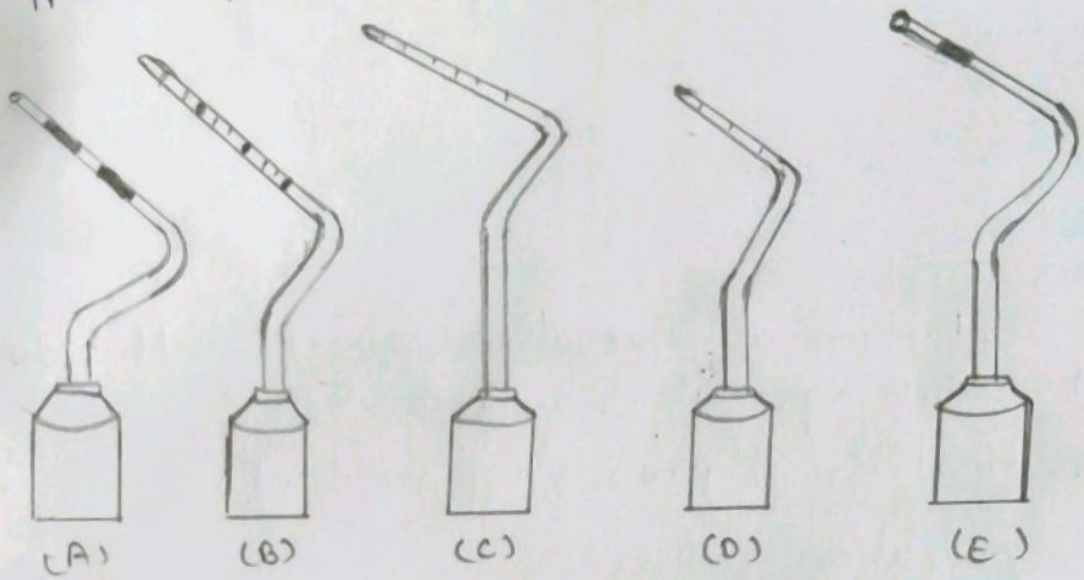

A) Marquis colour coded probe :—
- caliberated at 3 mm sections

B) University of North carolina - 15 (ULC - 15) probe :—
- A 15 mm long probe
- milimeter markings at each mm
- colour coding at 5, 10 & 15.

C) university of michigan "o" probe :—
with williams marking at 1, 2, 3, 5, 7, 8, 9 & 10

D) Michigan "o" Probe with markings at 3, 6 & 8 mm.

E) WHO probe :—
- it has 0.5 mm ball at the tip & milimeter markings at 3.5, 8.5 & 11.5 mm & colour coding From 3.5 to 5.5 mm

Scanned by Scanner Go

Tutorials

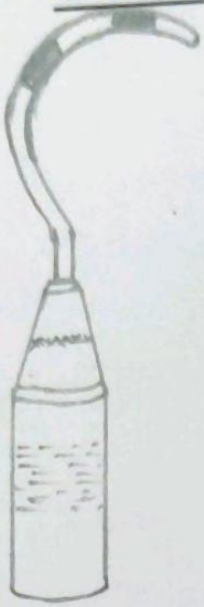

* Naber's probe :-
  - for detection of furcation areas with colour codeed markings at 3, 6, 9, & 12 mm.

* classification of probes (generation) :-

① First generation probes :-
  - conventional & Hand held probes eg- WHO probe, Nabers probe.

② Second-generation probes :-
  - pressure sensitive probes.

③ Third-generation probes :-
  computerised probes - eg. Florida probe, Foster miller Probe.

④ Foueth generation probes :-
  3-dimensional probes.

⑤ Fifth generation probe :-
  - ultrasonographic probes

Scanned by Scanner Go

classification of periodontal instruments :—

- peridontal instruments are designed for specific purposes such as removing calculus, planing root surface, curetting gingiva & removing diseased tissue.

* classification :—

1) Periodontal probe :—
   - To locate, measure & mark pockets.

2) Explorers :—
   - To locate calculus deposites & caries)

3) Scaling, Root planing & curettage instruments :—
   a) sickle scalers
   b) Curettes
   c) Hoe, chisels, file scalers
   d) Ultrasonic & sonic instruments

4) Periodontal endoscope :—

5) cleansing & polishing instruments :—

* Parts of instruments :—
   - Periodontal instrument composed of
     ↳ i) Blade
       ii) shank
       iii) Handle.



Periodontal Probe

Scanned by Scanner Go

Tutorials

* Mouth mirror :-
  - it is a diagnostic instrument with a reflective mirrored surface on the working end

* Uses :-
  i) indirect vision :
     - To view a tooth surface or intraoral structure that cannot be seen directly
  ii) Retraction : use of mirror Head to hold Patient's cheek, lip or tongue for better view
  iii) indirect illumination :- To reflet light onto a tooth surface where it is needed.
  iv) Transillumination :- Technique of directing light off the mirror surface through anterior teeth.

* classification of mouth mirror :-
  a) Front surface :- reflecting surface is a front surface of glass. that produces clear image with no distortion & good image quality. it is expensive & can be easily damaged
  b) plane surface :-
     - reflecting surface is a back surface of mirror lens & produces (ghost) double image which can be distracting.
  c) concave surface :- Reflecting surface is concave front surface mirror that shows magnified image may lead to distortion

* explorers :-
  - used to locate calculus, deposites & caries
  - also used to locate subgingival deposites & check the smoothness of root surfaces after root planing.
  - explorers are designed with diff shapes and angles for a variety of use according to its needs.

Scanned by Scanner Go

Tutorials

* Scaling, root planing & curettage instrument:-
- used for removal of biofilm & calcified deposites from crown, root. removal of altered cementum from subgingival root surface & debridment of soft tissue lining pocket.

• They are classified as below :—

1) Sickle scaler :—
- Have a flat surface & two cutting edge.
- converge in sharply pointed tip
- 1° used to remove supragingival calculus.

2) Curettes :—
- These are fine instrument used for subgingival scaling, root planing & removal of soft tissue lining of pocket.

3) Hoe, chisel & file scaler :—
- used to remove tenacious subgingival c.
- use is limited as compared to chisel.
- Hoe scalers are used for scaling of ledges or rings of calculus
- chisel for proximal surface of teeth
- Files used to fracture/crush calculus

* Ultrasonic & sonic instruments :—
- used for scaling & cleaning of tooth surface
- & curettage the soft tissue wall of pocket.



Parts of Instrument

Scanned by Scanner Go

Tutorials

IV periodontal endoscope :—

- A dental endoscope has been introduced for use subgingivally in the diagnosis and treatment for periodontal disease.
- This device allows clear visualization deeply into subgingival pockets & furcation it permit operater to detect subgingival deposits & guide them in through removal of this deposits.

V cleansing & Polishing instruments :—

- This category consist of

a) Rubber cup :—

They consist of rubber shell with or without webbed configurations in the & Hollow interior.

- They are attached to the handpiece and a good cleansing & polishing paste that contain fluoride is wed to keep rubber cups & minimize frictional Heat

b) bristle brushes :—

- These are avalible in wheels & cup shape.
- since ~~are~~ the bristles are stiff, the brush should be confined to the crown to avoid injury to the cementum.

c)

1100 / 1645

Scanned by Scanner Go

c) dental tapes :—
- used with polishing paste. used to polish Proximal surfaces that are inaccessible to other polishing instruments

d) Air-power polishing :—
A specially designed handpiece is used to delievet an air powered slurry of water and sodium bicarbonate for polishing
- it is effedive in remaining extrinsic stain.

VI Surgical Instruments :—
periodontal surgery accomplished by various instruments

a) excisional & incisional instruments
eg.
- periodontal knives.
- interdental knives
- surgical blades

b) surgical curettes & sickles
c) periosteal elevators
d) surgical chisels

five basic scaling instruments

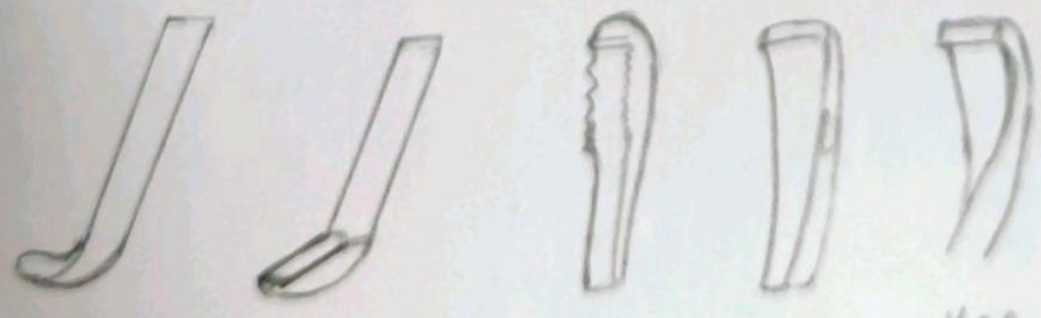

Scanned by Scanner Go

Tutorials

Curettes

- The curettes is the instrument of choice for removing deep subgingival calculus, root planing, altered cementum & removing soft tissue lining the periodontal pocket
- each working end has a cutting edge on both sides and a rounded toe.
- The curettes is finer than sickle scaler and does not have any sharp point or corners. other than cutting edge of blade
- Therefore curettes is finer than sickle scaler can be adopted and provide good access to deep pockets. with minimal soft tissue trauma

There are two types of curettes :—

— 1) universal 2) Area specific.

① universal :—

- have cutting edges that may be inserted in most areas of dentition by altering and adapting finger rests, fulcrum & Hand position & operator.
- The blade size & angle & length of shank may vary. but face of blade of every universal curette is at 90° angle (⊥) to lower shank. when seen from cross section from tip.

eg. 1) The Barnart curettes 1-2 & 5-6

2) columbia curettes 13-14, 2R-2L 4R-4L

3) younger good 7-8 mccall's 17-18

4) Indiana university 17-18

Scanned by Scanner Go

Tutorials

Basic characteristics of curettes :—
spoon shaped blade & rounded tip

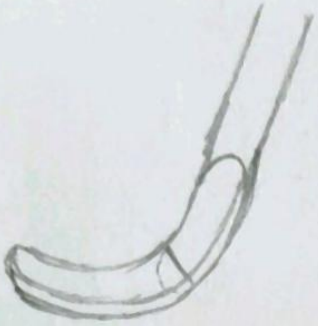

Basic characteristics of a curette.

specification	Gracey Curette	universal Curette
area of use	set of many Curette designed for specific area & surface	one curette designed for all areas & surfaces
cutting edge use	one cutting edge used. work with outer edge only	Both cutting edges either outer or inner used
curvature	curved in two planes blades curves up & to the side	curved in ~~two~~ one plane blades curves up not to the side
Blade angle	offset blade, face of blade beveled at 60° degree to shank	Blades not offset face of blade beveled at 90° TO shank.

Scanned by Scanner Go

Tutorials



Curette instead in pocket in a position of the base of a pocket on the distal surface of mandibular molar

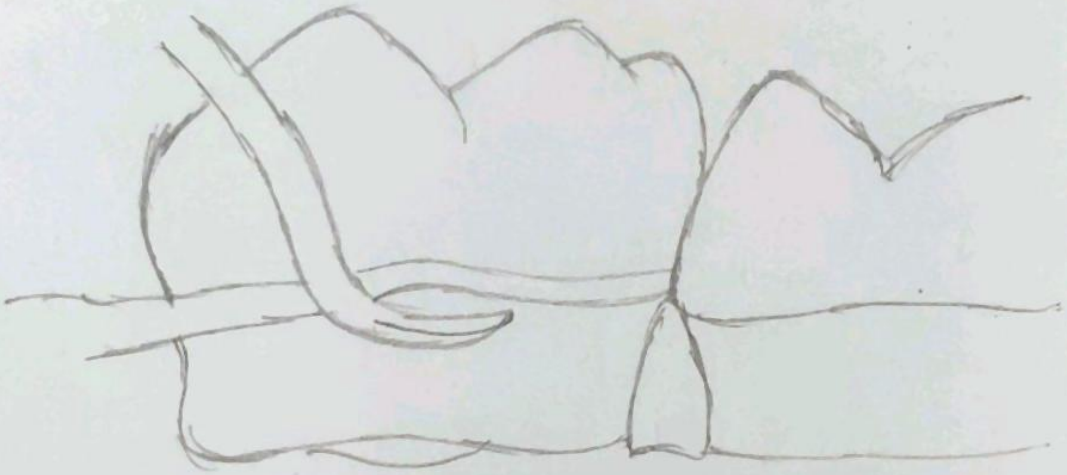

Curette inserted in a pocket with the tip directed apically.

micromini five gracey curettes

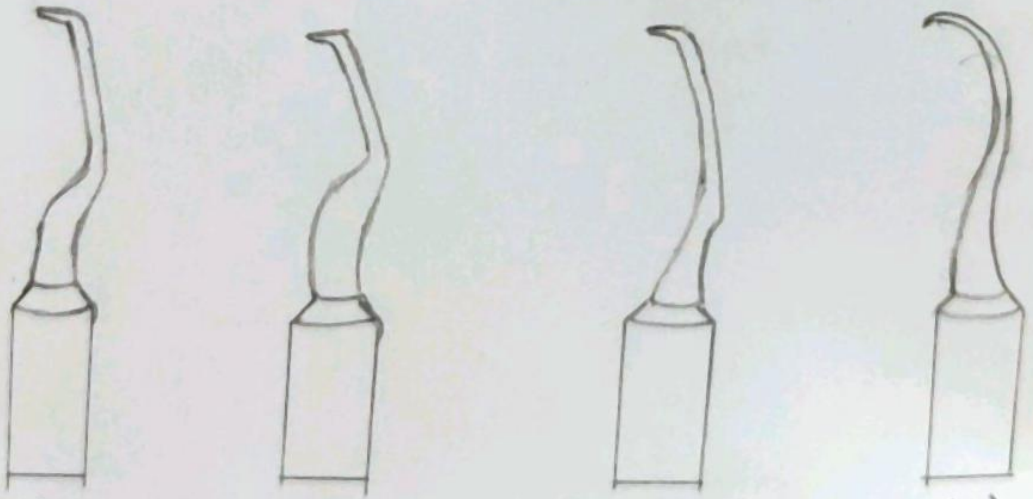

Scanned by Scanner Go

Tutorials

Modification of curettes :—

1) extended shank curettes (after 5 curettes) :—
- The terminal shank is 3 mm longer allasing extension in deeper periodontal pocket of 5 mm ormore.

Rigid design :— for heavy calculus removal
finishing design : light scaling or deplaquing

2) mini bladed curettes :— (mini five)
- The blades are half of the length of standard curettes.
- short blade allows easier insertion odaptation in deep, narrow pockets furcation developmental grooves, line angle & deep tight pockets.

3) Micro mini five Gracey curettes :—
- Their blades are 20% thinner & smaller than mini five curettes
- These are smallest of all five curettes & provide exceptional access to tight, deep or narrow pockets

4) Gracey curettes :— (set of 4 minibladed curettes)
- The blade length 50% shorter than conventional & Gracey curettes & blade is curved slightly upword.

Scanned by Scanner Go

Tutorials

This curvature allows Gracey curettes To adopt more closely to tooth than any other curettes.

5) periodontal maintenance curette
(most recent → november 2015)

- The blade is 1mm shorter & 20% thinner & face of blade is offset from terminal shank at 60° (other gracey designs offset at 70°)

- These are used for patient with tight tissue, recession & residual pocket depth following initial periodontal therapy or periodontal surgery

6) Langer & mini langer curettes (set of 3)
- The universal blade is honed at 90° angle rather than offset blade of Gracey Curettes

- This marriage of Gracey & universal curettes design allows advantages of area specific shank to be combined with versatility of universal curette blade.

10/1/24

Scanned by Scanner Go

CASE HISTORY

Department of Conservative and Endodontics

CASE HISTORY

DEPARTMENT OF CONSERVATIVE DENTISTRY AND ENDODONTICS

CASE RECORDS

Diagnosis & Treatment planning in Conservative Dentistry

Name of the patient: Kavita Purane

Age: 24/F

Registration No.

Address: Moshi, Pune

Date: 24/7/23

Tel. No. 8378981991

Gender: Female

Occupation: House-wife

Emergency Contact: —

DENTAL RECORD

Chief Complaint: Patient Complains of Pain in upper front teeth region of jaw since a day.

History of present illness: Patient was appearantly asymptomatic 1 day prior, until she started experiencing Pain in upper front teeth region of jaw. The Pain was Continuous, throbbing and aggravated on Cold Consumption. H/o swelling absent. No H/o night Pain. H/o Trauma 1 day back. Pain was relieved on taking medications.

Past Dental Experience:

Incomplete root canal treatment c 12/
(3 years ago)

Subjective symptoms:

Tooth / Region – 1

Pain:	Present		Absent	
Location:	Localized	Diffused	Referred	Radiating
Duration:	Seconds	Minutes	Hours	Constant
Quality:	Sharp	Dull	Throbbing	
Onset:	Stimulated	Spontaneous		
Increased by:	Cold	Heat	Pressure	Mastication
	Postural Change	Sweet	Sour	Others
Relieved by:	Cold	Heat	Medication	

Medical History: – No relevant History

A) Record of any present illness:

i) Cardiac disease – None

- Anginal / Coronary
- Pacemaker
- Congenital heart disease
- Rheumatic fever

ii) Abnormal bleeding – None

- Blood dyscrasias

iii) High blood pressure – None

iv) Anemia

v) Diabetes

vi) Hepatitis

vii) AIDS / HIV

viii) Asthma

ix) Tuberculosis

x) Arthritis

xi) Sinus trouble

xii) Epilepsy

xiii) Stroke

xiv) Psychiatric treatment

xv) Cancer treatment / Radiation therapy

B) Any medicines or drugs taken in the past or current medication – No

C) Allergy to any drug/drugs – No

D) Any prosthesis inserted into the body – No

E) Any Surgery in the past with or without blood transfusion – No

F) For Women Pregnancy Y/N

Nursing Y/N

G) Any other relevant findings – No

EXAMINATION

A) General Examination:

Built – Average

Stature – Normal

Gait – Normal

Posture – Erect

B) Extraoral Examination:

- Symmetry – Bilaterally symmetrical
- Swelling: – Absent Hard Soft Diffused Localized
  Dimension and extent
- TM Joint – No abnormality
- Lymph nodes – Non-Palpable
- Sinus/Fistula – Absent

C) Intraoral examination

i) Soft tissue examination: No abnormalities seen

Tongue Mucosa Palate Floor of mouth Gingiva

ii) Swelling: Present ~~Absent~~

iii) Sinus tract opening: – Absent

iv) Oral hygiene: Good Fair Poor

v) Occlusion: ~~Harmonious~~ Non-harmonious

CLINICAL EXAMINATION OF AMALGAM RESTORATIONS:

Amalgam blues –
Proximal overhangs –
Marginal ditching –
Voids –

} No relevant Findings

Fracture lines – Vertical fracture line seen on Clinical Crown over labial aspect

Improper anatomic contours –
Marginal ridge incompatibility –
Improper proximal contacts –
Recurrent caries –
Improper occlusal contacts –

} No relevant findings

CLINICAL EXAMINATION OF CAST RESTORATIONS

⇨ **Defective, Proximal overhang, Improper contours, Fractured tooth/Restoration, Secondary caries.**

CLINICAL EXAMINATION OF TOOTH COLORED RESTORATION.

1) Improper contour
2) Proximal contact
3) Overhanging proximal margin
4) Recurrent caries
5) Marginal staining.
6) Fracture

} No relevant Findings

EXAMINATION OF NON-CARIOUS LESIONS

ATTRITION
ABRASION
EROSION
ABFRACTION

} No relevant Findings

EXAMINATION OF AREA OF CHIEF COMPLAINT:

a. Tenderness on palpation - Absent

b. Pain on percussion - Absent

c. Mobility - Grade I mobility ō +ⁱ

d. Furcation involvement - Absent

e. Pulp vitality tests - Not relevant

Thermal test: Heat Cold

i. No response
ii. Moderate transient response
iii. Painful response which subsides quickly after removal of stimulus
iv. Painful response that lingers after removal of stimulus

f. Electric pulp test

	Control tooth	Test tooth
	Response at number	Response at number

Caries Diagnosis:

1. Clinical Examination for caries:
   a) Visual changes - Surface Texture - Distinct cavity $\bar{C}$ visible Dentin
   - Colour
2. Tactile sensation
3. Radiographs Involving Pulp
4. Transillumination. Dark shadow Seen in occlusal & Distal aspect

Categorization of Adults According to Caries Risk indicators:

Caries Risk Category

Low: - No carious lesions in last 3 years.

Adequately restored surfaces

Good oral hygiene

Regular dental Visits

Fluoride dentifrice use

Medium: -

Presence of two of the following indicators:

Current orthodontic treatment or removable appliance or several exposed root surface or poor oral hygiene or frequent fermentable carbohydrate intake or inadequate exposure to topical Fluoride.

High:- Presence of one of the following indicators:

Any carious lesion in previous 2 years or inadequate salivary flow or initial enamel interproximal radiolucencies or presence of >2 of the risk indicators shown in the medium risk category.

Provisional Diagnosis:

Previously initiated therapy $\bar{c}\,\frac{|12}{|}$

Investigations and interpretations :

i) Radiographs: Intraoral periapical $\bar{c}\,\frac{|12}{|}$

Teeth Completely seen - 21, 22

Teeth Partially seen - 11, 23

Bitewing Tooth of interest - 21

Crown - Acces opening $\bar{c}$ 21

Vertical fracture line along entire length of

O.P.G. Crown of 21

Root - Pathologic root resorption in apical

Any other third and half of middle third of root; Fracture line extending in Coronal third of root.

PDL space widening seen $\bar{c}\,\frac{|2}{|}$

No Peri-apical radiolucency seen $\bar{c}\,\frac{|12}{|}$

ii) Blood tests: —

iii) Any other: —

Final Diagnosis:

Pulpal

Reversible
Irreversible

Periapical Pathology:

1) Acute apical periodontitis
2) Chronic apical periodontitis
3) Periapical granuloma
4) Periapical cyst
5) Acute dentoalveolar abscess

Vertical Crown - Root Fracture c̄ | 1

Previously initiated therapy c̄ | 2

Prognosis: Fair

Treatment Plan:

xxxi) **Urgent phase**

Splinting using Composite Resin $\bar{c}$ $\frac{|12}{|}$

Refining of Access opening $\bar{c}$ $\frac{|12}{|}$ and Bio-mechanical Preparation $\bar{c}$ Placement of intra Canal Medicament

xxxii) **Control phase**

Oral Prophylaxis

xxxiii) **Re-evaluation phase**

Evaluation $\bar{c}$ $\frac{|12}{|}$

xxxiv) **Definitive phase**

Obturation $\bar{c}$ $\frac{|12}{|}$

Endodontic - restoration using Ribbond material followed by Crown Placement $\bar{c}$ $\frac{|12}{|}$

xxxv) **Maintenance phase**

Recall after 15 days, 1 month, 3 moths

Dept. of Conservative Dentistry & Endodontics

Signature of instructor :-

Date:- 24/4/23

CASE RECORDS

Diagnosis & Treatment planning in Conservative Dentistry

Name of the patient: Mr. Saurabh Jadhav

Age: 22 years old

Registration No. 125630

Address: Lohegaon

Date: 25/3/2023

Tel. No.

Gender: Male

Occupation: Student.

Emergency Contact:

DENTAL RECORD

Chief Complaint:

Patient complaint of pain in upper right back region of the jaw since 2 weeks

History of present illness:

Patient was apparently asymptomatic 2 weeks back. He experienced pain which was localized, constant and throbbing and spotaneous in nature. pain was aggrevating while cold, relieved after ~~removal of~~ taking medication.

Past Dental Experience:

No relevant history

Subjective symptoms:

Tooth / Region

Pain:	Present ✓		Absent	
Location:	Localized ✓	Diffused	Referred	Radiating
Duration:	Seconds	Minutes	Hours	Constant ✓
Quality:	Sharp	Dull	Throbbing ✓	
Onset:	Stimulated	Spontaneous ✓		
Increased by:	Cold ✓	Heat ✓	Pressure	Mastication
	Postural Change	Sweet	Sour	Others
Relieved by:	Cold	Heat	Medication ✓	

Medical History:

A) Record of any present illness:

i) Cardiac disease – None

- Anginal / Coronary
- Pacemaker
- Congenital heart disease
- Rheumatic fever

ii) Abnormal bleeding → None

- Blood dyscrasias

iii) High blood pressure → None

iv) Anemia

v) Diabetes

vi) Hepatitis

vii) AIDS / HIV

viii) Asthma

ix) Tuberculosis

x) Arthritis

xi) Sinus trouble

xii) Epilepsy

xiii) Stroke

xiv) Psychiatric treatment

xv) Cancer treatment / Radiation therapy

B) Any medicines or drugs taken in the past or current medication → NO

C) Allergy to any drug/drugs – NO

D) Any prosthesis inserted into the body → NO

E) Any Surgery in the past with or without blood transfusion – NO

F) For Women Pregnancy Y/N ✓

Nursing Y/N ✓

G) Any other relevant findings → No

EXAMINATION

A) General Examination:

Built – Average

Stature → Normal

Gait → Normal

Posture → Erect

B) Extraoral Examination:

- Symmetry → Bilaterally Symmetrical
- Swelling: → Absent Hard Soft Diffused Localized
  Dimension and extent
- TM Joint → No abnormality
- Lymph nodes → Non-palpable
- Sinus/Fistula → Absent

C) Intraoral examination

i) Soft tissue examination: → No abnormalities seen

Tongue Mucosa Palate Floor of mouth Gingiva

ii) Swelling: Present Absent ✓

iii) Sinus tract opening: → Absent

iv) Oral hygiene: Good Fair ✓ Poor

v) Occlusion: Harmonious ✓ Non-harmonious

CLINICAL EXAMINATION OF AMALGAM RESTORATIONS:

Amalgam blues
Proximal overhangs
Marginal ditching
Voids
Fracture lines
Improper anatomic contours
Marginal ridge incompatibility
Improper proximal contacts
Recurrent caries
Improper occlusal contacts

No relevant findings.

CLINICAL EXAMINATION OF CAST RESTORATIONS

⇨ **Defective, Proximal overhang, Improper contours, Fractured tooth/Restoration, Secondary caries.**

CLINICAL EXAMINATION OF TOOTH COLORED RESTORATION.

1) Improper contour
2) Proximal contact
3) Overhanging proximal margin
4) Recurrent caries
5) Marginal staining.
6) Fracture

No relevant findings.

EXAMINATION OF NON-CARIOUS LESIONS

ATTRITION

ABRASION

EROSION

ABFRACTION

No relevant findings.

EXAMINATION OF AREA OF CHIEF COMPLAINT:

a. Tenderness on palpation → Absent

b. Pain on percussion → Absent

c. Mobility → No mobility (Absent)

d. Furcation involvement → Absent.

e. Pulp vitality tests

Thermal test: Heat Cold ✓

i. No response
ii. Moderate transient response
iii. Painful response which subsides quickly after removal of stimulus
iv. Painful response that lingers after removal of stimulus ✓

f. Electric pulp test

	Control tooth	Test tooth
	Response at number	Response at number

Caries Diagnosis:

1. Clinical Examination for caries:
   a) Visual changes - Surface Texture → Distinct cavity with visible dentin
   - Colour
2. Tactile sensation
3. Radiographs → Involving caries approaching pulp
4. Transillumination. → Dark shadow seen in occlusal and distal aspec

Categorization of Adults According to Caries Risk indicators:

Caries Risk Category

Low: - No carious lesions in last 3 years.

Adequately restored surfaces

✓ Good oral hygiene

Regular dental Visits

Fluoride dentifrice use

Medium: -

Presence of two of the following indicators:

Current orthodontic treatment or removable appliance or several exposed root surface or poor oral hygiene or frequent fermentable carbohydrate intake or inadequate exposure to topical Fluoride.

High:- Presence of one of the following indicators:

Any carious lesion in previous 2 years or inadequate salivary flow or initial enamel interproximal radiolucencies or presence of >2 of the risk indicators shown in the medium risk category.

Provisional Diagnosis:

Symptomatic reversible pulpitis : $\frac{6}{|}$

~~Apical~~

Investigations and interpretations :

i) Radiographs: Intraoral periapical

Bitewing : $\frac{6}{|}$ → Irregular ill-defined radiolucency involving enamel, dentin involving pulp.

O.P.G. widening of PDL in middle and apical third of root

Any other

ii) Blood tests:

iii) Any other:

Final Diagnosis:

Pulpal

Reversible
Irreversible ✓ Symptomatic Irreversible pulpitis

Periapical Pathology:

1) Acute apical periodontitis
2) Chronic apical periodontitis
3) Periapical granuloma
4) Periapical cyst
5) Acute dentoalveolar abscess

Prognosis:

Good

Treatment Plan:

xxxi) Urgent phase

Root canal treatment ₹6/-

xxxii) Control phase

Oral phophylaxis

xxxiii) Re-evaluation phase

Evaluation ₹6/-

xxxiv) Definitive phase

Root canal treatment, Access Opening followed by Biomechanical preparation followed by Obturation ₹6/-

xxxv) Maintenance phase

Recall after 15 days, 1 month, 3 month, 6 month and 12 month.

Dept. of Conservative Dentistry & Endodontics

Signature of instructor :-

Date:- 26/3/2023

CASE RECORDS

Diagnosis & Treatment planning in Conservative Dentistry

Name of the patient: Nazid Azhar.

Age: 32. Registration No. 630810.

Address: Vishrantwadi' Date: 5/9/23.

Tel. No. 8967598789. Gender: female.

Occupation: Housewife Emergency Contact:

DENTAL RECORD

Chief Complaint:

Patient complains of pain on chewing food since past 2 months.

History of present illness:

Patient was apparently alright 2 months back & started experiencing dull aching pain since past 2 months on mastication.

Past Dental Experience:

Patient had undergone restorative treatment with respect to 16. 8 years ago.

Subjective symptoms:

Tooth / Region

Pain:	~~Present~~		Absent	
Location:	~~Localized~~	Diffused	Referred	
Duration:	Seconds	~~Minutes~~	Hours	Radiating
Quality:	Sharp	~~Dull~~	Throbbing	Constant
Onset:	Stimulated	~~Spontaneous~~		
Increased by:	Cold	~~Heat~~	Pressure	Mastication
	Postural Change	Sweet	Sour	Others
Relieved by:	Cold	Heat	~~Medication~~	

Medical History:

A) Record of any present illness: – Not relevant history.

i) Cardiac disease

- Anginal / Coronary
- Pacemaker
- Congenital heart disease
- Rheumatic fever

ii) Abnormal bleeding

- Blood dyscrasias

iii) High blood pressure

iv) Anemia

v) Diabetes

vi) Hepatitis

vii) AIDS / HIV

viii) Asthma

ix) Tuberculosis

x) Arthritis

xi) Sinus trouble

xii) Epilepsy

xiii) Stroke

xiv) Psychiatric treatment

xv) Cancer treatment / Radiation therapy

B) Any medicines or drugs taken in the past or current medication – No

C) Allergy to any drug/drugs – No

D) Any prosthesis inserted into the body – No

E) Any Surgery in the past with or without blood transfusion – No.

F) For Women Pregnancy ~~Y~~/N

Nursing ~~Y~~/N

G) Any other relevant findings

Subjective symptoms:

Tooth / Region

Pain:	✓ Present		Absent	
Location:	✓ Localized	Diffused	Referred	Radiating
Duration:	Seconds	✓ Minutes	Hours	Constant
Quality:	Sharp	✓ Dull	Throbbing	
Onset:	Stimulated	✓ Spontaneous		
Increased by:	Cold	✓ Heat	Pressure	Mastication
	Postural Change	Sweet	Sour	Others
Relieved by:	Cold	Heat	✓ Medication	

Medical History:

A) Record of any present illness: – Not relevant history.

i) Cardiac disease

- Anginal / Coronary
- Pacemaker
- Congenital heart disease
- Rheumatic fever

ii) Abnormal bleeding

- Blood dyscrasias

iii) High blood pressure

iv) Anemia

v) Diabetes

vi) Hepatitis

vii) AIDS / HIV

viii) Asthma

ix) Tuberculosis

x) Arthritis

xi) Sinus trouble

xii) Epilepsy

xiii) Stroke

xiv) Psychiatric treatment

xv) Cancer treatment / Radiation therapy

B) Any medicines or drugs taken in the past or current medication – No

C) Allergy to any drug/drugs – No

D) Any prosthesis inserted into the body – No

E) Any Surgery in the past with or without blood transfusion – No .

F) For Women Pregnancy X/N

Nursing X/N

G) Any other relevant findings

1127 / 1643

EXAMINATION

A) General Examination:

Built – Normal.

Stature – Normal

Gait – Normal

Posture – Erect.

B) Extraoral Examination:

- Symmetry –
- Swelling: NA Hard Soft Diffused Localized
  Dimension and extent
- TM Joint NA
- Lymph nodes NA
- Sinus/Fistula NA

C) Intraoral examination

i) Soft tissue examination: – NA.

Tongue Mucosa Palate Floor of mouth Gingiva
Normal Normal

ii) Swelling: Present Absent

iii) Sinus tract opening: Absent.

iv) Oral hygiene: Good Fair Poor

v) Occlusion: Harmonious Non-harmonious

1128/1645

vi) Current status of dentition

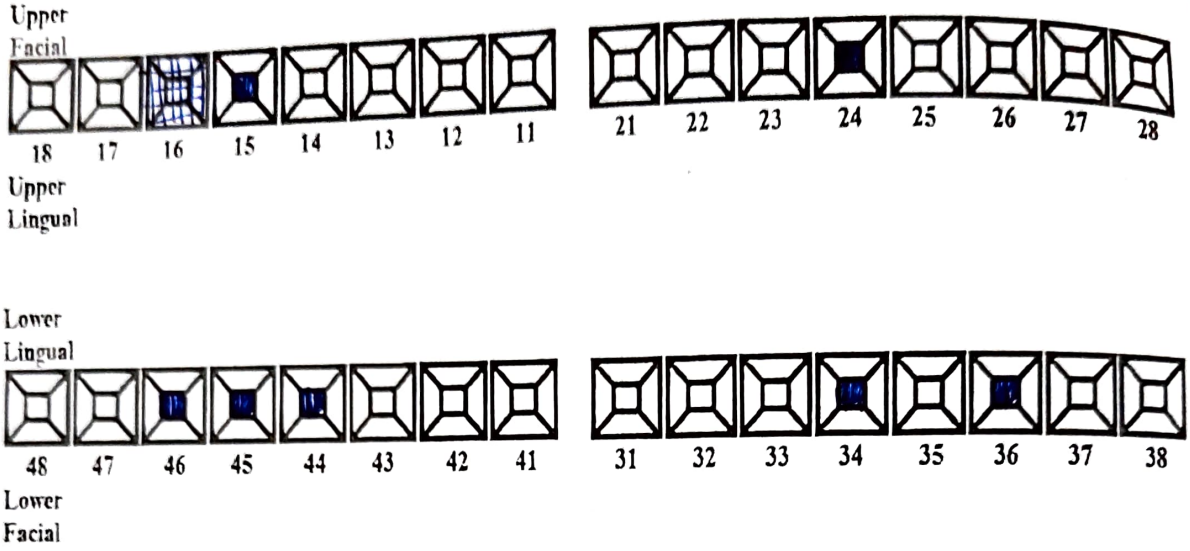

Notation:

Caries -

Restoration present -

Secondary caries -

Tooth missing - A

Discoloration -

Tooth fracture - F

R.C. treated – R.C.

Attrition -

Abrasion / Erosion –

Crown present – C

Vertical fracture – #

CLINICAL EXAMINATION OF AMALGAM RESTORATIONS: NA

Amalgam blues

Proximal overhangs

Marginal ditching

Voids

Fracture lines

Improper anatomic contours

Marginal ridge incompatibility

Improper proximal contacts

Recurrent caries

Improper occlusal contacts

CLINICAL EXAMINATION OF CAST RESTORATIONS

⇨ Defective, Proximal overhang, Improper contours, Fractured tooth/Restoration, Secondary caries.

CLINICAL EXAMINATION OF TOOTH COLORED RESTORATION.

1) Improper contour
2) Proximal contact
3) Overhanging proximal margin
4) Recurrent caries
5) Marginal staining.
6) Fracture

EXAMINATION OF NON-CARIOUS LESIONS

ATTRITION Absent

ABRASION Absent

EROSION Absent

ABFRACTION Absent

EXAMINATION OF AREA OF CHIEF COMPLAINT:

a. Tenderness on palpation – Present / Positive

b. Pain on percussion / Positive

c. Mobility Absent.

d. Furcation involvement Absent.

e. Pulp vitality tests

Thermal test: Heat Cold

i. No response
ii. Moderate transient response
iii. Painful response which subsides quickly after removal of stimulus
iv. Painful response that lingers after removal of stimulus

f. Electric pulp test

	Control tooth	Test tooth
	Response at number	Response at number

Caries Diagnosis:

1. Clinical Examination for caries:
   a) Visual changes
      - Surface Texture – Rough.
      - Colour – Black.
2. Tactile sensation – catch noticed ± explorer
3. Radiographs – Radiograph show radiolucent area involving enamel, dentin, pulp ± two roots.
4. Transillumination.

Categorization of Adults According to Caries Risk indicators:

Caries Risk Category

Low: - No carious lesions in last 3 years.

Adequately restored surfaces

Good oral hygiene

Regular dental Visits

Fluoride dentifrice use

Medium: -

Presence of two of the following indicators:

Current orthodontic treatment or removable appliance or several exposed root surface or poor oral hygiene or frequent fermentable carbohydrate intake or inadequate exposure to topical Fluoride.

High:- Presence of one of the following indicators:

Any carious lesion in previous 2 years or inadequate salivary flow or initial enamel interproximal radiolucencies or presence of >2 of the risk indicators shown in the medium risk category.

Provisional Diagnosis:

Irreversible chronic pulpitis w.r.t. 4|. followed by apical periodontitis.

Investigations and interpretations :

i) Radiographs: Intraoral periapical — caries involving pulp with two roots w.r.t 4|.

Bitewing —

O.P.G. —

Any other —

ii) Blood tests: NA

iii) Any other: NA .

Final Diagnosis:

Pulpal

Reversible
Irreversible ✓

Periapical Pathology:

1) Acute apical periodontitis
2) Chronic apical periodontitis ✓
3) Periapical granuloma
4) Periapical cyst
5) Acute dentoalveolar abscess

Prognosis:

Fair .

Treatment Plan:

xxxi) Urgent phase

Caries excavation & Access opening w.r.t. 4|.

xxxii) Control phase

caries control by fluoride application.

xxxiii) Re-evaluation phase

Maintainance of oral hygiene, Brushing, flossing, mouthwash.

xxxiv) Definitive phase

Endodontic treatment i.e. 4| (Biomechanical preparation & Obturation & Post operative restoration.) followed by prosthesis.

xxxv) Maintenance phase

Follow up after 1 months.
3 months
6 months.

Dept. of Conservative Dentistry & Endodontics

Signature of instructor :-

Date:-

CASE RECORDS

Diagnosis & Treatment planning in Conservative Dentistry

Name of the patient: Prem Kumar

Age: 29/M | Registration No.

Address: Kalve Nagar, Pune | Date:

Tel. No. 8529753154 | Gender: M

Occupation: Businessman. | Emergency Contact:

DENTAL RECORD

Chief Complaint: patient complains of pain in lower anterior region of jaw. since 7days.

1135 / 1645

History of present illness: patient was apparently asymptomatic 7 days prior. He started experience severe pain in lower front region of jaw. Pain was continuous, throbbing, activated on cold consumption. History of trauma few years back. History of sinus opening seen.

Past Dental Experience: patient had undergone for Restorat^ in upper back region of jaw.

Subjective symptoms:

Tooth / Region +

Pain:	Present ✓		Absent	
Location:	Localized ✓	Diffused	Referred	Radiating ✓
Duration:	Seconds	Minutes	Hours	Constant ✓
Quality:	Sharp ✓	Dull	Throbbing	
Onset:	Stimulated ✓	Spontaneous		
Increased by:	Cold ✓	Heat	Pressure	Mastication
	Postural Change	Sweet	Sour	Others
Relieved by:	Cold	Heat	Medication ✓	

Medical History:

A) Record of any present illness: No Medical history.

i) Cardiac disease

- Anginal / Coronary
- Pacemaker
- Congenital heart disease
- Rheumatic fever

ii) Abnormal bleeding

- Blood dyscrasias

iii) High blood pressure

iv) Anemia

v) Diabetes

vi) Hepatitis

vii) AIDS / HIV

viii) Asthma

ix) Tuberculosis

x) Arthritis

xi) Sinus trouble

xii) Epilepsy

xiii) Stroke

xiv) Psychiatric treatment

xv) Cancer treatment / Radiation therapy

B) Any medicines or drugs taken in the past or current medication

C) Allergy to any drug/drugs

D) Any prosthesis inserted into the body

E) Any Surgery in the past with or without blood transfusion

F) For Women Pregnancy Y/N

Nursing Y/N

G) Any other relevant findings

EXAMINATION

A) General Examination:

Built
Stature
Gait
Posture

} Average.

B) Extraoral Examination:

- Symmetry
- Swelling: No. Hard Soft Diffused Localized
  Dimension and extent
- TM Joint
- Lymph nodes
- Sinus/Fistula

} Not Applicable.

C) Intraoral examination

i) Soft tissue examination: Normal in appearance

Tongue Mucosa Palate Floor of mouth Gingiva

ii) Swelling: Present Absent

iii) Sinus tract opening: Seen.

iv) Oral hygiene: Good Fair Poor

v) Occlusion: Harmonious Non-harmonious

vi) Current status of dentition

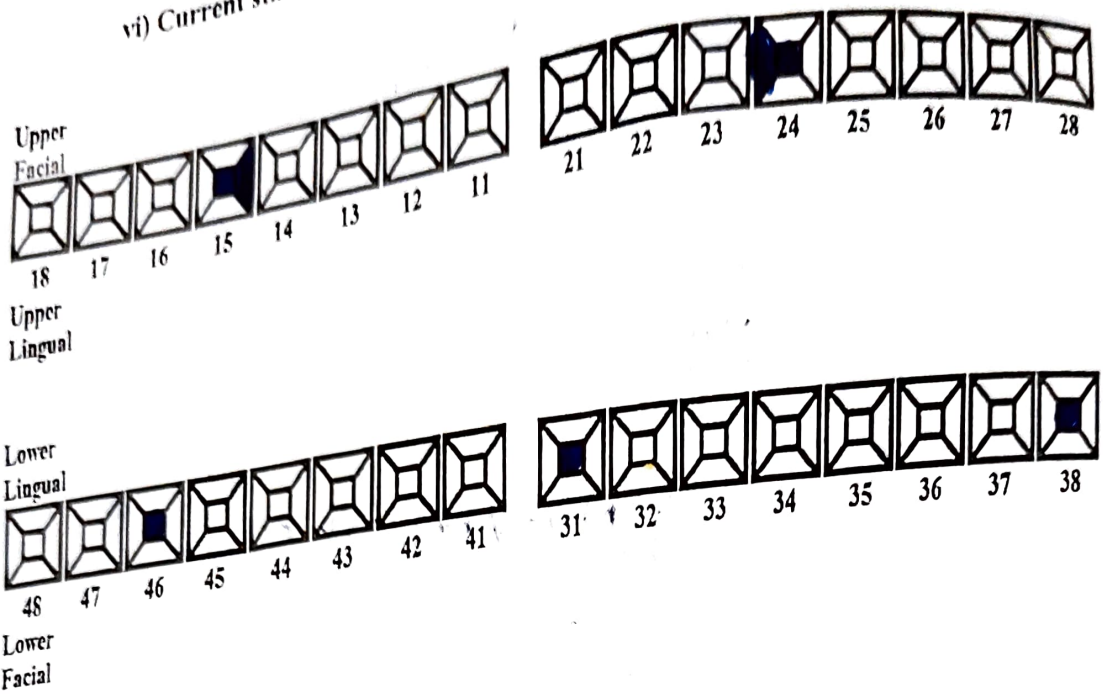

Notation:

Caries -

Restoration present -

Secondary caries -

Tooth missing - A

Discoloration -

Tooth fracture - F

R.C. treated – R.C.

Attrition -

Abrasion / Erosion –

Crown present – C

Vertical fracture – #

CLINICAL EXAMINATION OF AMALGAM RESTORATIONS:

- Amalgam blues
- Proximal overhangs
- Marginal ditching
- Voids
- Fracture lines
- Improper anatomic contours
- Marginal ridge incompatibility
- Improper proximal contacts
- Recurrent caries
- Improper occlusal contacts

} Not seen.

CLINICAL EXAMINATION OF CAST RESTORATIONS

⇨ Defective, Proximal overhang, Improper contours, Fractured tooth/Restoration, Secondary caries.

CLINICAL EXAMINATION OF TOOTH COLORED RESTORATION.

1) Improper contour
2) Proximal contact
3) Overhanging proximal margin
4) Recurrent caries
5) Marginal staining.
6) Fracture

EXAMINATION OF NON-CARIOUS LESIONS

ATTRITION Seen ✓

ABRASION

EROSION

ABFRACTION

} Absent.

EXAMINATION OF AREA OF CHIEF COMPLAINT:

a. Tenderness on palpation

b. Pain on percussion — Top +ve

c. Mobility — Not seen

d. Furcation involvement :— Not seen

e. Pulp vitality tests → performed — not vital

Thermal test: Heat ✓ Cold ✓

i. No response
ii. Moderate transient response
iii. Painful response which subsides quickly after removal of stimulus
iv. Painful response that lingers after removal of stimulus

f. Electric pulp test — not vital

	Control tooth	Test tooth
	Response at number	Response at number

Caries Diagnosis:

1. Clinical Examination for caries:
   a) Visual changes
      - Surface Texture
      - Colour
2. Tactile sensation
3. Radiographs
4. Transillumination.

Categorization of Adults According to Caries Risk indicators:

Caries Risk Category

Low: - No carious lesions in last 3 years.

Adequately restored surfaces

Good oral hygiene

Regular dental Visits

Fluoride dentifrice use

Medium: -

Presence of two of the following indicators:

Current orthodontic treatment or removable appliance or several exposed root surface or poor oral hygiene or frequent fermentable carbohydrate intake or inadequate exposure to topical Fluoride.

High:- Presence of one of the following indicators:

Any carious lesion in previous 2 years or inadequate salivary flow or initial enamel interproximal radiolucencies or presence of >2 of the risk indicators shown in the medium risk category.

Provisional Diagnosis:

Acute Apical Abscess 2 +1

Investigations and interpretations :

i) Radiographs: Intraoral periapical Attrition involving pulp. pulp exposure with two canal seen 2 +1

Bitewing –

O.P.G. –

Any other –

ii) Blood tests: NA

iii) Any other: NA

Final Diagnosis:

Pulpal

- Reversible
- ✓ Irreversible

Periapical Pathology:

- ✓ 1) Acute apical periodontitis
- 2) Chronic apical periodontitis
- 3) Periapical granuloma
- 4) Periapical cyst
- ✓ 5) Acute dentoalveolar abscess

Prognosis: Good

CASE RECORDS

Diagnosis & Treatment planning in Conservative Dentistry

Name of the patient: Atharva Dhage

Age: 18

Address: Dhanori

Tel. No. 9960345832

Occupation: Student

Registration No. 155752

Date: 12/9/23

Gender: Male

Emergency Contact:

DENTAL RECORD

Chief Complaint: Patient complains of pain and discoloration of tooth in upper front region of jaw since 1 month

History of present illness: Patient was apparently alright 1 month back. He suffered trauma to the upper front tooth due to blow from cricket ball. He started experiencing pain on biting which was dull aching in nature and relieved on its own. He also experienced pinkish discoloration of tooth.

Past Dental Experience: No relevant history

Subjective symptoms:

Tooth / Region 14

Pain:	Present ✓		Absent	
Location:	Localized ✓	Diffused	Referred	Radiating
Duration:	Seconds	Minutes ✓	Hours	Constant
Quality:	Sharp	Dull ✓	Throbbing	
Onset:	Stimulated ✓	Spontaneous		
Increased by:	Cold	Heat	Pressure	Mastication
	Postural Change	Sweet	Sour	Others
Relieved by:	Cold	Heat	Medication ✓	

Medical History:

A) Record of any present illness: No relevant history

i) Cardiac disease
- Anginal / Coronary
- Pacemaker
- Congenital heart disease
- Rheumatic fever

ii) Abnormal bleeding
- Blood dyscrasias

iii) High blood pressure

iv) Anemia

v) Diabetes

vi) Hepatitis

vii) AIDS / HIV

viii) Asthma

ix) Tuberculosis

x) Arthritis

xi) Sinus trouble

xii) Epilepsy

xiii) Stroke

xiv) Psychiatric treatment

xv) Cancer treatment / Radiation therapy

B) Any medicines or drugs taken in the past or current medication

C) Allergy to any drug/drugs

D) Any prosthesis inserted into the body

E) Any Surgery in the past with or without blood transfusion

F) For Women Pregnancy Y/N

Nursing Y/N

G) Any other relevant findings

EXAMINATION

A) General Examination:

Built — Average

Stature, Gait, Posture — Normal

B) Extraoral Examination:

- Symmetry ✓
- Swelling: NO — Hard / Soft — Diffused / Localized — Dimension and extent
- TM Joint
- Lymph nodes
- Sinus/Fistula

— No abnormality detected

C) Intraoral examination

i) Soft tissue examination: No abnormality detected

Tongue Mucosa Palate Floor of mouth Gingiva

ii) Swelling: Present Absent

iii) Sinus tract opening: No sinus opening

iv) Oral hygiene: ✓Good Fair Poor

v) Occlusion: ✓Harmonious Non-harmonious

vi) Current status of dentition Presence of mesiodens.

Upper Facial

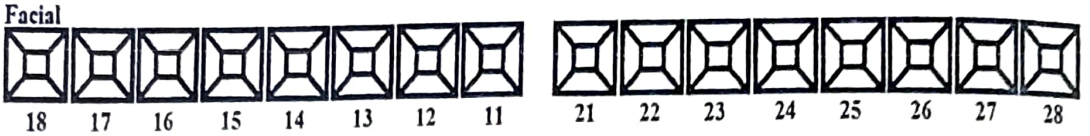

Upper Lingual

Lower Lingual

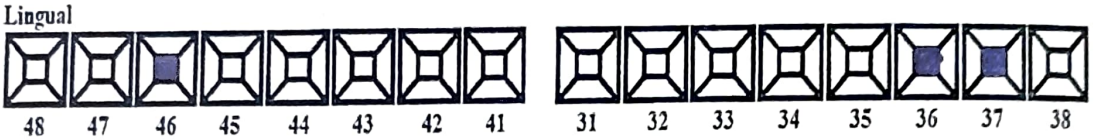

Lower Facial

Notation:

Caries -

Restoration present -

Secondary caries -

Tooth missing - A

Discoloration -

Tooth fracture - F

R.C. treated – R.C.

Attrition -

Abrasion / Erosion –

Crown present – C

Vertical fracture – #

CLINICAL EXAMINATION OF AMALGAM RESTORATIONS:

Amalgam blues

Proximal overhangs

Marginal ditching

Voids

Fracture lines

Improper anatomic contours

Marginal ridge incompatibility

Improper proximal contacts

Recurrent caries

Improper occlusal contacts

No abnormality detected

CLINICAL EXAMINATION OF CAST RESTORATIONS

⇨ Defective, Proximal overhang, Improper contours, Fractured tooth/Restoration, Secondary caries.

CLINICAL EXAMINATION OF TOOTH COLORED RESTORATION.

1) Improper contour
2) Proximal contact
3) Overhanging proximal margin
4) Recurrent caries
5) Marginal staining.
6) Fracture

EXAMINATION OF NON-CARIOUS LESIONS

ATTRITION — seen with +

ABRASION

EROSION

ABFRACTION

Absent

EXAMINATION OF AREA OF CHIEF COMPLAINT:

a. Tenderness on palpation

b. Pain on percussion -ve

c. Mobility Not seen

d. Furcation involvement Not seen

e. Pulp vitality tests

Thermal test:	Heat	Cold
i. No response ✓	✓	✓

ii. Moderate transient response

iii. Painful response which subsides quickly after removal of stimulus

iv. Painful response that lingers after removal of stimulus

f. Electric pulp test

Control tooth	Test tooth
Response at number	Response at number
9	25

Caries Diagnosis:

1. Clinical Examination for caries:
   a) Visual changes
      - Surface Texture
      - Colour
2. Tactile sensation
3. Radiographs
4. Transillumination.

Categorization of Adults According to Caries Risk indicators:

Caries Risk Category

Low: - No carious lesions in last 3 years.

Adequately restored surfaces

Good oral hygiene

Regular dental Visits

Fluoride dentifrice use

Medium: -

Presence of two of the following indicators:

Current orthodontic treatment or removable appliance or several exposed root surface or poor oral hygiene or frequent fermentable carbohydrate intake or inadequate exposure to topical Fluoride.

High:- Presence of one of the following indicators:

Any carious lesion in previous 2 years or inadequate salivary flow or initial enamel interproximal radiolucencies or presence of >2 of the risk indicators shown in the medium risk category.

Provisional Diagnosis:

Internal resorption secondary to chronic irreversible pulpitis c /

Investigations and interpretations :

i) Radiographs: Intraoral periapical Periapical widening seen with /

Periapical radiolucency seen c /

Bitewing

O.P.G.

Any other

ii) Blood tests:

iii) Any other:

Final Diagnosis:

Pulpal

Reversible
Irreversible ✓

Periapical Pathology:

1) Acute apical periodontitis
2) Chronic apical periodontitis ✓
3) Periapical granuloma
4) Periapical cyst
5) Acute dentoalveolar abscess

Prognosis: good

Treatment Plan:

xxxi) **Urgent phase** Access opening with $\frac{11}{}$

xxxii) **Control phase** Caries control by fluoride application

xxxiii) **Re-evaluation phase**

Oral prophylaxis
Maintenance of oral hygiene

xxxiv) **Definitive phase**

~~Ex~~ Non surgical endodontic treatment $\bar{c}$ $\frac{11}{}$
Biomechanical preparation and obturation $\bar{c}$ $\frac{11}{}$
Extraction of mesiodens

xxxv) **Maintenance phase**

Closure of midline diastema by orthodontic treatment
Follow up after 1 month
3 month
6 month
1 year
3 year

Signature of instructor :-

Dept. of Conservative Dentistry & Endodontics

Date:-

CASE HISTORY

Department of Orthodontics and Dentofacial Orthopedics





















Anjali Khadke.

D. Y. PATIL DENTAL SCHOOL

Dr. D Y Patil Knowledge City, Charholi Bk, Via Lohegaon, Pune

D Y PATIL GROUP

ORTHODONTIC CASE RECORD

DEPARTMENT OF ORTHODONTICS AND DENTOFACIAL ORTHOPEDICS

Consent –

I, Anjali Phadke , fully understand that my ward needs Orthodontic treatment. I have also understood the need for extractions of _____before starting the Orthodontic treatment of my ward.

I have understood that although Orthodontic treatment has a very high degree of success, it is a bio-mechanical procedure, so it cannot be guaranteed and the unfavorable consequences of this treatment may include the following:

1. Post-extraction discomfort and swelling may occur for which medication will be prescribed if deemed necessary by the doctor.

2. Pain and discomfort of teeth and adjacent soft tissues may occur due to placement of brackets, bands and wires.

3. The treatment time will be increased indefinitely if the patient does not co-operate with all the instructions given by the treating doctor.

4. There may be a total relapse of finished treatment, if the retainers are not worn for the required duration.

5. There may be a relapse of treatment if deleterious oral habits such as tongue thrusting, mouth breathing, lip sucking etc. persist after completion of treatment.

6. Relapse of treatment may occur later on eruption of the maxillary / Mandibular third molars Extractions if not deemed necessary at the initial examination may be needed later and carried out with due consent.

8. Accidental breakage of the wires or brackets will not be the responsibility of the doctor.

9. Tooth mobility and gum swelling may occur due to Orthodontic treatment, if proper oral hygiene is not maintained during the treatment.

10. Poor Oral Hygiene may also result in permanent stains, white spots or cavities in the teeth.

11. Estimated fees may alter in case the treatment plan is altered during the treatment

12. Pre and post treatment photographs radiographs and other records can be used by the institute for study purpose, presentations and publications.

13. For surgical cases, if surgery is refused by the patient, we/ department shall not be liable for the consequences.

14. If gum condition worsens or in case of severe periodontitis, adequate gum & periodontal health will be determined prior to starting orthodontic treatment. It is the responsibility of the patient to maintain proper oral hygiene including use of special methods.

15. The Department may utilize the services of any of its doctors / students /associated specialist doctors for the treatment.

16. In case of preexisting TMJ disorders if treatment is carried out, it is with full awareness that these may worsen during or after treatment, though orthodontic treatment has no correlation with TMJ disorders. The operator or department shall not be held liable for the same.

17. On completion of the treatment, the aesthetic judgment of the treating doctorls will be considered final and unquestionable.

I have also understood that the estimated duration of treatment will be about 2 Years and the fees for it will be Rs. 15,000/- and Rs. _____ per Month/quarter will be charged.

Anjaligoda

Signature of the Parent Guardian:

Relationship of the Parent / Guardian:

Date: 31/12/2

D. Y. PATIL DENTAL SCHOOL

Dr. D Y Patil Knowledge City, Charholi Bk, Via Lohegaon, Pune

Case History Proforma

A) Patient Details

Name– Anjali Khadke

Age– 20 yrs 6 months

Gender – Male / Female

Date of Birth – 12th Jan. 2002

Ethnicity –

B) Correspondence Details

Address – Bhairav Nagar, Dhanori, Pune

Contact numbers – Patient: 8411888143 Parent: 7038686664. Landline no.-

Email id - Anjalipk121@gmail.com.

Chief Complaint: patient complaints of cooked teeth in upper front region of jaw.

Dental History: NAH.

Medical History:

Systemic diseases- Yes/ No

Allergies- Yes/ No

H/O Hospitalisation- Yes/ No

H/O Trauma Yes/No

Pre-natal history-

Nutritional disorders- Yes/ No

Post-natal history-

Milestones of development- Premature/ Usual/ Delayed achievement

History of adverse Oral Habits

Digit sucking / Lip sucking / Tongue sucking / Cheek sucking / Nail biting / Bruxism / Mouth Breathing

Any other habit –

Frequency – Continuously / Intermittently / Rarely

Intensity – High / Moderate / Low

Duration – ____ hrs a day

General and physical assessment:

	Pre Rx	Mid Rx	Post Rx	
Height-	156 cm.			cm
Weight-	45 kg.			kg

Physique – Mesomorphic / Ectomorphic / Endomorphic

Growth Status

Secondary Sexual Characteristics – attained / not attained

Rapid Height Change – attained / not attained

Voice Change – attained / not attained

E) Psychological Assessment

Internally Motivated / Externally Motivated

Easy to educate / Difficult to educate

Lively / Quiet / Nervous / Phlegmatic

Expectations: Unrealistic / Realistic

F) Extra Oral Examination

Facial Index:

Mesoprosopic / Euryprosopic / Leptoprosopic

(84-87.9) (78.9-83.9) (88-93)

Facial height x 100 / Facial Width

90 / 110

90 x 100 / 110 = 81%

Cephalic Index:

Mesocephalic / Brachycephalic / Dolichocephalic

(76.0-80.9) (81.0-85.4) (upto 75.9)

Head width x 100 / Head Length

135 / 170

185 x 100 / 170 = 79%

Facial Symmetry: Symmetrical / Asymmetrical (Directional / Anti Symmetry / Fluctuating)

Profile: Straight (anterior divergent/ posterior divergent)/ Convex/ Concave

Facial height:

Total-

Upper- 60 mm

Middle- 55 mm

Lower- 55 mm

Lower 1/3rd –

Upper 1/3rd -

Lower 2/3rd –

TMJ Examination-

Pain/Tenderness- None/ right/ left/ bilateral

Clicking- None/ / right/ left/ bilateral

Crepitus- None/ right/ left/ bilateral

Swallowing Pattern – Somatic / Viscerosomatic / Visceral

Breathing Pattern – Oral / Nasal / Oronasal

Circum Oral musculature –

Orbicularis Oris – No abnormality detected / Hyperactive / Hypoactive

Buccinator – No abnormality detected / Hyperactive / Hypoactive

Mentalis – No abnormality detected / Hyperactive / Hypoactive

Masseter – No abnormality detected / Hyperactive / Hypoactive

Lateral Pterygoid – None / Right / Left / Bilateral

Temporalis – None / Right / Left / Bilateral

G) Soft Tissue Examination

Nasolabial angle – Normal / Acute / Obtuse

Upper Component / Lower component

Lips- Competent / potentially competent / Incompetent

Upper lip – Average Thick/ Thin Short / Long Length - mm

Lower lip – Average Thick / Thin Short / Long Length - mm

Upper Lip Position at rest – Incisal 1/3rd Middle 1/3rd

Cervical 1/3rd Beyond Cervical 1/3rd

Lip Step – Positive / Negative / Straight

Smile Arc – Consonant / Flat / Reverse

Smile Line – Pleasant / Toothy / Gummy

Mentolabial Sulcus – Average / Shallow / Deep / Absent

Midlines –

Facial Midline to Upper Dental Midline – Coincident / Non - coincident

Facial midline to Lower Dental Midline – Coincident / Non - coincident

To wards left

H) Intra Oral Examination

Gingival Condition – Normal / Inflamed / Hyperplasic / Recession

Width of Attached Gingiva – Adequate / Inadequate in the region of

Periodontal Disease – Yes / No

Oral Hygiene Status – Good / Fair / Poor

Labial Frenum – Strong / Weak / Deep Insertion / Frenectomized

Tongue –

Size – No abnormality detected / Macroglossia / Microglossia

Posture – Low lying / Normal

Palate – Average / Shallow / Deep

Supplemental Findings -

OPG analysis:

Dental: 8 7 6 5 4 3 2 1 | 1 2 3 4 5 6 7 8

Teeth present/ absent 8 7 6 5 4 3 2 1 | 1 2 3 4 5 6 7 8

Supernumerary teeth present/ absent-

Root morphology anomaly present/absent (supported with IOPA) -

Demerijian's assessment for canine and third molar- molar : G canine - H.

Third molar impacted/ erupting/erupted- partially Impacted.

General bone condition-

Anatomical:

TMJ assessment:

Condylar head: Fossa:

Ramus:

Gonial border: Normal

Symmetry of structures:

General structures:

I)

Dental Examination

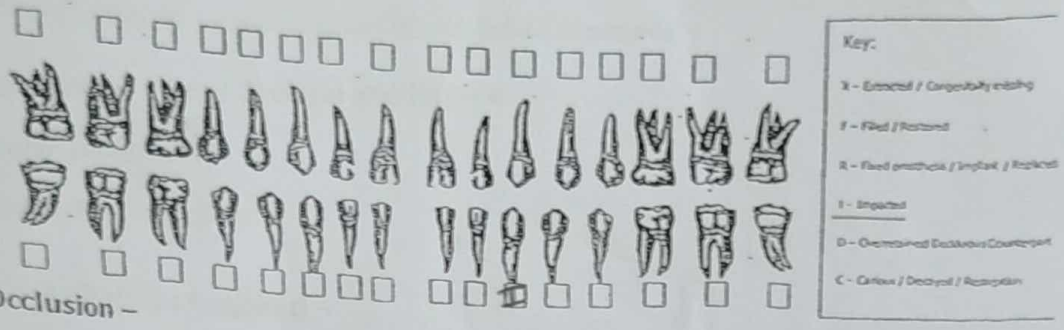

Occlusion –

Relation	Right Side	Left Side
Incisor Relation	I	I
Canine Relation	I	end - on
Molar Relation	edge to edge	end - on

Axial Relation – Proclined / Retroclined

Overjet – mm 1 mm

Overbite – mm 7 mm

Openbite – mm

Crossbite – mm

Curve of Spee – mm

Scissor bite –

Rotations –

Dental Midlines – Upper to Left ☐ Upper to Right ☑

Lower to Left ☐ Lower to Right ☑

Arch Form & Dimension –

	Maxillary	Mandibular
Shape	'V' Shaped ☐ 'U' Shaped ☐ Square ☑	'V' Shaped ☐ 'U' Shaped ☐ Square ☑
Symmetry	Symmetrical ☐ Asymmetrical ☐	Symmetrical ☐ Asymmetrical ☐

J) Functional Movement Analysis –

Maximum Opening – mm 39 mm

Freeway Space – mm 4 mm

Lateral Occlusion – Group Function / Canine Guided

Protrusive Occlusion – Incisal Guidance / Posterior Occlusal Interference

Functional shift- None/ Occlusal interference

Muscular abnormality-

Anatomic TMJ disturbance-

K) Consultations Required –

Periodontal –

Restorative Dentistry –

Prosthodontic –

Maxillofacial –

Otolaryngologist –

Other –

L) Skeletal Age Assessment

CVMI – Initiation(100%) / Acceleration(85%-65%) / Transition(65%-40%) / Deceleration(40%-25%) / Maturation(25%-10%) / Completion(10%-0%) stage – 6

MP3 – MP3-F / MP3-FG / MP3-G / MP3-H / MP3-HI / MP-I

Hand-Wrist Radiographs –

IOPA (in cases with history of tongue thrust, trauma, anterior open bite, periodontally compromised, mesiodens and any other specification)

M) Orthodontic Model Analysis

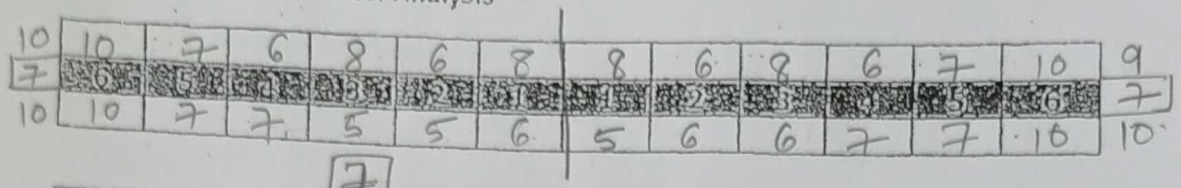

Parameter	Upper Arch	Lower Arch
Sum of Incisors	38	22
Total Tooth Material	70	61
Arch Perimeter	80	61
Difference	10 available	0

Nance & Carey's Index: (Mandible)

Arch perimeter- sum of tooth material mesial to 1st molar = 0 mm

LD' (Arch perimeter)=

LD= LA+2(X) $22 + 2(19) = 22 + 38 =$ 60

(LA=Sum of incisors, X= Sum of MD width of canine to 2nd premolar)

0- 2.5mm	2.5- 5mm	More than 5mm	INFERENCE
Proximal stripping	Extraction of second premolar	Extraction of first premolar	Proximal stripping.

Ashley & Howe's Index: (Maxilla)

$$\frac{\text{Canine fossa width} \times 100}{\text{TTM}}$$

$\frac{35 \times 100}{90}$ 38.8%

Need for extraction = 37% or less

No extraction = 44% or more

Borderline case = 37 – 44% Borderline Case.

PMD = $\frac{35 \times 100}{90}$ = 38.8%. E

Pont's Index:

1) Width of arch in premolar region

$$\frac{SOI \times 100}{80} \qquad \frac{28 \times 100}{80} = 35$$

2) Width of arch in molar region

$$\frac{SOI \times 100}{64} \qquad \frac{28 \times 100}{64} = 43.7$$

REGION	MEASURED	CALCULATED	DIFFERENCE	INFERENCE
4 | 4	30	35	5	Expansion Needed.
6 | 6	42	43.7	1.7	

Measured value is less expansion is required.

Chhada's Index

1) Width of arch in premolar region

$$\frac{SOI \times 100}{82.7} \qquad \frac{28 \times 100}{82.7} = 33.8$$

2) Width of arch in molar region

$$\frac{SOI \times 100}{63.7} \qquad \frac{28 \times 100}{63.7} = 43.9$$

REGION	MEASURED	CALCULATED	DIFFERENCE	INFERENCE
4 | 4	31	33.8	2.8	Expansion Needed
6 | 6	41	43.9	2.9	

DRNA Index:

1) Premolar Index (1st pm)

$$\text{Premolar index (1st pm max)} = \frac{\text{Sum of maxillary incisal widths}}{81.3} \times 100$$

$$\text{Premolar index (1st pm max)} = \frac{\text{Sum of mandibular incisal widths}}{57.87(\text{male}) / 60(\text{female})} \times 100$$

2) Molar Index (1st m max)

$$\text{Molar index (1st m max)} = \frac{\text{Sum of maxillary incisal widths}}{63.13} \times 100$$

$$\text{Molar index (1st m max)} = \frac{\text{Sum of mandibular incisal widths}}{45.75} \times 100$$

REGION	MEASURED	CALCULATED	DIFFRENCE	INFERENCE
4 4				
4 4				
6 6				
6 6				

MOYERS CHART

Mandibular bicuspids and cuspids												
21 1 2	19.5	20.0	20.5	21.0	21.5	22.0	22.5	23.0	23.5	24.0	24.5	25.0	25.5
Males													
95%	21.6	21.8	22.0	22.2	22.4	22.6	22.8	23.0	23.2	23.5	23.7	23.9	24.2
Females													
95%	20.9	21.0	21.2	21.5	21.7	22.0	22.2	22.5	22.7	23.0	23.3	23.6	23.9
Maxillary bicuspids and cuspids													
21 1 2	19.5	20.0	20.5	21.0	21.5	22.0	22.5	23.0	23.5	24.0	24.5	25.0	25.5
Males													
95%	21.2	21.4	21.6	21.9	22.1	22.3	22.6	22.9	23.1	23.4	23.6	23.9	24.1
Females													
95%	21.4	21.5	21.7	21.8	21.9	22.0	22.2	22.3	22.5	22.6	22.8	22.9	23.1

Bolton's Analysis

$\frac{82 \times 100}{90}$

Overall Ratio –

$\frac{\text{Md 12 x 100}}{\text{Mx 12}}$ Mean = 91.3 %

Inference – Mandibular TTM Excess / Maxillary TTM excess

0.

91.1 %

Anterior Ratio –

$\frac{\text{Md 6 x 100}}{\text{Mx 6}}$ Mean = 77.2 %

Inference – Mandibular Ant. TM excess / Maxillary Ant. TM excess

Inference in mm = 0.2 (excess/deficient overall)

Inference in mm = 0 (excess/deficient anterior)

$\frac{34}{44} \times 100 = 77.2\%$

$90 - \left(\frac{82 \times 100}{91.3}\right) =$

$90 - 89.8$

$= 0.2$

Space analysis:

Maxillary Arch-

Space Required	mm	Space available	mm
Decrowding	8 mm	Existing spaces	10 mm
Correction of Proclination		Derotation/ distalation	3 mm
Correction of deep bite	5 mm	Extraction	
Other		Proximal Stripping	
Total	13 mm	Total	13 m

Mandibular Arch:

Space Required	mm	Space available	mm
Decrowding	6 mm	Existing spaces	0
Correction of Proclination		Derotation	
Levelling of Curve of Spee	3 mm	Extraction	6
Molar Correction		Proximal Stripping	3
Total	9 mm	Total	9 mm

Diagnosis-

1. Skeletal
   a) Sagital-

Jaw Base Relation – Class I / Class II / Class III (ANB)

Maxilla – Orthognathic / Retrognathic / Prognathic (SNA)

Mandible – Orthognathic / Retrognathic / Prognathic (SNB ; SND ; SN-P_oG)

   b) Vertical-

Growth Pattern – Normal / Vertical / Horizontal (FMA ; $G_oG_n - S_n$)

Maxillary Rotation – Normal / Anteinclination / Retroclination (S_eN to Palatal plane)

Rotation of Jaw Bases – Divergent / Convergent / Same Direction (upward / downward)

(Functional + Palatal plane to Mand.Plane)

c) Transverse-

1. Dental

Angle's Malocclusion – Class I / Class II / Class III

3) Soft Tissue

Profile – Stralght / Concave / Convex

Lip –

Chin –

Muscle tonicity –

Tongue –

A 20 year 6 months old female patient on skeletal Class II jaw base with relation to cranial base with Horizontal growth pattern and posterior divergence, with retroclined upper and proclined lower anteriors, upper lip strain associated with competent lips.

Problem List with Priority –

Patient's Priority – correction of crowded teeth.

Operator's Priority – correction of deep bite and to achieve class I molar relation.

Treatment Objectives –

① To correct the retroclination of Maxillary Incisors
② Extraction of Impacted Canine.
③ To correct the lower dental midline shift
④ To corred the deep bite.
⑤ To level and align the arches.
⑥ Settling the occlusion.

Treatment Plans –

Treatment A → ① Non-Extraction treatment plan.

① Fixed Mechanotherapy with MBT slot 0.022".
② Upper anterior Bite plate is given for anchorage
③ Before alignment, Utility arch is given from maxillary central Incisor to maxillary first molar. for correction of retroclination and deep bite.
④ After correction of proclination, alignment and leveling of upper arch is done.
⑤ For mandible, Extraction of Impacted canine.
⑥ Ideal treatment plan for correction of retrusive mandible is orthognathic surgical procedure BSSO (Bilateral split sagittal osteotomy).

23/8/22

CEPHALOMETRIC ANALYSIS

1. Down's Analysis:

Measurement	Mean value	Pre treatment	Mid treatment	Post treatment
Facial Angle	87.8	80°		
Angle of Convexity	0°	22°		
AB Plane Angle	-4.6°	−18°		
Mandibular Plane Angle	21.9°	28°		
Y- Axis	59.4°	62°		
Cant to Occl. Plane	9.3°	19°		
Inter incisal Angle	135.4°	157°		
Incisor occl. Plane Angle	14.5°	17°		
Incisor Mand Plane Angle	1.4°	14°		
U1to A- pog Linear	2.7 mm	1 mm		

skeletal class II
Prominent maxilla.
class II
Average vertical growth of mandible
class II div II
Average
lower proclined

2. Steiner's Analysis:

Measurement	Mean/ SD	Pre treatment	Mid treatment	Post treatment
SNA	82°	85°		
SNB	80°	74°		
SND	76°			
ANB	2°	11°		
Go Gn to SN	32°	25°		
U1 to N-A mm	4mm	−9 mm		
U1 to N-A angle	22°	−14°		
L1 to N-B mm	4mm	2 mm		
L1 to N-B angle	25°	23		
L1 TO U1 angle	131°	157°		
Occl. To S-N angle	14°	23°		
S Line	retrusive			
SL SE ratio				

Prognathic maxilla
retrusive mandible
class II skeletal
Horizontal growth
class II div II

Average
class II div II

Steiner's sticks:

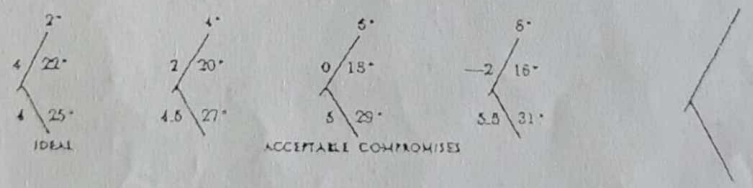

3. Tweed's Analysis:

Measuremant	Mean	Pre t/t	Mid t/t	Post t/t	Inference
FMA	25^0	25°			
FMIA	65^0	54°			
IMPA	90^0	102°			

4. Witt's Appraisal:

Measurement	Mean	Pre t/t	Post t/t	Post t/t
BO AO	F O mm M ± 1mm	5 mm		

Female

5.Mc Namara's Analysis:

Measurement	Mean	Pre t/t	Mid t/t	Post t/t
N perpendicular to A	0±2 mm	0		
N perpendicular to pogonion	0 to -4mm	-16		
Facial axis angle	0	-1°		
Mand. Plane angle	26±4	24°		
Eff. Max. length(CO-A)	91 mm	90 mm		
Eff. Mand. Length(CO-Gn)	113-118 mm	100 mm		
Maxillofacial differential	→	10 mm		
Lower ant. Face height	→ (LAFH)	61 mm		
U1 to point A distance	4mm	-8 mm		
L1 to A pog line distance	1-2mm	5 mm		
Naso labial angle	90-110	117°		

Average
retrusive mandible
vertical face
Average

Class II div 2

- Airway Analysis-

  Upper airway: 8 mm

  Lower airway: 6 mm

6. Rickett's Analysis-

	Mean value	Pre t/t	Mid t/t	Post t/t	
Facial axis angle	$90^0 \pm 3.5^0$	89°			retroposition of chin. skeletal class II.
Facial depth	$87^0 \pm 3^0$	79°			Average
M.P. angle	$26^0 \pm 4.5^0$	25°			Class II skeletal
Convexity of pt. A	$2^0 + 2$mm	9mm			
L1 to APO angle	$22^0 \pm 4^0$	13°			retroclined.
L1 to APO mm	1 ± 2	5mm			
U_6 to Pt V	Age + 3mm	21 mm			Average
L. lip to E-plane	-2 + 2mm	2 mm			

7. Composite Analysis:

A) Cranial base relationship:

Parameters	Males	Females	Pre treatment	Mid t/t	Post treatment	
N-S-Ba degree		130±6	133°			
N-S	83±4	77±4	71mm			Average
S-Ba mm	50±4	46±4	47 mm			
SN-FH degree		5±4	4°			Average

B) Maxilla to cranium

	Males	Average	Females	Pre t/t	Mid t/t	Post t/t
SNA degree		82±6		85		
N-ptA mm	1.1±2.7	0 to 1 mm	0.4±23	0		
Ba- PNS mm	52±4		50±4	46mm		
Ba-ANS mm	113±5		106±5	105 mm		
Na-ANS mm	60±4		56±3	47mm		
PAL Sc N degree		84	(Compliment)	85°		
Co-A mm	99±86		91±4.3	90 mm		
PNS-ANS mm	62±4		57±4	58mm		

Average

C) Mandible to cranium

	Males	Average	Female	Pre t/t	Mid t/t	Post t/t
SNB degree		80±2		74		
N-Pg mm	0.3±3.8		-1.8±4.5	-16		
Npg-FH degree		89±3.9		80°		
Ba-Gn mm	128±5		120±6	99 mm		
Co-Gn mm	134±7		120±5	100mm		
Co-Go mm	66±4		60±3	52 mm		
Go-Gn mm	86±4		81±4	66 mm		
ArGo .Me degree		126±6		123°		

retrusive mandible

Horizontal retrusive mandible

D) Maxilla to Mandible:

	Males	Average	Females	Pre t/t	Mid t/t	Post t/t
ANB degree		2		11°		
Ao-Bo mm	-1		0	5 mm		
Co-A Go-Gn mm	34.5±4		29.2±3.3	24 mm		

90 − 66

=

E) Vertical relation:

	Males	average	Females	Pre t/t	Mid t/t	Post t/t
Y- axis		53 to 66		62°		
Facial axis		90		80°		
GoGn-Sn		32		41°		
Occ-Sn degree		14		23°		
FMA degree		25		25°		
UFH/LFH mm		0.7		0.7		
PFH/AFH mm		62.65%		69.23%		
Sum of posterior angle degree		396		389		

48/61

72 104

122 + 144 + 123.

F) Chin Prominence:

	Males	Average	Females	Pre t/t	Mid t/t	Post t/t
Pog-NB mm		2±2				
B-Pg Mp mm	8.9±7		7.2±9			

G) Maxilla Dental

	Males	Average	Females	Pre t/t	Mid t/t	Post
U1-Na mm		4		-9		
U1-Na Angle		22		-14		
U1-pt A 1 mm	5.3±2		5.4±1.7	-8 mm		
U1-Sn degree	102±2			72°		
U1-A Pog mm		25°, 4mm		0 mm		
U1-N Pog mm		2mm		4 mm		

skeletal class II div II

H) Mandible Dental

	Males	Average	Females	Pre t/t	Mid t/t	Post t/t
L1-NB mm		4		3 mm		
L1-NB degree		25		24°		
IMPA degree		95±5		102°		
L1-A Pog mm		22, 4		16,5 mm		
L1-N Pog mm		4		2 mm		

I) Maxilla-Mandible Dental:

	Males	Average	Females	Pre t/t	Mid t/t	Post t/t
U1-L1 degree		130±5 2 mm		157°		

Composite soft tissue analysis:

		Males	Avg	Females	Pre trt	Mid trt	Post trt
GSnPog							
Nose prominence							
Cm-Sn-Ls							

Holdaway's Analysis:

Nasolabial angle							
Facial angle	N´pog´-FH	88°					
Upp. Lip Curvature	N´pog´ FH	1 mm					
Sk. Convexity at A	A-NPog	9 mm					
Harmony angle	Pog´-Ls to N´pog´	24°					
Pn to H	Pn to H	4 mm					
Up. Sulcus depth	Sls-H	5 mm					
Up. Lip thickness	Sn-A	11 mm					
Up. Lip strain	11-7 =	8 mm					
Li to H line		0					
Low. Sulcus depth	Lls-H	7 mm					
Soft tissue chin thickness	Pog-Pog´	11 mm					
S line to LL1(mm)							

Date	Work Done	Follow up on	Signature
5/7/22	Case history and record taken		
15/7/22	Pt is advised for Mandibular occlusal view.		
29/7/22	placement of seperator in upper molars		
25/8/22	placement of utility arch of 16x16 SS wire.		
29/9/22	placement of utility arch of 16x22" SS wire.		
2/11/22	Reactivation of utility arch of 16x22" SS wire		
26/12/22	Removal of utility arch and complete upper bonding done and 0.012" Niti wire given.		
27/1/23	Lower bonding done with 0.14" Niti wire given.		
3/3/23	Extraction with $\frac{+}{C}$ 0.14" Niti wire placed in upper arch and 0.12" Niti wire in lower arch		

Date	Work Done	Follow up on	Signature
6/4/23	16x22" Niti in upper arch and 0.14" Niti in Lower arch.		
28/4/23	17x25" Niti in Upper arch and 0.14" Niti in Lower arch		
29/5/23	17x25" SS wire placed in upper arch and 0.16" Niti wire placed in Lower arch E-chain in upper from 6 – 6.		
5/7/23	19x25" Niti in upper arch with cinch back. and 0.18" SS in Lower arch and E-chain ~~2-12~~		
8/8/23	17, 27, 37, 47, Bonded. 0.16" Niti wire placed in upper and Lower arch.		
7/9/23	16x22" SS in upper arch and cinch back. 16x22" SS in Lower arch 7 – 7 E-chain		
4/10/23	19x25" SS in upper arch and cinch back 19x25" SS in lower arch and consolidated.		
9/11/23	Installation of forsus appliance with Omega loops in Lower arch		

CASE HISTORY

Department of Prosthodontics, Crown and Bridge

OPD No.
Date

Department of Prosthodontics
DY Patil Dental School, Lohegaon
Pune

Case Record
Complete Denture Therapy

I. Name of the Student : Sakshi Lonkar

Roll No. : 25

Patient Data

Name : Mrs. Anusaya Jadhav

Age : 70 years

Sex : female

Address : Skways Sereno, Lohegaon, Pune

Phone No : 9325443434

Occupation : Housewife

II. Chief Complaint Patient complains of ill fitting denture since 2-3 years.
HOPI

III. Systemic Status (Names of disease with check box)
~~☐~~ Hypertension ☐ Aasthma ~~☐~~ Thyroid
☐ Diabetes ☐ cardiac disease ~~☐~~ Anemia
Medications if any

IV. Personal History

Diet : Vegetarian

Habits: mishri since 45 years

V. Dental History

I. History of Dental Extraction - Naturally exfollated.

a) Maxillary:

Reason for extraction - carier pulpal/perio/trauma

Sequence of extraction - loss of teeth

		max
		mand

Duration of extraction - edentulousness = 5-6 years

b) Mandibular:

Reason for extraction - carier pulpal/perio/trauma

Sequence of extraction - loss of teeth

Duration of extraction - edentulosness 5-6 year

ii. Number and type of previous denture

Type	Maxillary	Mandibular	Duration
complete denture	✓	✓	3-4 years

iii. Earlier denture experience : Not satisfactory
iv. Evaluation of previous denture : loose fitting denture
v. Pre extraction Records :

VI. Mental Attitude (House Classification) Philosophical

VII. Gen. Examination - Gait, constitution, Nutritional status, diet

VIII. Extra Oral Examination Pt. orientation to time, place of person

i. Facial form

Outline for : Square/Tapering/Sq.tapering/Ovoid

Profile : Straight/Convex/Concave

ii. Lips(Static Position)

a) Length : Short/Medium/ Long

b) Thickness: adequate.

c) Support : Adequately supported / Unsupported

d) Mobility : Normal / Reduced mobility/Paralysis

e) Commissure:
competancy competant lipr

iii. Temporomandibular joint

a) Tenderness :

~~b) Mouth opening~~ :

c) Deviation

d) Clicking/Crepitus :

} No abnormality detected.

e) Any other :

iv. Neuromuscular evaluation

a) Speech : Normal / Affected

b) Co-ordination : Excellent / Fair / Poor

VII. Intra Oral Examination

i. Arch form : Square / Tapering / Sq. tapering / Ovoid

ii. Rresidual Ridge Form (Atwood's clasification)

Maxillary : order 3

Mandibular : order 5

iii. Inter arch space : Ideal / Excessive / Insufficient

mylohyoid ridge

iv. Ridge Parallelism : Class I / Class II / Class III

Genial tubercle

v. Ridge Relation : Class I / Class II / Class III

Hard palate

vi. Soft Palate : Class I / Class II / Class III

rat-throat form

vii. Palatal Sensitivity : Presence / Absence of gaging

floor of mouth

gag reflex -

ix. Mucose Condition : Healthy / Inflamed/ Pathologic

x. Attachment

		Labial	Buccal
Frenal	: Maxillary	Class I	Class I
	: Mandibular	class I	Class I

xi. Saliva

Quality : Serous Mucous

~~Quality~~ Quantity : Adequate / Inadequate

xii. Tongue

Size : ~~Normal / Enlarged~~ I / II / III

~~Quality~~ : ~~Normal / Retracted~~

Position – mouth opening – adequate.

ix. Investigation

XI Provisional Diagnosis – maxillary and mandibular completely edentulous arch
OPG

XIII - Final diagnosis –

XIV - Prognosis – Good.

x. Treatment Plan

~~A. Surgical / Non Surgical Preparation of tissues / Systemic / Local~~

treatment :

A] Education & motivation for treatment

B] Pre prosthetic treatment

–

C] Prosthetic treatment

Complete Denture Prosthesis for maxillary and mandibular arch

B. Clinical Step and Laboratory Procedures , Materials, and Techniques used:

No.	Step	Date	material & technique	Sign Grade	Sign
1.	Primary Impression : Maxillary Mandibulor	31/3/23	Primary impression made with impression compound (mucostatic tech)		
2.	Primary cast perparation	31/3/23	Dental Plaster		
3.	Custom tray fabrication	31/3/23	cold cure acrylic resin		
4.	Final Impression: Maxillary Mandibulor	3/4/23	Border moulding with green stick cpd. Final impression with ZOE paste		
5.	Master Cast	5/4/22	Dental stone		
6.	perparation of Wax occiusal rims	6/4/23	modelling wax.		
7.	Jaw relation record	8/4/23	Jaw relation recorded		
8.	Transfer of sealed Jaw relation record to the articulator		Dental Plaster		
9.	Selecation of teeth				
10.	Teeth arrangement	10/4/23			

1190771645

11.	Try-in and Verification of jaw relation record	11/4/23	
12.	Perparation of mould, wax elimination, processing	12/4/23	
13.	trimming, regovery of the denture, finishing and polishing	13/4/23	
14.	Denture insertion	17/4/23	
15.	Recall checkup		

Accomplishment : Satisfactory / Unsatisfactory

Patient's Signature :

17.4.23

Staff Incharge Signature :

HOD Signature

OPD No.	91223
Date	

Department of Prosthodontics
DY Patil Dental School, Lohegaon
Pune

Case Record
Removable Partial Denture Therapy

I. Name of the Student : Ankita Gaikwad.

Roll No. : 19

I. Patient Data

Name : – Muktai Deshpande.

Age : – 50 years.

Sex : – Female

Address : – Bhosari, Pune.

Phone No : –

Occupation : – Housewife

II. Chief Complaint Patient complains of missing teeth in upper and lower jaw since 1 year.

III. Systemic Status – Normal

Medications if any – NRH

IV. Dental History

Extraction done 1 year ago.

V. Mental Attitude

Philosophical

VI. Tempormandibular Joint Examination :

No abnormality detected.

VII. Intra oral Examination

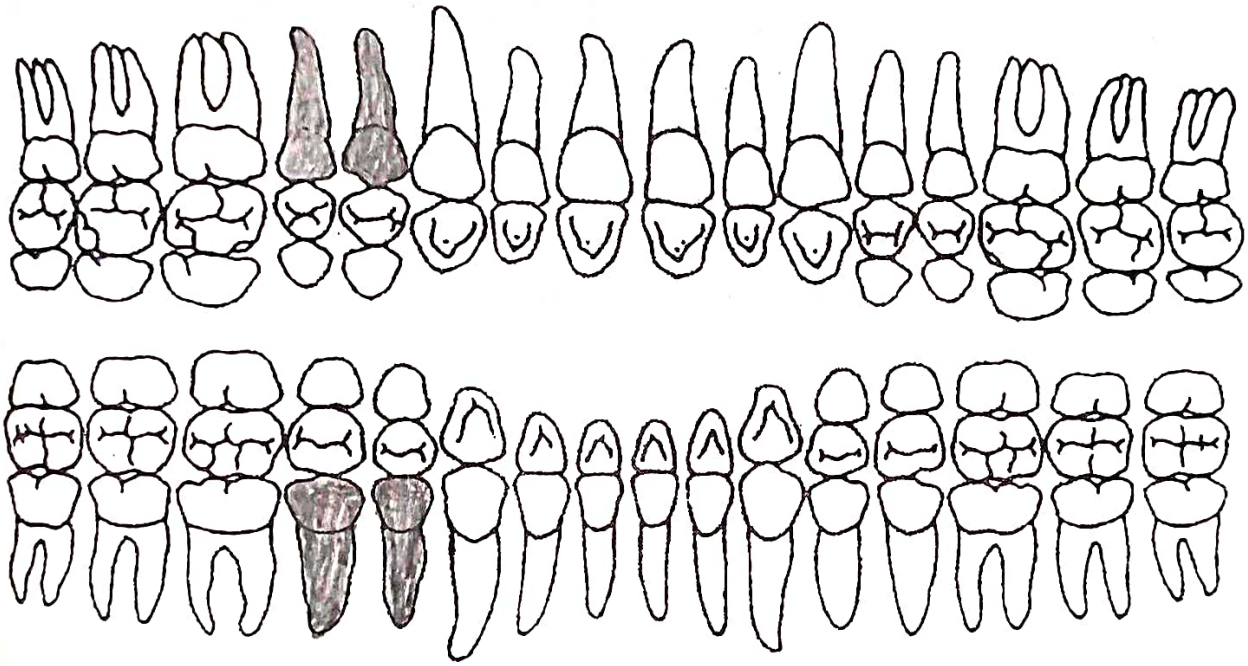

Missing : Red
Root Canal Therapy : Blue
Restoration : Light Blue
Root Pieces : Brown
Crowns / F.P.D : Green
Plaque/ Calculus / Stains : Yellow
Caries : Black
Impacted teeth : Light green

Any other relevant findings :

XIII. Treatment Plan for Definitive Partial Denture.

Maxillary :

Treatment Plan

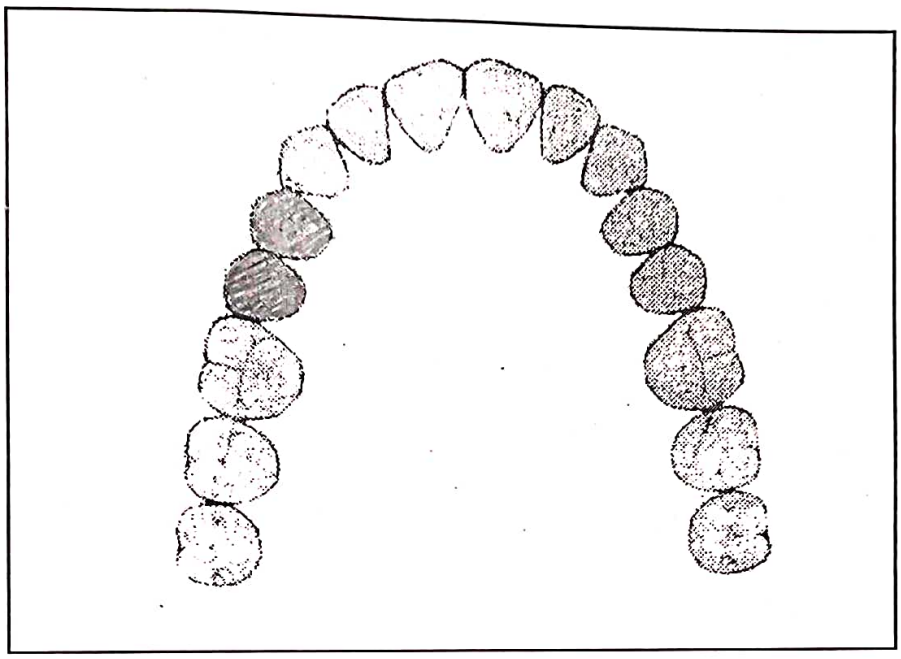

Mandibular :

Treatment Plan

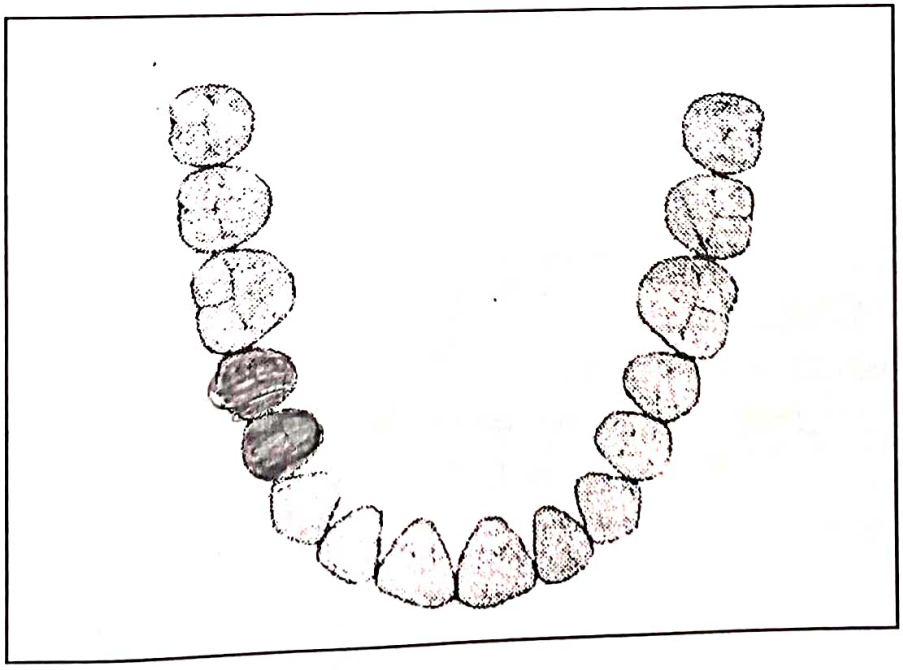

1197-1645

XIV. Treatment Plan for Interim Partial Denture :

Clinical Step and Laboratory Procedures , Materials, and Techniques used:

No.	Step	Date	Material & Technique	~~Sign~~ Grade	Sign.
1.	Diagnostic Impression : Maxillary Mandibulor		Alginate impression material used & mucostatic pressure technique used.		
2.	Diagnostic cast Working cast fabrication		Dental stone double pour technique		
3.	Custom tray fabrication (if required)				
4.	Final Impression: Maxillary Mandibulor				
5.	Working cast fabrication				
6.	Surveying				
7.	Blockout of working cast		Modelling wax used.		
8.	Jaw relation record (if required)				
9.	Transfer of sealed jaw		Mean value articulator used		

	relation record to the articulator				
10.	Selection of teeth		Acrylic teeth.		
11.	Teeth arrangement				
12.	Try - in and verification of jaw relation record				
13.	Preparation of mould , wax elimination, processing		Flasking done with dental plaster, dewaxing done. packing with heat cure resin compression moulding.		
14.	Trimming, recovery of the denture, finishing and polishing		Finishing & polishing done.		
15.	Denture insertion				
16.	Recall checkup				

Accomplishment: Satisfactory / Unsatisfactory

Patient's Signature

Staff Incharge Signature:

HOD Signature

Consolidated statement of Expenditure incurred excluding salary for Purchase of Consumables

Statement highlighting expenditure incurred excluding salary for Purchase of Consumables.

This is to state that the following expenditure has been done by the college for purchase of consumables excluding salary component as a percentage during the last five years.

Financial Year	Expenditure on the Purchase of Consumables
2022-2023	Rs.1,08,93,487.00
2021-2022	Rs.64,81,862.00
2020-2021	Rs.49,53,728.00
2019-2020	Rs.69,11,255.00
2018-2019	Rs.38,19,614.00

Dr Anand Shigli
Dean
D Y Patil Dental School

D Y PATIL DENTAL SCHOOL PUNE

LINGARAJ SHIGLI ANAND
Digitally signed by LINGARAJ SHIGLI ANAND
Date: 2024.09.27 10:23:19 +05'30'